




Ultrasound

in Abortion Care



Ultrasound Training **Workbook**



ULTRASOUND IN ABORTION CARE WORKBOOK

In 2005, Affiliates Risk Management Services, Inc. (ARMS) began a conversation with the Consortium of Abortion Providers (CAPS) on potential opportunities for collaboration. Based on these discussions, both ARMS and CAPS saw an unmet need for a training tool for affiliate staff members who perform ultrasound services for Planned Parenthood clients. Such a training tool would provide consistent and clear training to a diverse group of medical staff with varying levels of training. This training program, *Ultrasound in Abortion Care*, is a result of the ARMS/CAPS collaboration.

ARMS gratefully acknowledges the substantial contribution of the Consortium of Abortion Providers (CAPS), and in particular, Mary Fjerstad, in the development of both the concept and content of this program, both the CD-ROM and accompanying workbook. We would also like to extend thanks to the National Abortion Federation (NAF) for their provision of CME credits for those medical staff who utilize the “*Ultrasound in Abortion Care*” CD-ROM, and Challenger Corporation for their technical expertise in building the CD-ROM tool. Additionally ARMS would like to thank the various authors, faculty, and reviewers who lent their support and expertise to this project.

AUTHORS

Mark Deutchman, MD
Professor of Family Medicine
University of Colorado Health Sciences Center
Denver, Colorado

Matthew F. Reeves, MD, MPH
Director of Family Planning Research
Assistant Professor
Divisions of Gynecologic Specialties and Diagnostic Ultrasound
Department of Obstetrics, Gynecology, and Reproductive Sciences
University of Pittsburgh School of Medicine
Pittsburgh, Pennsylvania

Mary Fjerstad, NP, MHS
Clinical Training Director
Planned Parenthood Consortium of Abortion Providers
El Cajon, California

Mary Andrews, NP, MSN
Women’s Health Nurse Practitioner
Department of OB/Gyn
Adjunct Faculty, University of Arizona
Planned Parenthood of Southern Arizona
Tucson, Arizona

FACULTY

Chief Faculty Advisor:
Matthew Reeves, MD

Advisory Committee:
Laura Castleman, MD, MPH
Christian Fiala, MD
Paul Fine, MD
Deborah Oyer, MD

CREDITS

Chief Faculty Advisor: Matthew Reeves, MD
Author: Mark Deutchman, MD
Project Manager: Mary Fjerstad, NP
Director of Development: Bobby Anderson
Multimedia Programmer: Jamie Ciocco
Narrator: Suzanne Thorp RNC, MS, WHNP
NAF Project Coordinators: Lauren Tews, MPH and Melissa Werner, MPH, MAT

DISCLAIMER

This educational program is intended as a guideline and does not dictate an exclusive course of management. The program contains recognized methods and techniques of medical care that represent currently appropriate clinical practice. Variations in the needs of individual patients and differences in the resources available to clinical providers may justify alternative approaches to those contained in these materials. Neither Affiliates Risk Management Services, Planned Parenthood[™] Federation of America, Planned Parenthood Consortium of Abortion Providers, the National Abortion Federation, nor officers, employees, or members associated therewith are responsible for adverse clinical outcomes that might occur in the course of delivery of services in which they are not expressly and directly involved in the role of primary caregiver.

CME INFORMATION

Learners can receive CME credit for completing the “Ultrasound in Abortion Care” CD-ROM and taking the CME test. Please see the CD-ROM for additional information. CME credits are not available for “advanced placement” test completion.

INFORMATION ABOUT RUNNING THE CD-ROM

MINIMUM SYSTEM REQUIREMENTS:

Windows:

- Pentium III or comparable processor
- Windows 2000 or XP
- 128 MB RAM
- 16-bit color (thousands of colors) at 800x600 (SVGA) resolution
- Sound card and speakers

Macintosh:

- Power Macintosh 500 MHz G3 or higher
- Mac OS X 10.2.6 or higher
- 256 MB RAM
- 16-bit color (thousands of colors) at 800x600 (SVGA) resolution

RECOMMENDED SYSTEM REQUIREMENTS:

Windows:

- Pentium IV or comparable processor
- Windows 2000 or XP
- 256 MB RAM (512 MB recommended for Windows XP)
- 24-bit color (millions of colors) at 800x600 (SVGA) resolution
- Sound card and speaker

Macintosh:

- Power Macintosh G4, G5 or Intel Mac
- Mac OS X 10.3.9 or 10.4
- 512 MB RAM (1 GB recommended for Intel Macs)
- 24-bit color (millions of colors) at 800x600 (SVGA) resolution

INSTRUCTIONS FOR GENERAL USE OF THE CD-ROM

Windows: Simply place CD-ROM in your computer. The program will auto-start and install all required components (if Autorun is disabled on your computer, double-click the CD-ROM icon). To minimize the course viewer or quit the program, see the "Options" menu in the top menu bar.

Macintosh: Place CD-ROM in your computer. Double-click the CD icon that will appear on your desktop. A folder will open containing the program application icon and a Readme help text. Double-click the application icon to launch the program. The program will install all required components. To minimize the course viewer or quit the program, see the "Course Viewer" menu in the top menu bar.

After the program loads, several narrated introductory videos will explain the features of the interactive CD-ROM course. There is also detailed Help in the "About" pull-down menu.

Go to Options --> Display Settings to find out how to properly configure your display for optimal ultrasound viewing.

CME SUPPORT INFORMATION

Included in this CD-ROM, there is an interactive CME quiz. Users completing the quiz with a passing score of 80% will be eligible to receive CME credit. CME accreditation information and how to submit your quiz results for CME credit are outlined in the CME menu on the CD-ROM, printed on the printable score report which is generated upon completion of the quiz, in the introductory video, and Help menu.

All CME submissions (completed score report and user evaluation from) should be mailed or faxed to:

Challenger Corporation
c/o ARMS/NAF CME
5100 Poplar Avenue, Suite 310
Memphis, TN 38137
USA
Fax: 1-901-767-7019
Tel: 1-901-762-8449, ext. 1405

CME certificates are processed within 5-10 business days following receipt of your mailed or faxed submission. A CME certificate will be mailed to you at the address you provide upon processing completion. Please allow for transit time. All submissions are subject to verification. All user information is kept confidential.

ADVANCED PLACEMENT SUPPORT

Those staff performing ultrasound who are already proficient and experienced may take the Advanced Placement (AP) quiz in lieu of reviewing the CD-ROM, though reviewing the CD-ROM and taking the CME quiz is recommended. The AP quiz is available from the "AP Quiz" pull-down menu on the CD-ROM. Learners can take the AP quiz for the Introductory Chapters or for both the Introductory Chapters and the Advanced Modules. Learners who score 80% or better on the AP quiz can then click "View/print score report" to print out a score report. This report can be kept in their personnel file, verifying the content areas that were tested and passed.

No CME hours will be awarded for those who take the Advanced Placement quiz; CME credit can only be awarded when the CD-ROM is reviewed, the CME quiz is taken and passed, and then the user applies for a CME certificate.

LIVE TECHNICAL SUPPORT

Business Hours:
Monday - Friday (Excluding Holidays) 8:00am - 6:00pm, Central Standard Time (USA)

Toll-Free: (888) 242-5536
Email: techsupport@chall.com
On the Internet: www.chall.com/support.htm

Affiliates Risk Management Services, Inc.
Copyright© 2007

1.1: Purpose of this Training CD

This training CD includes instruction in the use, performance and interpretation of ultrasound examinations in the field of abortion care. The target audience is personnel working in abortion services with a wide range of backgrounds, from medical assistants to physicians.

This training CD includes instruction in the use, performance and interpretation of ultrasound examinations in the field of abortion care. The target audience is personnel working in abortion services with a wide range of backgrounds from medical assistants to physicians.

This resource is intended to provide an overview of the material and also allows the user to practice some ultrasound skills, such as measuring gestational sacs. Testing and quality assurance features are also provided. After completing this resource, users will need additional training and hands-on experience under the supervision and

guidance of an experienced sonographer.

It should be noted that ultrasound is not necessary for the safe provision of abortion, either by aspiration or using medications. In many practices, ultrasound is not a routine component of abortion care. Where it is available, some providers find ultrasound helpful, for instance, in pre- or post-abortion assessment and/or during procedures with challenging anatomy. Sonography is a tool that can provide valuable data when used properly by adequately trained personnel. This CD covers a comprehensive range of topics related to the use of ultrasound in abortion care. This resource provides guidance for the correct performance of ultrasound but should not be interpreted to imply that ultrasound is a standard that should be uniformly adopted in the provision of abortion care.

National Abortion Federation designates this educational activity for a maximum of (three four five six seven eight nine ten eleven) hours of Category I credit towards the AMA's Physician Recognition Award. Users should claim only the number of hours that they spent completing the CD.

1.2: Introductory and Advanced Chapters

- Chapters 1 - 9 are introductory chapters.
- Chapters 10 through 13 are advanced chapters.
- The CME quiz is divided so that learners can receive credit for introductory or advanced chapters or both.
- Chapter 14 should be reviewed by all users.

Chapters 1 through 9 are introductory chapters. The main purpose of the introductory chapters is to introduce the basic principles of ultrasound; however, more sophisticated findings will also be mentioned. As learners progress in their skills, they will be able to recognize more subtle sonographic findings. However, the expectation of the program is that they will understand the important basic principles, and the basic principles are tested in the CME post-test.

Chapters 10 through 13 are advanced chapters.

The CME quiz is divided so that learners can receive credit for introductory or advanced chapters or both.

1.3: Learning Objectives

Upon completion of the basic chapters, you will:

- Understand the use of ultrasound in the first trimester of pregnancy
- Understand the physics of ultrasound
- Understand the techniques of transabdominal and transvaginal ultrasound
- Recognize normal and abnormal first trimester sonographic findings
- Correlate hCG and sonographic findings
- Perform gestational sac measurements
- Perform embryonic crown-rump measurements
- Understand the implications of specific sonographic findings for the provision of surgical abortion
- Understand the use of ultrasound in medication abortion
- Recognize and monitor the proficiency of staff performing ultrasound in abortion care.

Upon completion of the introductory chapters, you will be able to:

- Describe the role of ultrasound in the first trimester of pregnancy
- Summarize the physics of ultrasound
- Compare and contrast techniques of transabdominal and transvaginal ultrasound
- Identify normal and abnormal first trimester sonographic findings
- Correlate hCG and sonographic findings
- Perform gestational sac measurements
- Perform embryonic crown-rump measurements
- Describe the implications of specific

ultrasonographic findings for the provision of surgical abortion

- Explain the use of ultrasound in medication abortion
- Summarize how to recognize and monitor the proficiency of other providers' use of diagnostic ultrasound in abortion care.

The term "medical abortion" has been the most widely used descriptor for abortion methods employing regimens of mifepristone, methotrexate, misoprostol, and/or other agents when used in the first trimester, generally through 63 days gestation. However, some in the field use the term "medication abortion" as an alternative term and have argued that it is more understandable and less confusing. This is the term we will use in this resource.

Upon completion of the advanced chapters, you will be able to:

- Perform second trimester fetal measurements to assess gestational age
- Recognize the location of the placenta sonographically
- Understand the use of real time ultrasound in first and second trimester surgical abortion.

Upon completion of the advanced chapters, you will be able to:

- Perform second trimester fetal measurements to assess gestational age
- Recognize the location of the placenta sonographically
- Explain the use of real time ultrasound in first and second trimester surgical abortion.

1.4: Patient Counseling



NP: Hello Ms. _____ my name is _____. I would like to explain how we use ultrasound to plan and complete your abortion procedure safely and efficiently. I would also like to make sure all your questions are answered. Ultrasound enables us to see inside the body using sound waves similar to sonar used by ships. The sound energy is very small and not harmful. The two main things we want to know are the location of the pregnancy and how far along your pregnancy is. We know that you have had already had a positive pregnancy test, but we need to make sure that the pregnancy is inside the uterus, not somewhere outside of your uterus, such as in a fallopian tube, since that would require very different care. Sometimes, we find that a pregnancy is already starting to miscarry. Early miscarriages are very common. If you are already starting to miscarry, your treatment would be different. Once we know that the pregnancy is inside the uterus, we need to know how far along it is. We do that by taking measurements. It is important to know how far along you are to advise you about the timing and type of abortion procedure that can be used in your case. Do you have any questions?

NP: An ultrasound scan can be performed by placing a probe either in the vagina or on the abdomen. In early pregnancy, because the pregnancy is very small and very low in the pelvis, the best way to view it is by placing a small transducer inside your vagina, so that is what we're going to use today. The transducer is cleaned first and covered with a latex or plastic cover and sterile lubricant.

Are you allergic or sensitive to latex?

Client: No.

NP: During the ultrasound scanning process, I will see the uterus and, will probably see the pregnancy on a video screen. I will make measurements of the embryo to determine how far along you are. The process takes several minutes.

After the scan is complete, I will usually be able to tell you how far along your pregnancy is and counsel you about what abortion procedures you may choose from. If I see anything unusual, like a failed pregnancy or more than one embryo, would you like to know this?

Client: No, I don't think I need to know that.

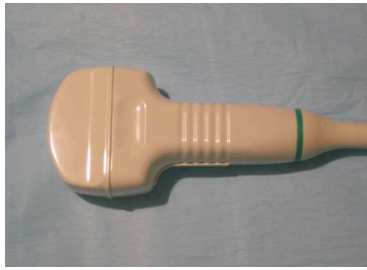NP: OK. Occasionally, the pregnancy is too early to see, or the findings are abnormal or not clear. If that occurs, I will be recommending other medical consultation to help figure things out. If I see, or suspect that your pregnancy is outside of the uterus--called ectopic pregnancy--that is a potentially very dangerous condition for your health and will recommend immediate medical attention.

Do you have any questions?

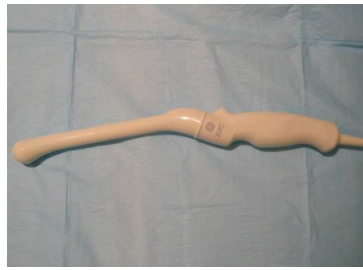Client: No.

NP: If it would make you feel more comfortable, you may grasp the handle of the probe and insert it yourself into your vagina.

2.1: Role of Ultrasound and Scanning Routes



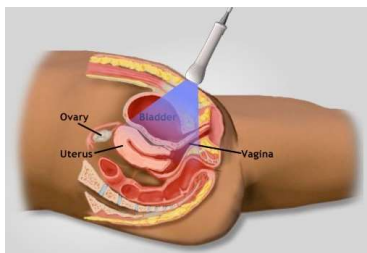
Transabdominal transducer



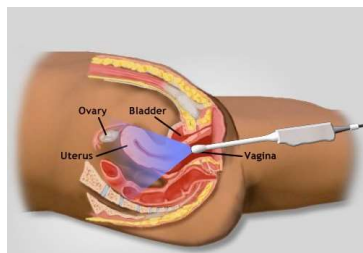
Transvaginal transducer

Sonography is a tool that can provide valuable data regarding the location, age and condition of the pregnancy when used properly by adequately trained personnel. Understanding the physics and instrumentation of ultrasound is essential to make the best use of this tool. The uterus and pelvis can be scanned by both the transabdominal or transvaginal route using different

probes.



Transabdominal scanning



Transvaginal scanning

Scanning by the transabdominal route produces a wide overview of the pelvis. Scanning by the transvaginal route produces a more detailed, but narrower and shallower view. Chapter 4 includes extensive instruction in the techniques of pelvic scanning, while this chapter is devoted to the physics and instrumentation of ultrasound.

2.2: Introduction to the Physics and Orientation Section

Goals of the Physics Section:

- Understand basic physics of ultrasound
- Understand what artifacts are
- Recognize patient orientation
- Orient the ultrasound image correctly

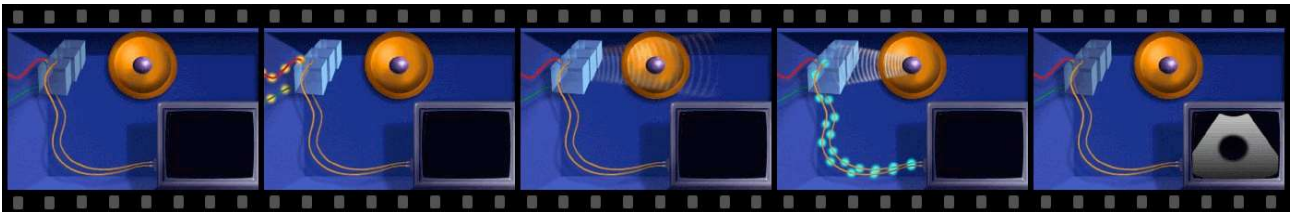
Two topics are covered in this section. First, the physics of sonography are reviewed including how physics affects sonographic images. Second, standard patient positioning and image orientation and labeling are discussed. Available ultrasound technologies are reviewed. Additional information about ultrasound technologies is included in the Advanced Module.

2.3: The Piezoelectric Effect: Transmission



The probe is the main part of the ultrasound machine. The crystals in the probe are called piezoelectric crystals. The crystals in the probe generate sound waves. The sound waves travel outward and pass through tissue and fluid and are reflected back to the probe.

2.4: The Piezoelectric Effect: Reception



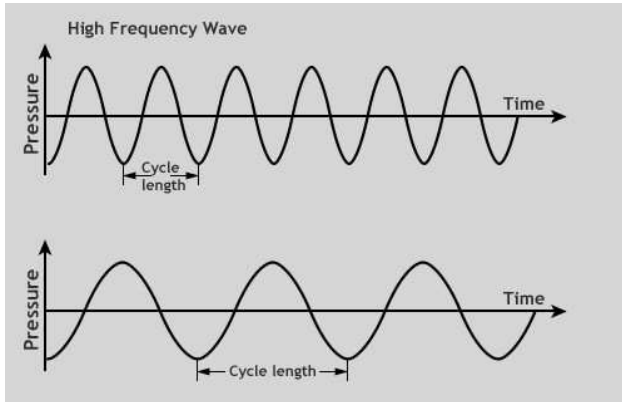
When the sound wave emitted from the transducer crystal strikes a reflective substance and is reflected back, the reflected sound energy strikes the crystal. Because the crystal is a piezoelectric material, it emits a tiny electrical charge when it is struck. This tiny charge indicates to the computer in the ultrasound machine the presence of objects within the ultrasound beam. By using the clock in the computer to track the time from emission of the sound wave to its return, the distance from the probe can be calculated. This method works because the speed of sound waves in human tissues is essentially constant.

2.5: Transducer Construction




The construction of the ultrasound probes is highly technical. They are very expensive. In many cases, probes that are broken cannot be repaired. Care should be taken to avoid dropping them, knocking them or running over the cord. Also, the probe shouldn't be twisted around, because that can damage the probe. The probe only needs to be rotated from the longitudinal to the transverse position.

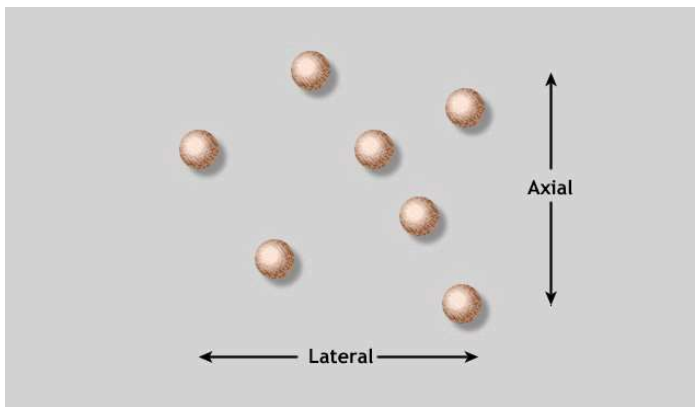
2.6: Probes with Different Frequency



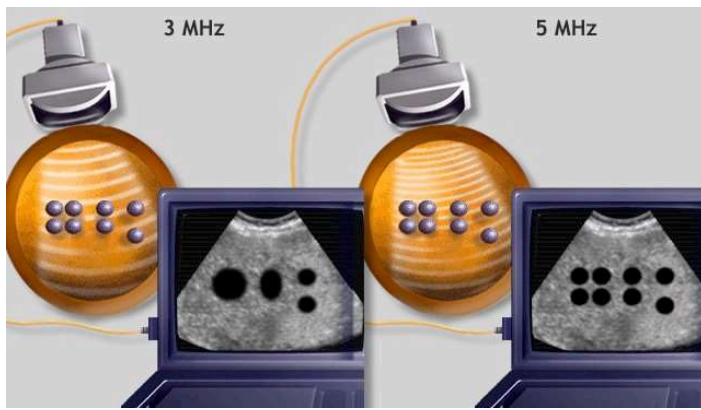
Sound waves vary in frequency, which corresponds to pitch. Sound waves that humans can hear are in the range of 20 to 20,000 cycles per second (Hertz). Ultrasonic waves are much higher in pitch and frequency, well beyond the range of human hearing. For ultrasound, frequency is measured in millions of cycles per second in units called megahertz (MHz). The frequency of probes for abdominal sonography is between 3 MHz and 6 MHz. Commonly, the frequency of transvaginal probes is between 5 MHz and 10 MHz.



2.7: Frequency vs. Resolution: Practical Limits

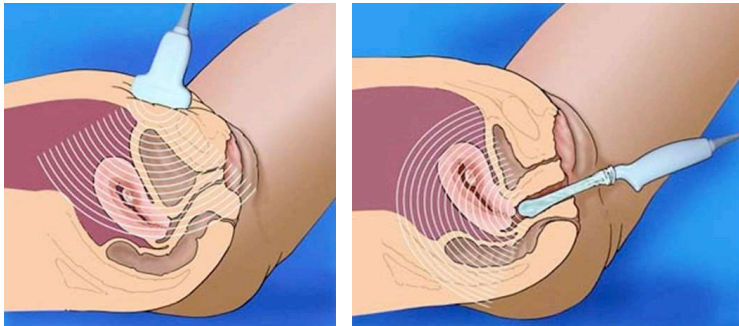


Frequency affects resolution (the clarity of the image). Probes set at higher frequency provide more detail.



When objects are small and close together, they may be indistinguishable from one another with a low-frequency probe, while a high-frequency probe can show them as separate objects.

2.8: Frequency and Depth of View



Transabdominal ultrasound

Transvaginal ultrasound

Although higher frequency sound waves give better resolution, they cannot travel as far as lower frequency waves. High-frequency transducers such as the vaginal probe are useful only when they can be placed close to the object being studied. In early pregnancy, the uterus is small and the probe tip is placed close to the cervix, giving a detailed view of an early pregnancy. If a pregnancy is more advanced, a lower-frequency probe (abdominal probe) allows greater depth

of vision to see the whole pregnancy.

2.9: Overall Gain



Time gain compensation (TGC):

Amplification of echoes from deeper reflectors is greater than from shallower reflectors.

Sound energy grows weaker the further it has to travel to the transducer. For this reason, deeper reflectors that are just as large as shallower reflectors will produce weaker echoes and will be "seen" by the ultrasound system as less intense unless there is some way to compensate. This compensation is accomplished by differentially amplifying echoes from deeper reflectors. This process is called time gain compensation and is abbreviated TGC.



Ultrasound systems usually use a series of slide switches or knobs to control time gain compensation. The position of a particular switch or knob corresponds to the part of the image that it affects. Generally, the TGC switches corresponding to progressively deeper areas of the image must be positioned further to the right to create a smooth, uniform image. A TGC curve can be displayed that shows the degree to which various portions of the image are amplified. During the course of an ultrasound scan, it is common for the operator to periodically readjust the TGC switches to optimize image quality.

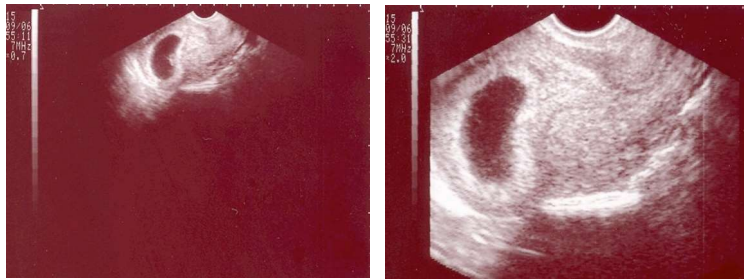


In addition to TGC switches, a knob that controls overall gain is usually present. Although the overall gain knob lightens or darkens the image, this control is different from the brightness and contrast knobs on the video screen. The overall gain knob controls overall amplification of returning echoes.



On the ultrasound shown in the photograph, the gain knobs are shown in the large box on the left side of the control keyboard. The depth knobs are shown in the smaller box on the right side of the control keyboard.

2.10: Image Depth



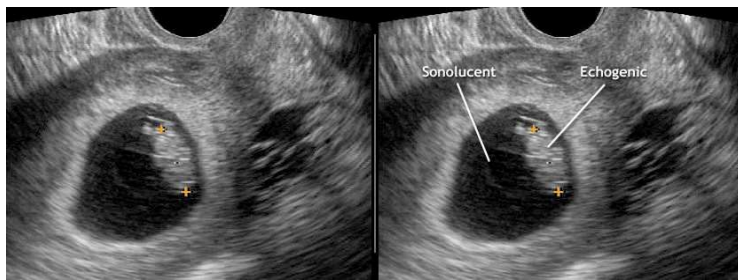
Depth not properly adjusted

Depth properly adjusted

The depth of the ultrasound image can be adjusted to allow visualization of deep structures. Depth can also be adjusted to remove unused space from the bottom of the image. For structures close to the transducer, decreasing the depth effectively enlarges the view of the structures of interest. This example shows a transvaginal image of an early pregnancy. On the left, the depth has not been properly adjusted. On the

right, the depth has been adjusted properly and the pregnancy is much easier to view. In addition, when depth is set correctly, detail within the gestational sac, such as the yolk sac or embryo, are seen.

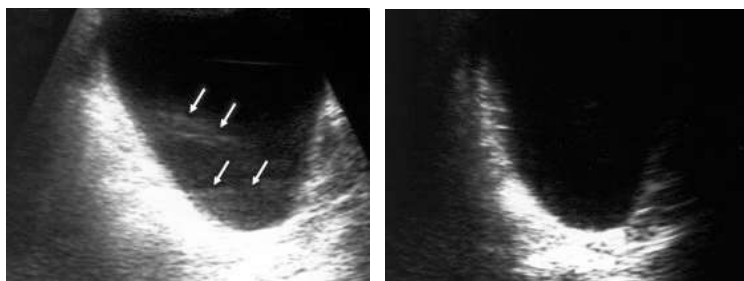
2.11: Acoustic Impedance



Sound energy is reflected from tissue. Solid tissue, for instance bone, is dense and produces a bright reflection. This brightness is called echogenic. Areas that do not produce echoes, such as fluid, are called sonolucent. This image shows an early pregnancy. The fluid in the gestational sac is sonolucent. It appears dark or black on the screen. The embryo is comprised of solid tissue and

appears lighter or white on the screen. This is called echogenic.

2.12: Reverberation Artifact



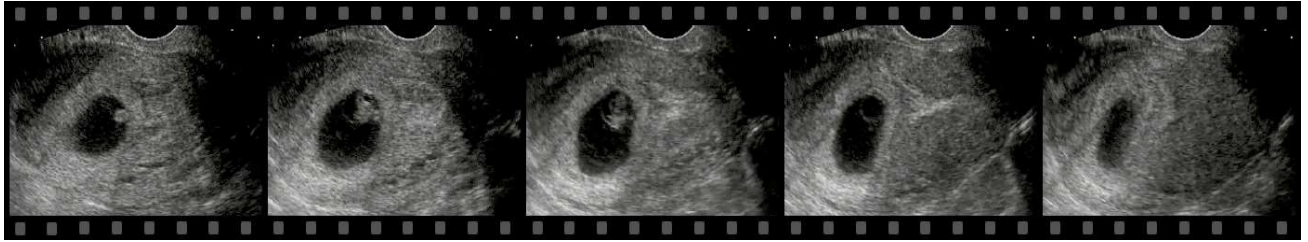Reverberation artifact

Artifact diminished by reducing gain

An artifact is a distortion of the image on the screen so that it may not represent the tissues beneath the probe. These artifacts are due to the physical characteristics of the sound waves and how they appear on the ultrasound machine. To some degree, artifact is present in most images. Understanding how and why artifacts are created will aid in your interpretation of ultrasound findings. Artifacts that are encountered

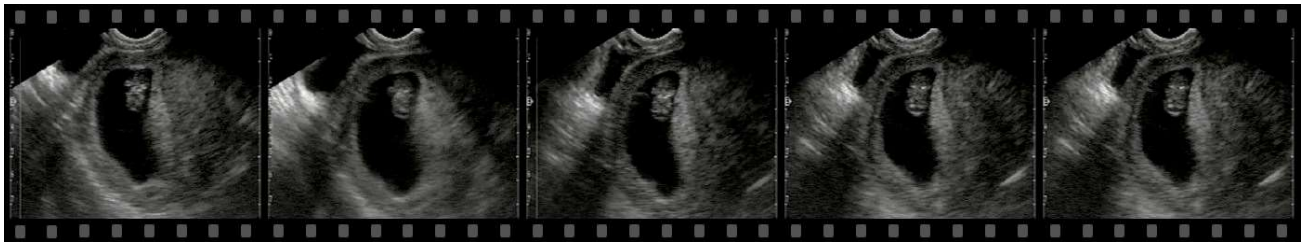while images are being obtained are discussed. One type of artifact is called reverberation. Reverberation artifacts are phantoms that appear on the ultrasound screen because of echoes that bounce between the probe and tissues. They are most commonly seen in fluid-filled spaces, such as the gestational sac. Care must be taken to distinguish the yolk sac from artifact. Artifacts can often be diminished by decreasing the gain.

2.13: Freeze Frame and Cineloop

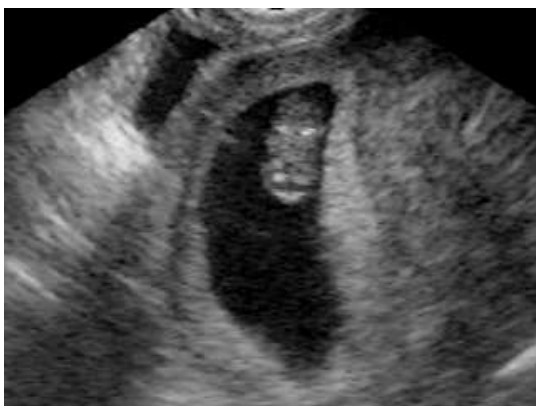

You need to freeze the moving image to take measurements and for printing an image for the medical record. Some systems store a series of previous frames in the computer's memory so that the last several seconds of images can be retrieved.

2.14: Machine Controls: Electronic Calipers

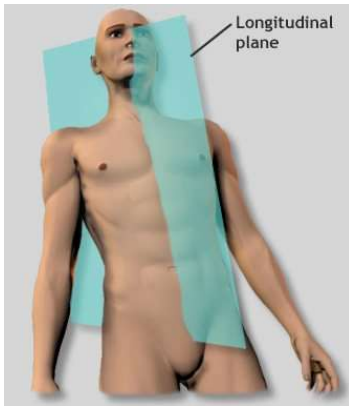


It is essential to be able to perform measurements to date the pregnancy. On-screen measurements are more accurate than those performed later on printed images. The ultrasound machine has electronic calipers to use when performing on-screen measurements. The operator uses a tracking ball or other pointing device to locate and set the calipers at desired points. The software calculates and displays the measurement.



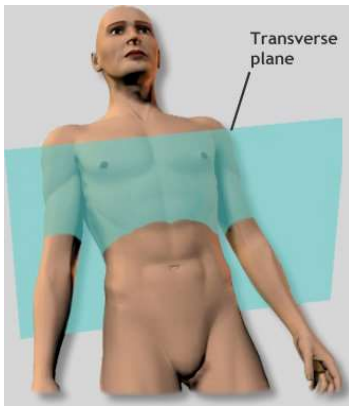
Practice measuring by setting the calipers and performing a measurement of the length of the embryo in this image. You can mark it with a pencil or decide mentally where to place the calipers. The answer key is at the end of the workbook.

2.15: Imaging Planes: Longitudinal



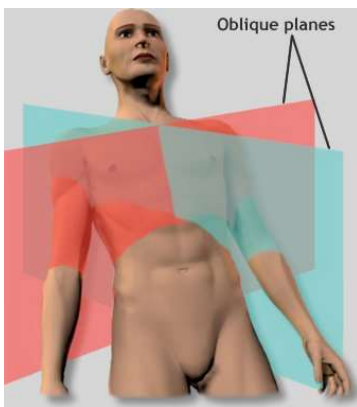
Imaging planes along the long axis of the body are longitudinal. The longitudinal plane that cuts the body in half lengthwise is the midline longitudinal plane.

2.16: Imaging Planes: Transverse



The crosswise axis of the body is called the transverse plane.

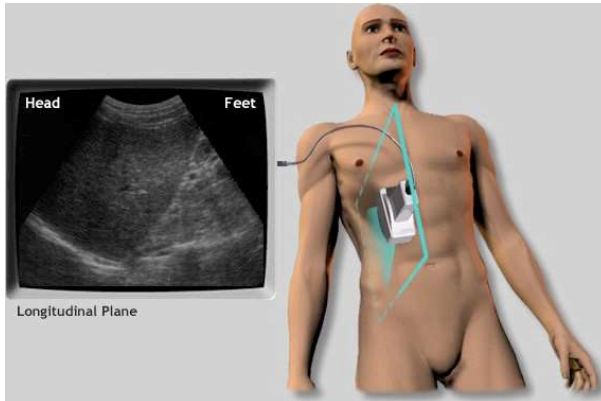
2.17: Imaging Planes: Oblique



Imaging planes at other angles are oblique.

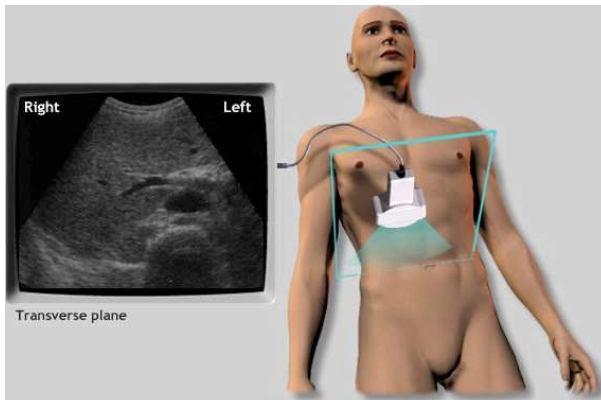
2.18: Standard Image Orientation

Longitudinal Plane



Ultrasound images are oriented in a standard way. This is an image of a liver ultrasound, but it demonstrates the principles of the longitudinal and transverse planes. When scanning in a longitudinal plane, the operator holds the transducer in such a way as to cause the end of the image toward the patient's head to be off the left side of the video screen and the end of the image toward patient's feet to be off the right side.

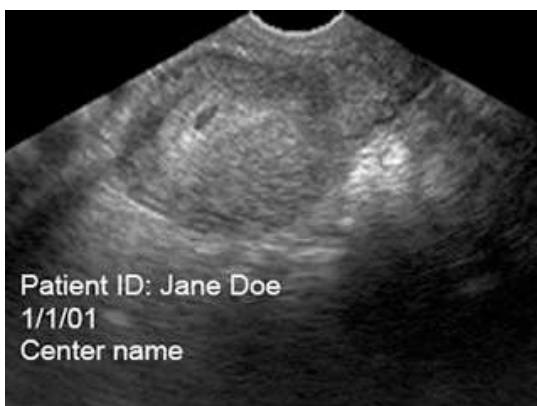Transverse Plane



When scanning in a transverse plane, the operator holds the transducer in such a way as to cause the patient's right side to be displayed to the left side of the video screen and the patient's left side to be displayed on the right side of the screen. This is the same as viewing the body from the foot of the examination table.

In Chapter 4, we will discuss how to position the ultrasound probes and how to perform a systematic scan.

2.19: Image Labeling



Ultrasound images should be labeled with the patient's name and the date of the scan.

2.20: Permanent Record and Documentation



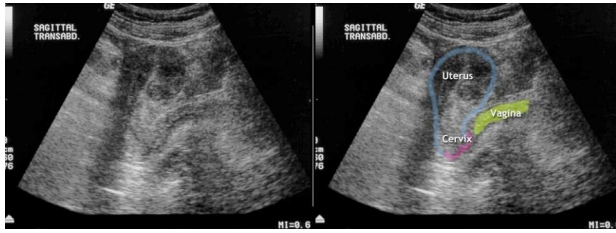A permanent record should be made of each ultrasound study, including an interpretation of the clinical significance of findings.

A printed copy of ultrasound images should be part of the medical record or a digital image should be a permanent part of the electronic medical record. Documentation in the record should include:

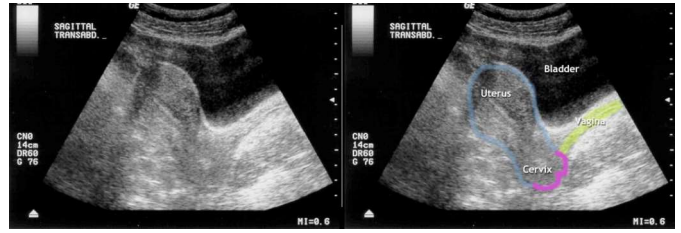
- Name of the patient
- Medical record number
- Date of scan
- Name of health center where the scan was performed
- Name of operator
- Findings (i.e., number of gestational weeks, cardiac activity seen, etc.)

Gestational age by ultrasound is commonly indicated by menstrual weeks, for instance 6w3d or 6 3/7.

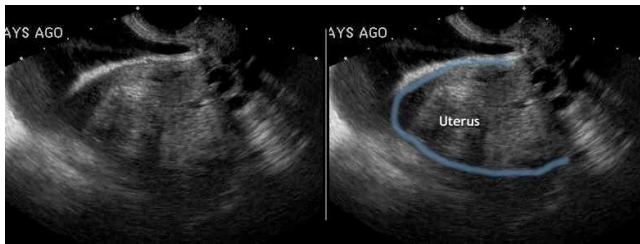
3.1: Bladder Filling



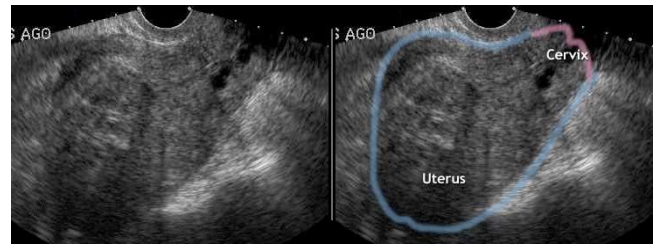
Transabdominal scan with empty bladder



Transabdominal scan with full bladder



Transvaginal scan with partly filled bladder



Transvaginal scan with empty bladder

When scanning by the transabdominal route, it is usually helpful, and often essential, for the client to have a relatively full urinary bladder. The full bladder displaces bowel so the uterus can be seen. Bowel contains gas that scatters ultrasound energy, blocking the view.

In contrast, a full bladder on transvaginal sonography may result in reverberation artifact, as seen in the third image. Commonly a full bladder may displace the uterus, making it difficult to visualize. Prior to performing transvaginal ultrasound, the patient should be instructed to empty her bladder.

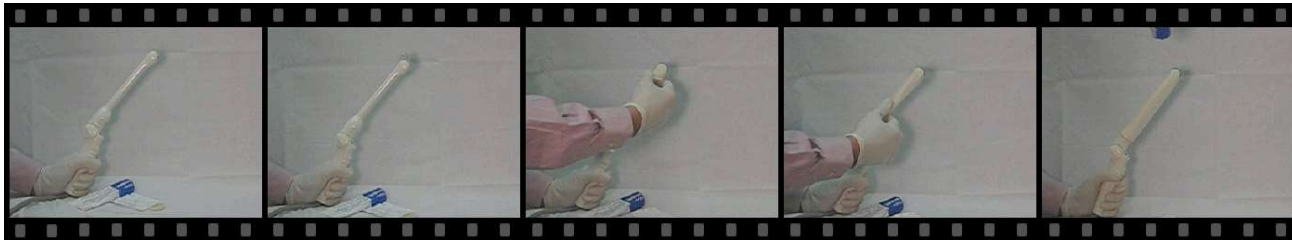3.2: Transducer Cleaning



Placing transducer in cleaning solution

All transducers should be cleaned between patients according to the manufacturer's instructions and local protocols and regulations. Care should be taken to use only cleaning solutions that are considered safe by the manufacturer. This is particularly important if transducers are to be soaked, since some solutions can erode seals and ruin the transducer. The policy of your agency for disinfecting the probe between each patient use should be followed.

3.3: Transvaginal Transducer Preparation for Transvaginal Scanning



Covering transducer with condom

Prior to transvaginal scanning, the clean transducer is prepared by placing a small amount of ultrasound gel directly on the transducer.

Then it is covered with a clean membrane such as a condom, plastic sheath or examination glove. Some agencies require that condoms, not plastic sheaths or examination gloves be used, since condoms create a better barrier against most organisms than exam gloves or probe sheaths. Ask the client if she has a latex allergy. If she does, use a latex-free material as a cover. Then check to ensure that large air bubbles are not between the transducer and the cover. Bubbles trapped between the transducer and cover can markedly decrease the quality of the image.

Then, lubricating gel is applied to the tip of the covered transducer to ease its insertion into the vagina. Some clinicians ask the client if she wants to insert the transducer herself.

3.4: Transvaginal Transducer Care After the Scan is Finished



Removing cover and cleaning transducer

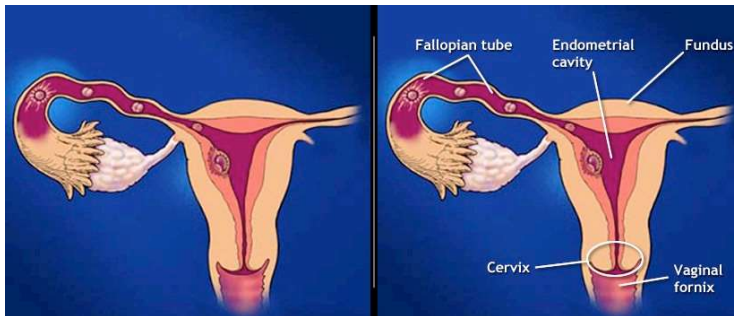
After the scan is finished, the cover is discarded and the probe is cleaned. The probe is sprayed or wiped with disinfectant solution between patients. Use the procedures approved by your agency to disinfect the vaginal probe between each patient.

3.5: Counseling Points

- Inquire about latex allergy.
- Ask the client if she wants to see the ultrasound screen.
- Ask the client if she wants an explanation of the sonographic findings.

The counseling vignette shown in chapter 1 included several points that are discussed prior to performing the scan. These are again summarized here. They include: Inquiring about latex allergy. Asking the client if she wants to see the ultrasound screen. Asking the client if she wants an explanation of the sonographic findings.


4.1: Introduction to the Anatomy of the Female Pelvis



The uterus, cervix, fallopian tubes and ovaries are discussed in this course. Since the structures of the female pelvis are discussed in detail in this course, it's important to be familiar with the terms being used.

4.2: Scanning Routes: Transabdominal and Transvaginal

Comparison of features of pelvic scanning routes

<p>Transabdominal</p> <ul style="list-style-type: none">• Able to see structures outside of pelvis• Lower spatial resolution (3 to 5 MHz transducers)• Free transducer maneuverability• Full urinary bladder improves visualization		<p>Transvaginal</p> <ul style="list-style-type: none">• Limited to pelvic structures• Higher spatial resolution (5 to 7.5 MHz transducers)• Limited transducer maneuverability• Full urinary bladder decreases visualization
---	--	--

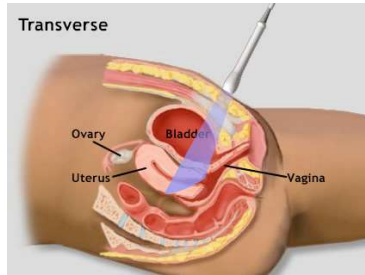
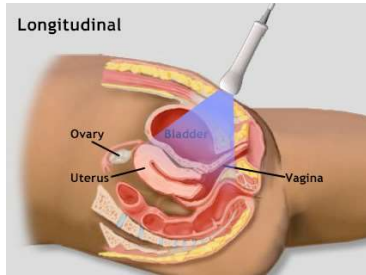
Ultrasound imaging of the female pelvis may be accomplished by both the transabdominal and the transvaginal routes. Each has its advantages and disadvantages, as shown in this table. Probes used for transvaginal scanning generally employ higher frequencies than those used for the transabdominal route. For this reason, transvaginal probes produce improved spatial resolution, but visualization is limited to pelvic structures. Maneuverability of a probe positioned inside the vagina is also limited. Transabdominal scanning allows visualization of structures that may rise out

of the pelvis, out of the range of view of a transvaginal transducer.

A complete ultrasound of the pelvis involves both abdominal and transvaginal imaging. In an ultrasound targeted to date the pregnancy in an asymptomatic patient, typically either an abdominal or a transvaginal scan is adequate. The most important goal of the scan is to identify the structures which confirm a normal intrauterine pregnancy. Those structures will be discussed in detail in further chapters.

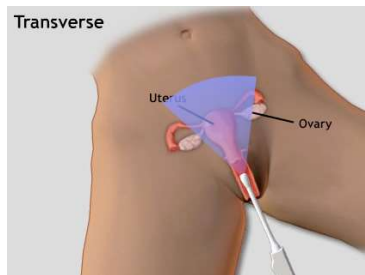
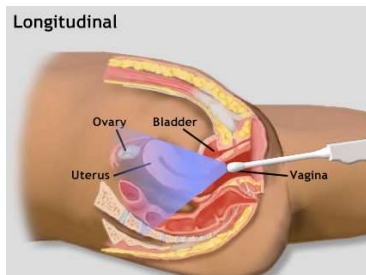
4.3: Anatomic Planes and Probe Positions Used to Scan the Pelvis

Abdominal scan



The pelvis is imaged sonographically in two planes: longitudinal and transverse. Here, we see a transabdominal scan in the midline longitudinal plane, along the long axis of the woman's body, and then in the transverse plane, cutting across the woman's body. In some textbooks, you may see the term "sagittal" in place of longitudinal.

Transvaginal scan

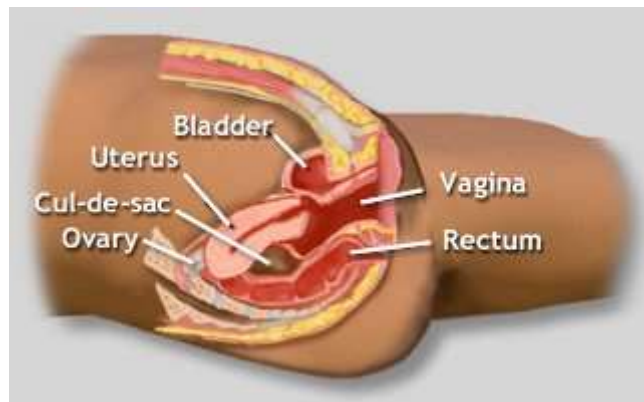
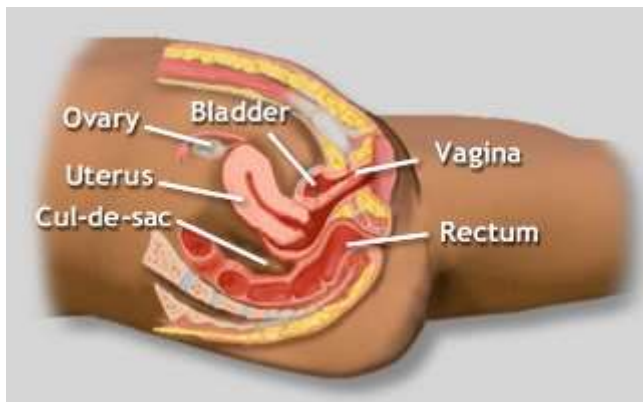


With transvaginal scanning, longitudinal and transverse views are also obtained. When using transvaginal scanning, transverse views are usually parallel to the patient's back. Technically, transverse views from transvaginal imaging are called "coronal" but this term is not commonly used in gynecologic ultrasonography.

The term "oblique" may be used to describe any view that is obtained at an angle between the longitudinal and transverse views.

4.4: Longitudinal Transabdominal Scan Plane Images

Uterus diagrams



Anatomic diagram in the longitudinal plane of anteverted uterus

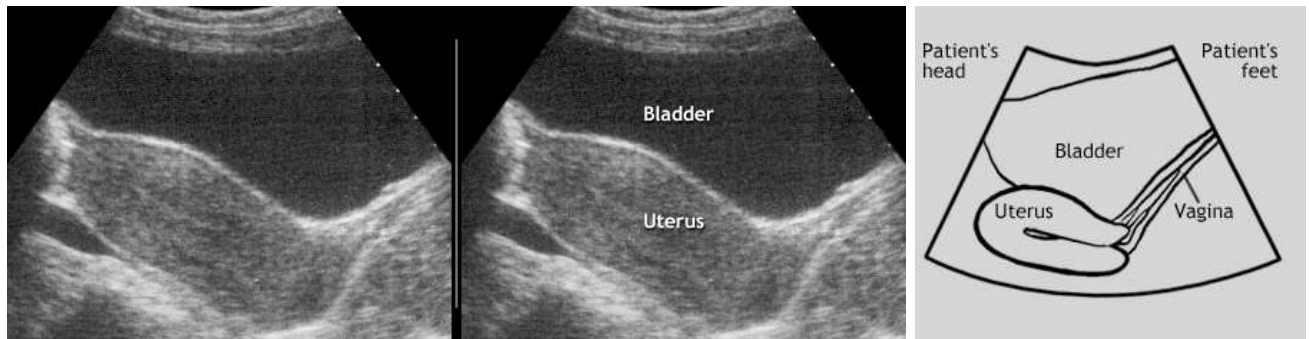
Anatomic diagram in the longitudinal plane of retroverted uterus

In the longitudinal transabdominal views of the pelvis, the uterus, cervix and vagina are seen. The

uterus may normally be in either an anteverted or retroverted position. Longitudinal view to the left or right of the uterus may reveal the ovaries. The "cul-de-sac" is seen between the uterus and the rectum.

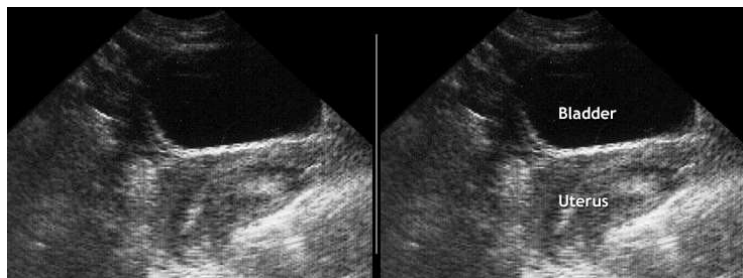
The diagram on the left shows an anteverted uterus seen in the longitudinal plane. The diagram on the right shows a retroverted uterus seen in the longitudinal plane.

Anteverted uterus through full bladder



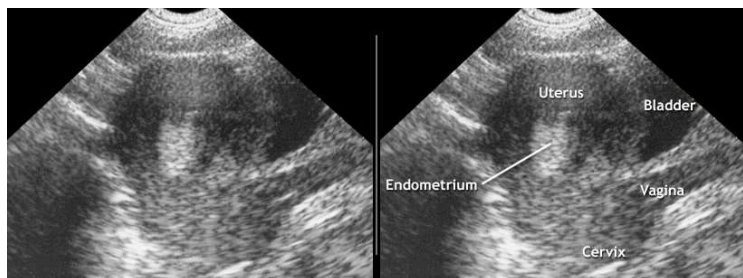
This image and the corresponding diagram show an anteverted uterus seen in the longitudinal plane through a full bladder.

Retroverted uterus through full bladder



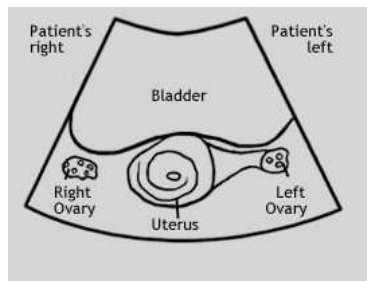
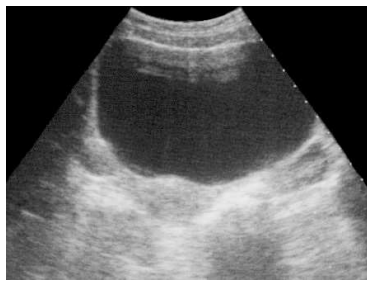
This image shows the sonographic appearance of a retroverted uterus seen in the longitudinal plane through a full bladder.

Anteverted uterus through partially filled bladder



If the bladder is only partly filled, an anteverted uterus points straight up at the transducer. If the uterus is retroverted and the bladder is only partly filled, the uterus is often difficult to see transabdominally.

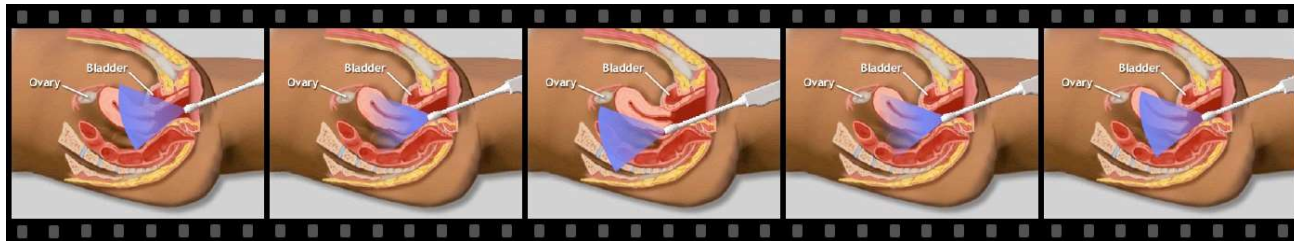
4.5: Transverse Transabdominal Scan Plane Images



In transverse transabdominal views through a full urinary bladder, the uterus or cervix and sometimes the ovaries are seen. This diagram and corresponding image show the sonographic appearance of an anteverted uterus seen in the transverse plane through a full urinary bladder.

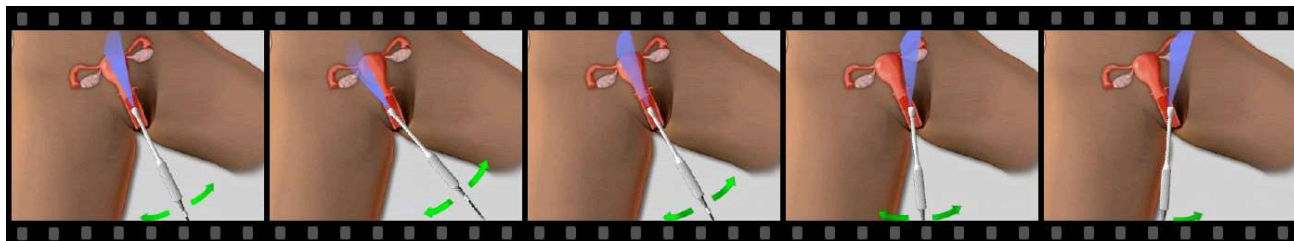
Transverse image diagram

4.6: Longitudinal Transvaginal Scan Plane Image



Transvaginal imaging allows the uterus and cervix to be seen in greater detail than produced by transabdominal scanning. The midline longitudinal view is the most commonly used view to document the uterus and cervix and is one of the simplest to obtain.

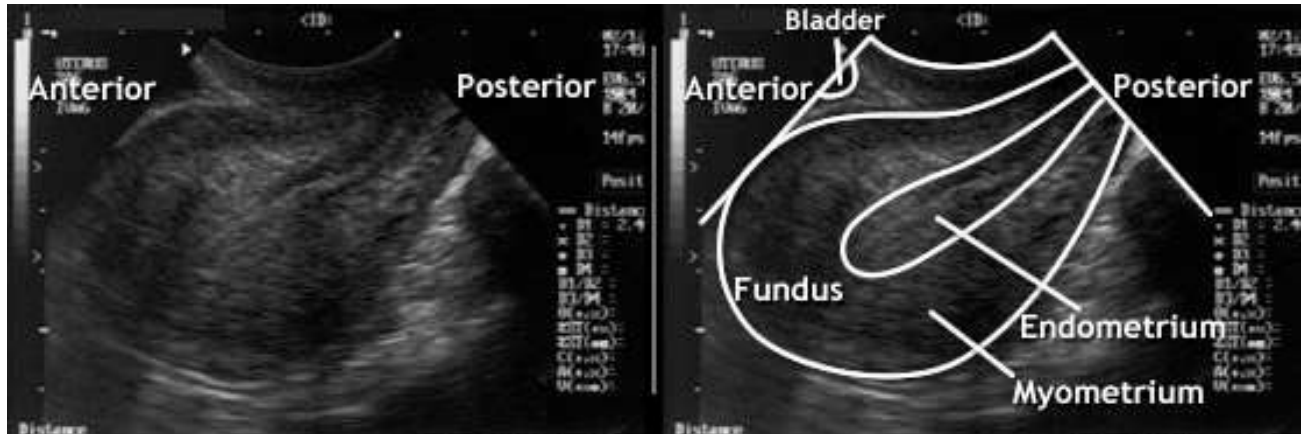
The depth to which the transducer is advanced has a profound effect on what structures are within the field of view. If the transducer is not advanced far enough, some structures may be outside its short field of view. Advancing the transducer too far into either the anterior or posterior vaginal fornix may leave some pelvic structures behind the transducer and out of its field of view.



To see the ovaries, the transducer usually must be moved laterally to the patients left and right. The transducer may be kept in the longitudinal view as shown here as it is angled to the left or right to obtain left and right longitudinal views.

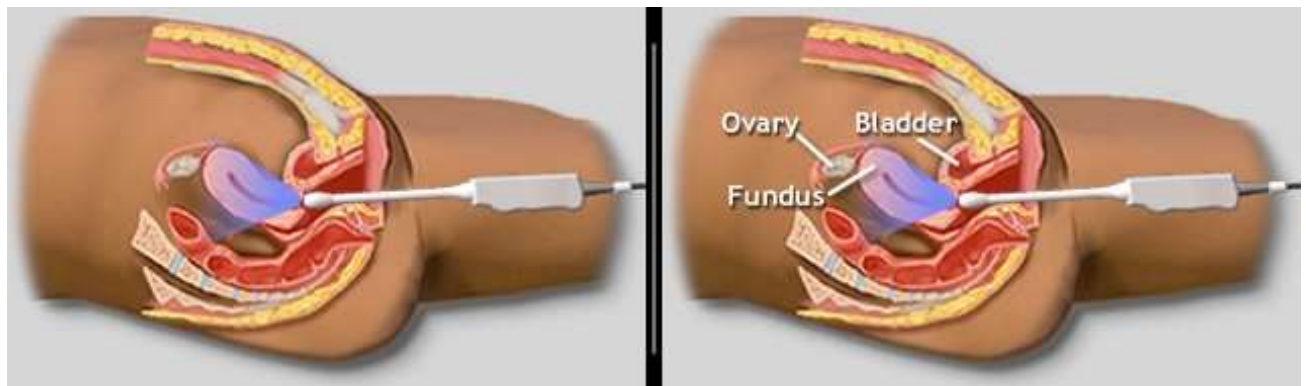
4.7: Longitudinal Transvaginal Scan: Anteverted and Retroverted Uterus

Anteverted uterus



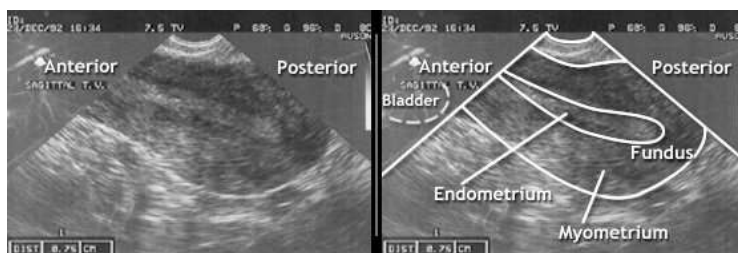Anteverted uterus

When a transvaginal scan is done in the longitudinal plane and the uterus is anteverted, the image appears with the fundus on the left side of the screen. The fundus should be adjacent to the bladder.



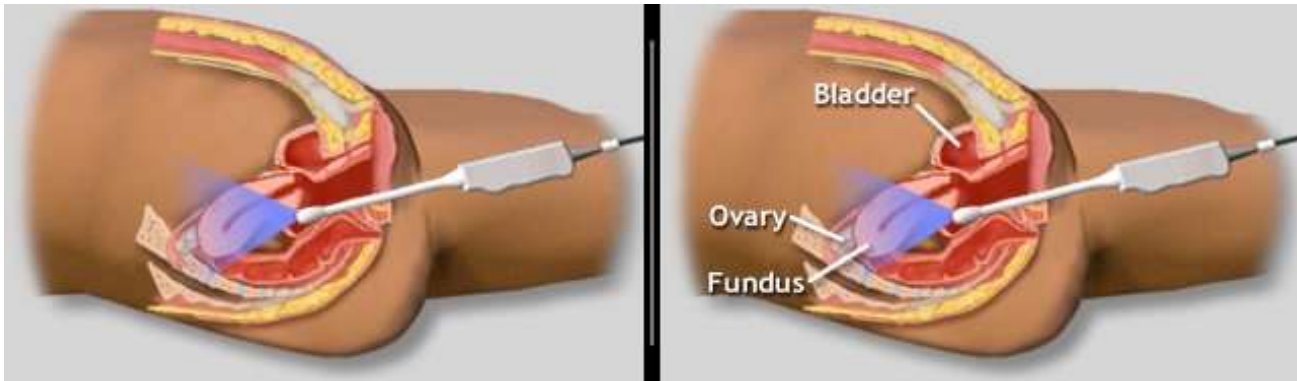
Anteverted uterus

Retroverted uterus



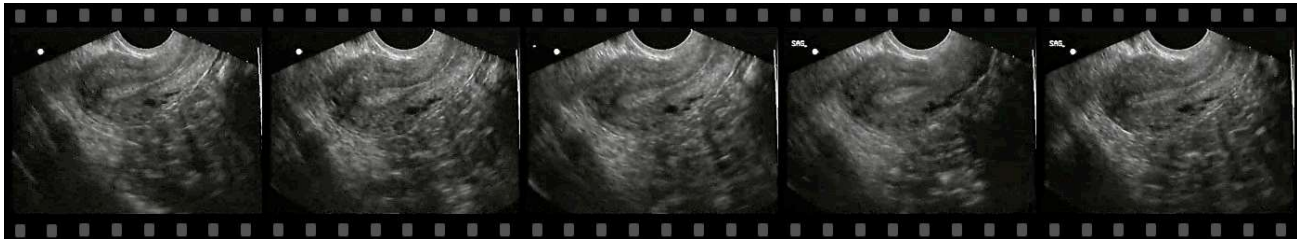
Retroverted uterus

When a transvaginal scan is done in the longitudinal plane and the uterus is retroverted, the image appears with the fundus on the right side of the screen. The fundus will be opposite from the bladder and will be adjacent to the rectum, which may not be seen.



Retroverted uterus

4.8: Longitudinal Transvaginal Imaging of Anteverted & Retroverted Uterus

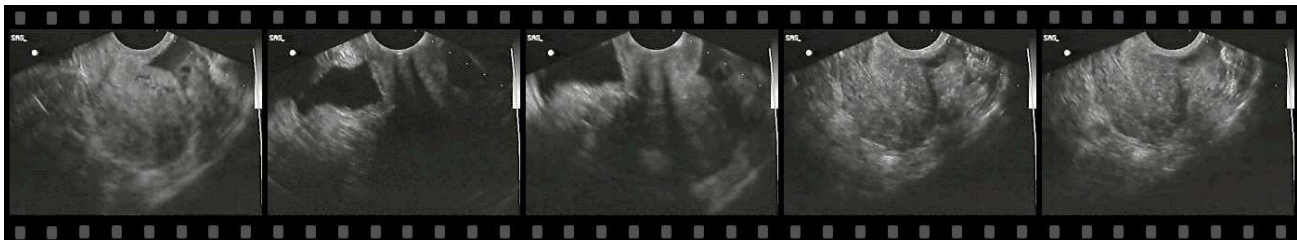


Anteverted uterus

The first row of video frames shows a normal, empty, anteverted uterus. The next row of video frames shows a normal, empty, retroverted uterus. In both cases, the patient's head is towards the bottom of the video and her feet are towards the top. The anterior abdominal wall is to the left of the video. This orientation seems unusual at first and may take some time to become used to.

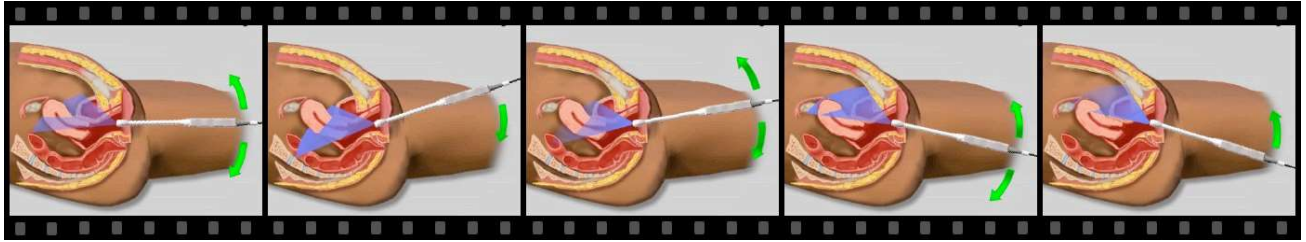
If you are viewing the CD-ROM, click the play button on the anteverted uterus video. The bladder briefly comes into view just to the left of the transducer. Notice the peristalsis of the bowel behind the uterus. This is normal. The round sonolucent structures towards the edge of the myometrium are arcuate blood vessels. These are often prominent in women who have carried a pregnancy to term.

If you are running the CD-ROM, click the play button on the retroverted uterus video. The bladder briefly comes into view and fills the left side of the video. It is anterior to the uterus, just to the left of the transducer. When the transducer is drawn back, a small amount of sonolucent fluid is seen posterior to the uterus. This is called "free-fluid" in the cul-de-sac.



Retroverted uterus

4.9: Transverse Transvaginal Plane Images

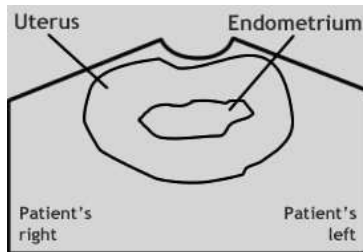
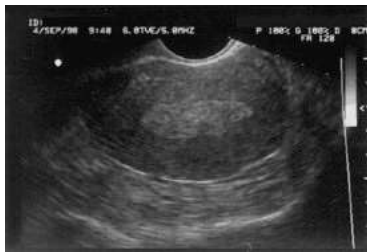

In transverse transvaginal views, the urinary bladder, uterus, cervix and ovaries are seen in greater detail than produced by transabdominal scanning.

Whether the probe is in the longitudinal or transverse position, to visualize the uterus, you may need to change the angle of the probe. If the uterus is anteverted, the handle of the transducer may need to be lowered toward the floor because the sound beam needs to be directed upward. If the uterus is retroverted, the handle of the transducer may need to be elevated upward, which directs the sound beam toward the patient's spine.

If you are running the CD-ROM, click and drag the transducer to move the handle of the transducer downward toward the floor and upward, and notice how the sound beam is re-directed.

4.10: Transverse Transvaginal Plane: Image of Uterus

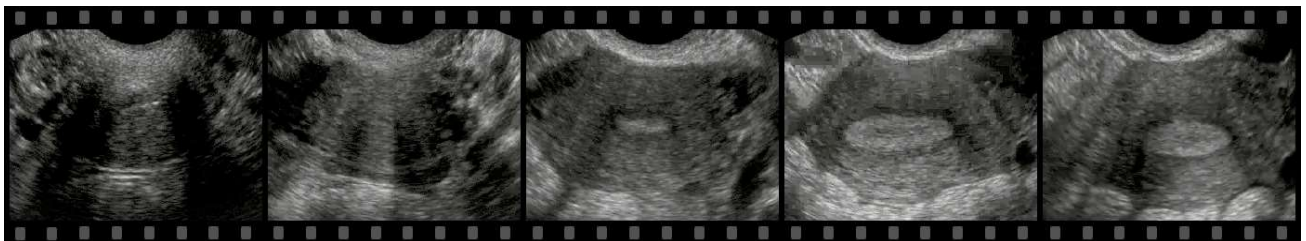

Anteverted uterus

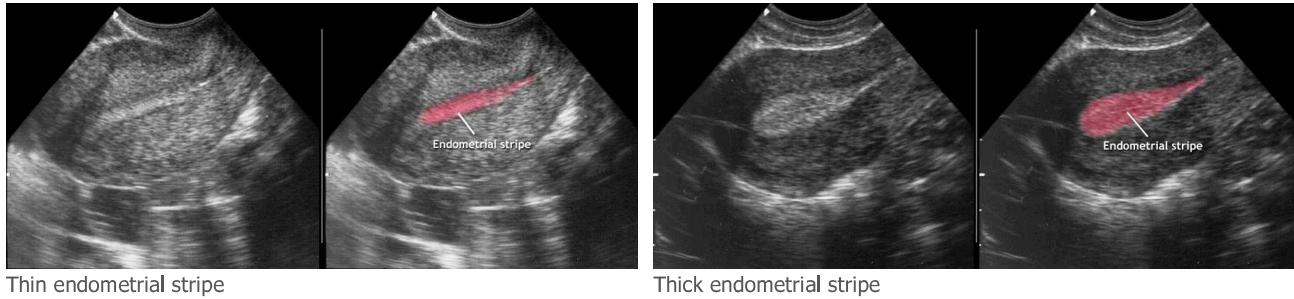
Images

A typical transverse image of the uterus at the level of the fundus is shown here.

Video frames



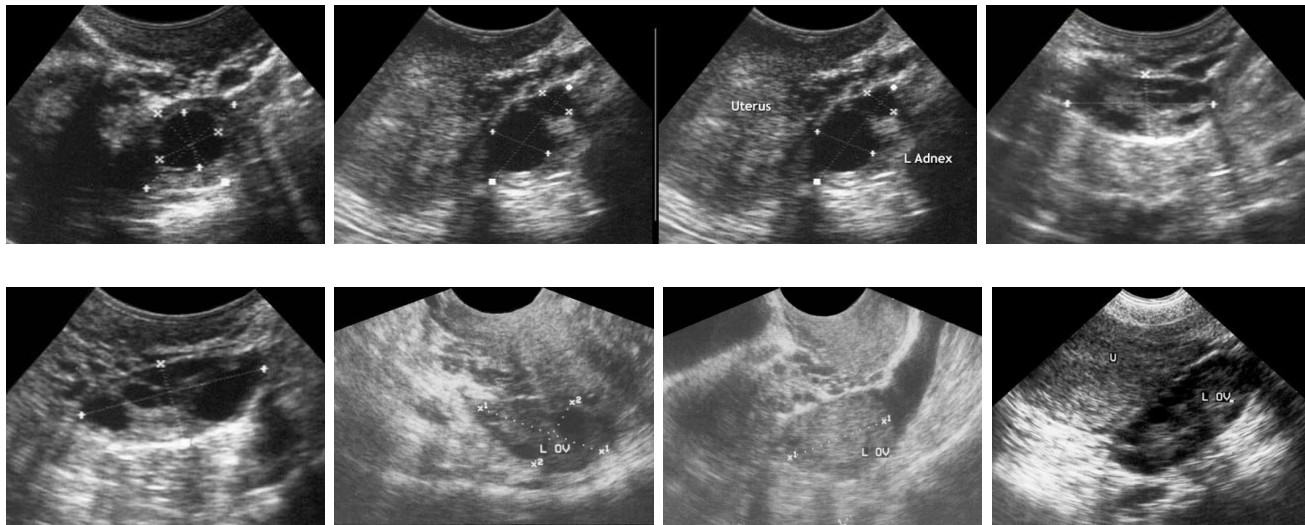
4.11: Endometrial Thickness or Stripe

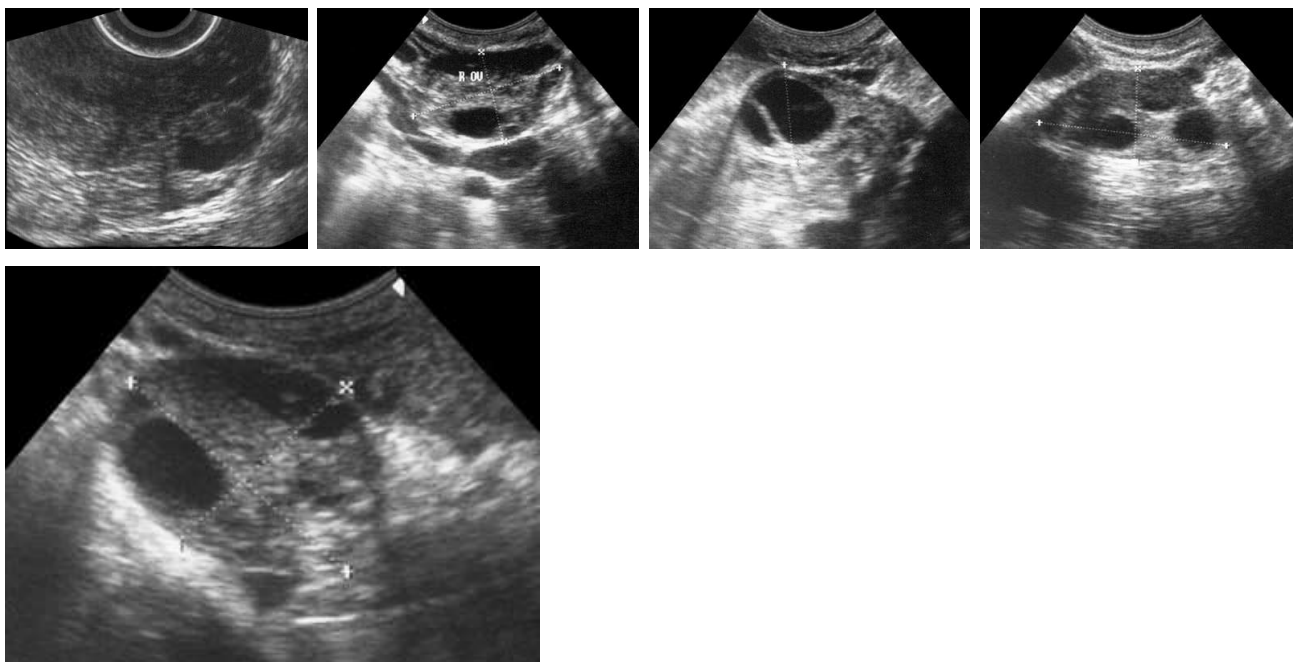


The endometrium (layers of the uterine lining) is more echogenic than the surrounding myometrium (muscle tissue of the uterus) and varies in thickness depending on the stage of the menstrual cycle. These transvaginal longitudinal images of an anteverted uterus show the thin endometrial stripe seen early in the cycle and the thick endometrial stripe seen late in the cycle. A thick endometrial stripe is not abnormal in a menstruating woman. In the postmenopausal woman with vaginal bleeding, a thick endometrial stripe may indicate hyperplasia or cancer.

The image on the right with the thick endometrial stripe has the classic "triple line" appearance of the late proliferative phase of the cycle (in the first half of the menstrual cycle) and will become more homogeneously echogenic as it becomes more secretory in the second half of the menstrual cycle.

4.12: Ovaries



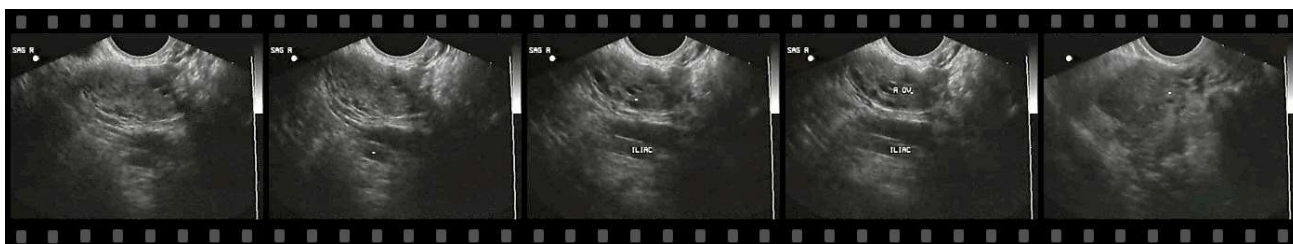

This is a gallery of images of normal ovaries. If you're running the CD-ROM, click on any image to see an enlargement. Ovaries vary widely in size and sonographic appearance. They often contain multiple sonolucent follicular cysts, which are best seen during transvaginal scanning. Just prior to ovulation, a normal mature follicular cyst can be up to 3 cm in diameter. The ovaries often lie adjacent to the iliac vessels.

4.13: Finding the Ovaries



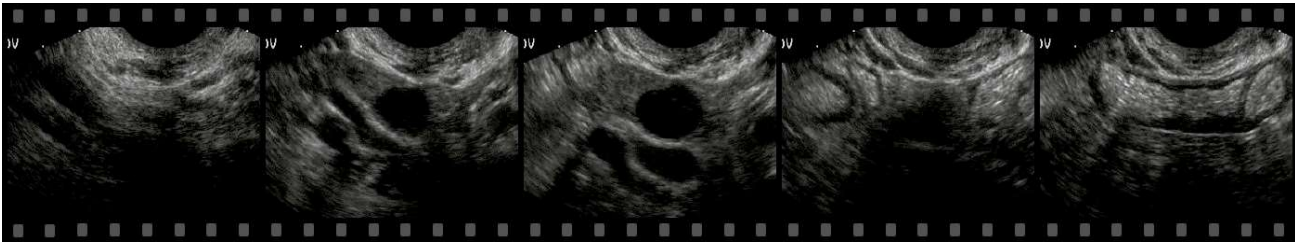
Case 1



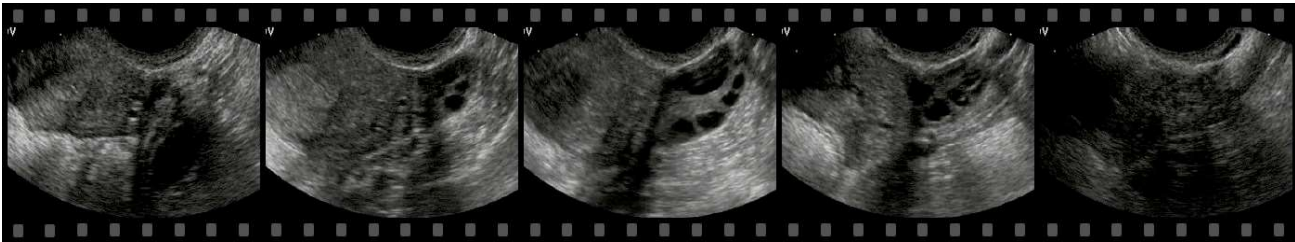In patients who have not had pelvic surgery, the ovaries often lie near the iliac arteries which can be seen pulsating during real-time scanning and therefore are excellent guideposts to identification of the ovaries as seen in these video frames. Because they are tethered to the uterine cornua, the ovaries are often located just lateral to the uterine fundus.

It may take considerable practice for learners to be able to identify the ovaries. In some patients, one or both ovaries may not be visible due to obscuring bowel or other reasons.

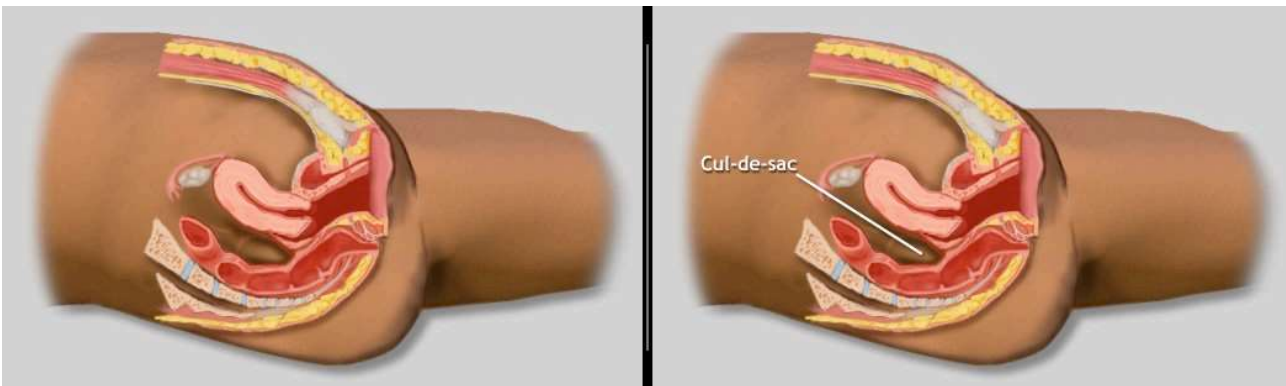
Case 2



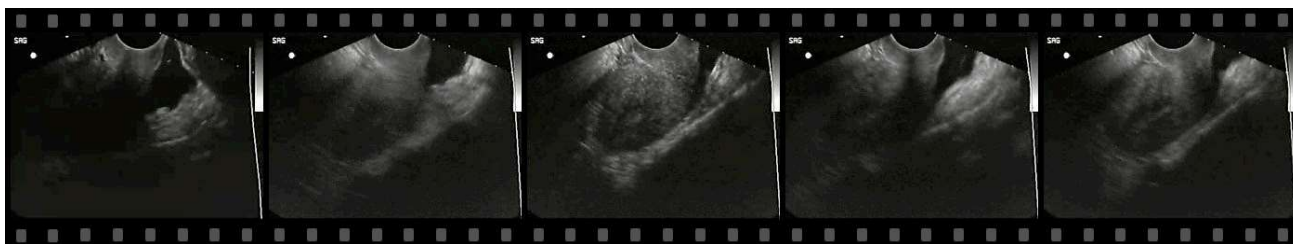
Case 3



4.14: Cul-de-Sac

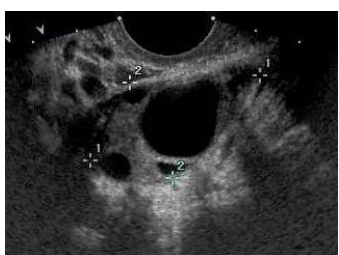

The cul-de-sac is a potential space behind the uterus occupied by bowel or obliterated as the uterus lies against the rectum. It normally can contain a few milliliters of sonolucent fluid that often can be seen during transvaginal scanning. It is important to identify fluid in the cul-de-sac because it can be related to the presence of an ectopic pregnancy. Since it is the lowest portion of the peritoneal cavity, fluids collect in the cul-de-sac before other areas. The fluid may be blood from a ruptured ectopic pregnancy or a hemorrhagic ovarian cyst, but it may not be possible to know from the sonogram alone.

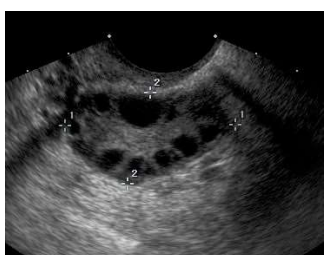

These video frames show cul-de-sac fluid in a patient with a leaking ovarian cyst, but the fluid can have a similar appearance with an ectopic pregnancy. The uterus is mid-position, neither anteverted nor retroverted. The bladder, containing urine, is seen toward the end of the video. Bowel is seen between the uterus and bladder.

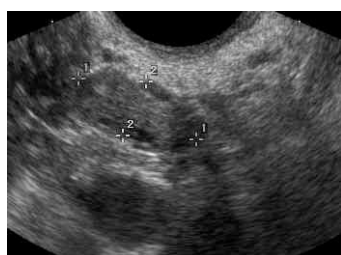4.15: Additional Images of Normal Ovaries



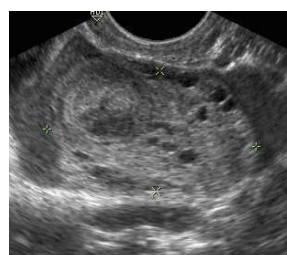Normal ovary with one large & one small cyst



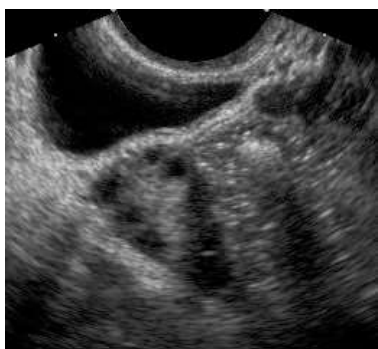Normal ovary containing many small cysts



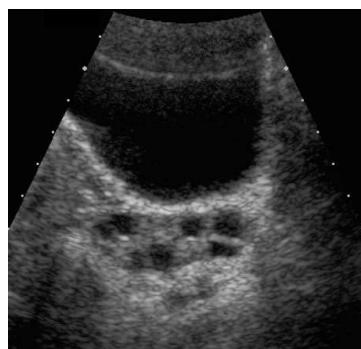Normal ovary



Normal ovary



Normal ovary



Normal ovary seen transabdominally

This gallery of images shows ovaries. The first image shows a corpus luteum cyst. Corpus luteum cysts are discussed in more detail in Chapter 6.

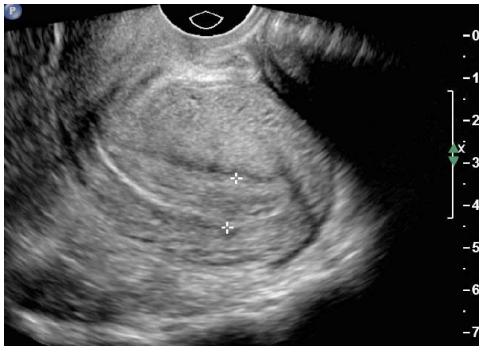
4.16: Uterine Position Exercises



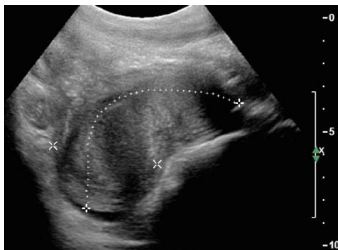EXERCISE: Anteverted vs. retroverted uterus

For each of these images, check the box indicating whether you believe the uterus is anteverted or retroverted. The answer key is at the back of the workbook.

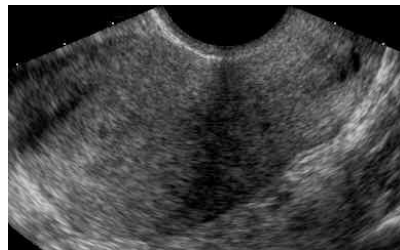
These exercises also help you to identify the outline of the uterus.



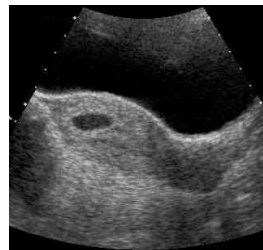The uterus in this transvaginal scan is: anteverted
 retroverted



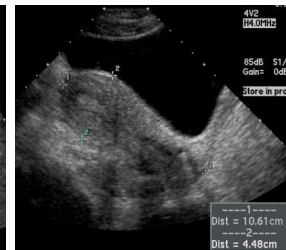The uterus in this transabdominal scan is: anteverted
 retroverted



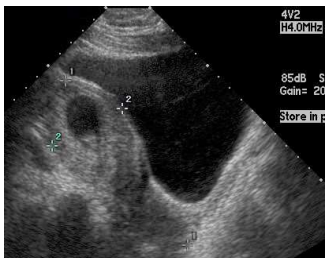The uterus in this transvaginal scan is: anteverted retroverted



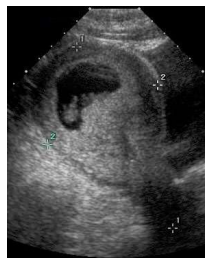The uterus in this transabdominal scan is: anteverted
 retroverted



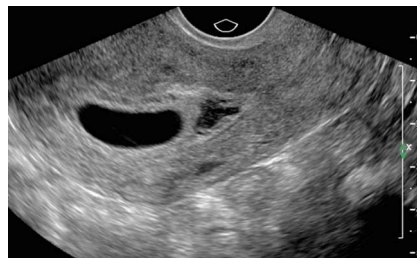The uterus in this transabdominal scan is: anteverted retroverted



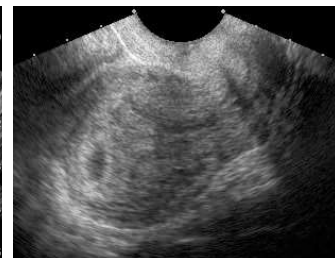The uterus in this transabdominal scan is: anteverted
 retroverted



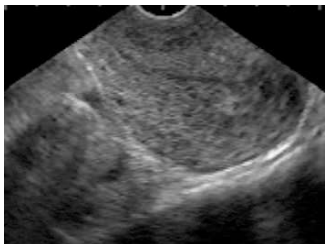
The uterus in this transabdominal scan is: anteverted
 retroverted



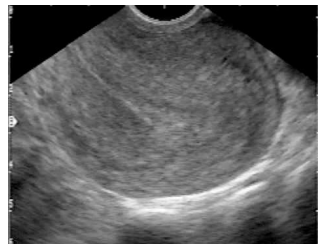The uterus in this transvaginal scan is: anteverted retroverted



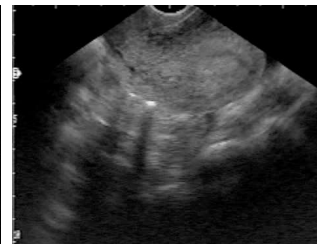The uterus in this transvaginal scan is: anteverted
 retroverted



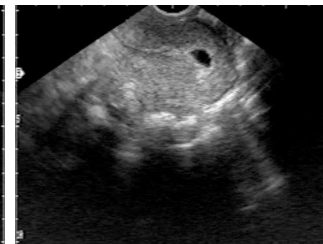
The uterus in this transvaginal scan is: anteverted
 retroverted



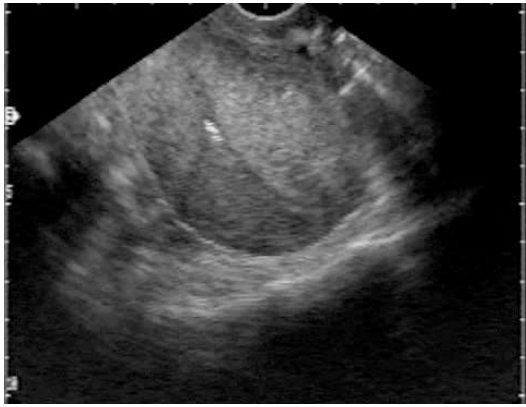
The uterus in this transvaginal scan is: anteverted
 retroverted



The uterus in this transvaginal scan is: anteverted
 retroverted

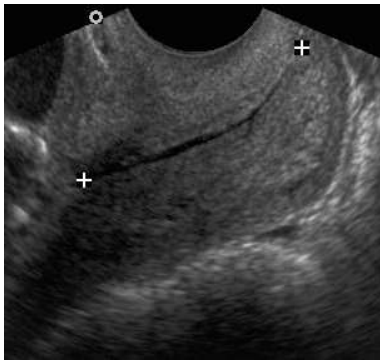


The uterus in this transvaginal scan is: anteverted
 retroverted

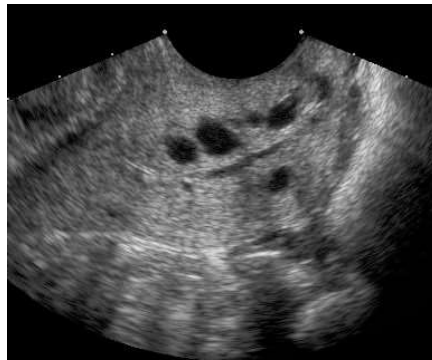

The uterus in this transvaginal scan is: anteverted
 retroverted

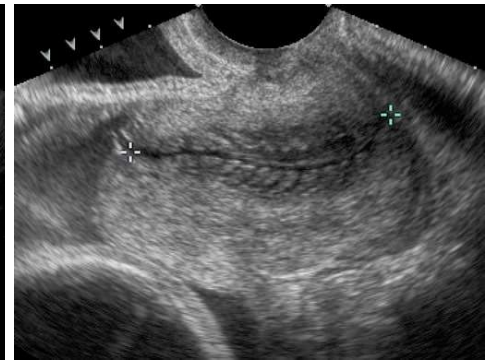
4.17: Cervix



Transvaginal scan of the cervix



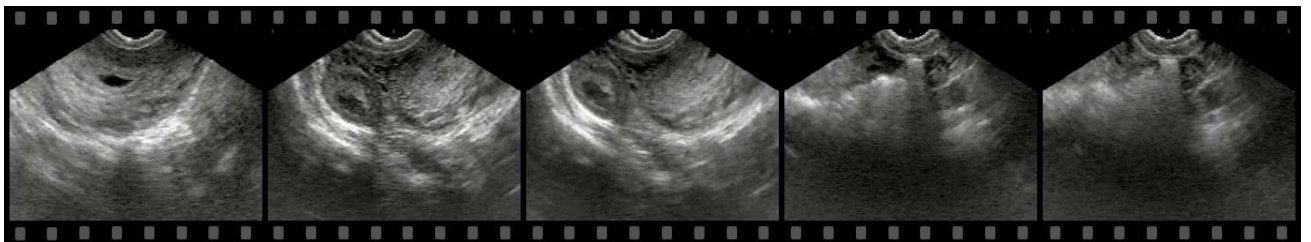
Transvaginal scan of the cervix with nabothian cysts



Transvaginal scan of the cervix showing plicae

This gallery of images shows the cervix. The second image shows Nabothian cysts, which are common and normal in the cervix. The third image shows cervical plicae. Plicae are the arrangement of endocervical mucosa which ascend laterally like the branches of a tree. These folds press together to close the canal.

4.18: Systematic Approach to Scanning the Pelvis



Overview Video #1 frames

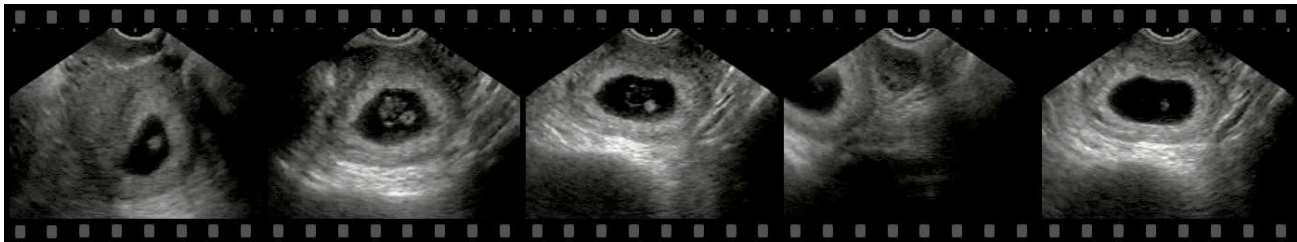It is important to perform a systematic scan. The uterus, and its contents, should be visualized in both the longitudinal and transverse planes. Effort should be made to visualize the ovaries in at least

one plane, if not both planes. There are several methods of performing a systematic scan. A commonly accepted method is described here.

A systematic approach to scanning the pelvis, rather than simply targeting the pregnancy is important to make sure the pregnancy is really intrauterine and to prevent missing other conditions such as adnexal masses, twin gestations, and free pelvic fluid. These video frames show such a systematic approach to scanning the pelvis.

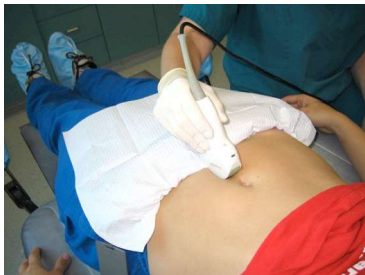One way to perform a systematic scan is to sweep across the uterus in the longitudinal plane (with the probe in the 12 o'clock position) and then to sweep across the pelvis from the patient's right to left in the transverse position (with the probe in the 9 o'clock position).

Based on the lessons just completed, you should be able to recognize the uterus, and often the ovaries in these video frames. The following slides will show you how to obtain similar images.

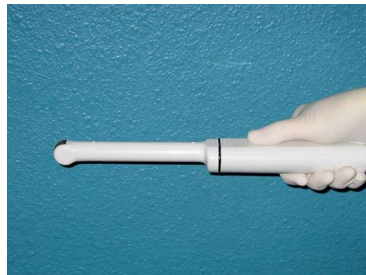

Overview Video #2 frames

4.19: Position of the Probe: Longitudinal



Abdominal probe, longitudinal position



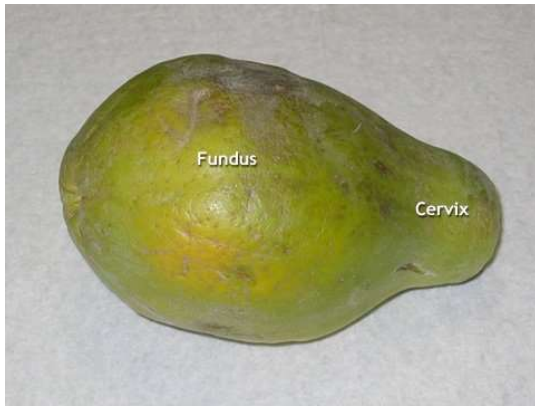
Transvaginal probe, longitudinal position

Every probe has a button or marker to indicate the "up" or 12 o'clock position. When the probe is held at the 12 o'clock position, pointing up toward the patient's head, the uterus is viewed in the longitudinal plane.

The photographs show both the transabdominal and transvaginal probes in the "up" position, providing a longitudinal view of the uterus. In the

image seen on the ultrasound machine with transabdominal imaging, the patient's head will be towards the left and the feet towards the right. With transvaginal imaging, the patient's head will be towards the bottom and the feet towards the top of the image seen on the ultrasound machine.

4.20: Papaya Model of Uterus



The uterus is shaped like a papaya. The narrow end resembles the cervix and the large, round end resembles the uterine fundus.

4.21: Longitudinal View: Papaya Model



Longitudinal cut: external view



Longitudinal cut: internal view

If the uterus is viewed with ultrasound in the longitudinal plane, its contents are revealed, just like the papaya that has been cut down the middle in these images. This view is referred to as the "papaya view" later in this program.

4.22: Transverse View: Papaya Model



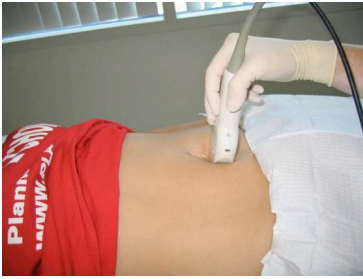Transverse cut: external view



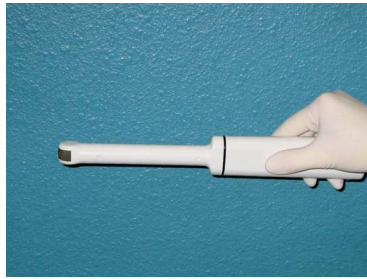
Transverse cut: internal view

The uterus is also commonly viewed with ultrasound in the transverse plane, when examining the contents of the fundal area, just as the papaya in these images has been cut across the large, round end.

4.23: Position of the Probe: Transverse



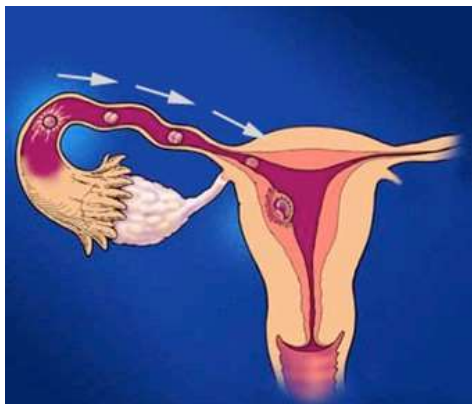Abdominal probe, transverse position



Transvaginal probe, transverse position

When the button or marker is rotated to the 9 o'clock position (toward the patient's right), a transverse view is seen. In the image seen on the ultrasound machine, the patient's right will be towards your left, as if you were looking at the patient from her feet.

5.1: Pregnancy Dating Terminology

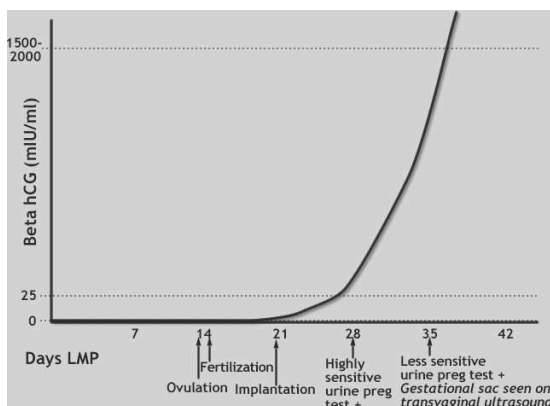


In this course, we will date the pregnancy from the first day of the last menstrual period (LMP). This is called menstrual dating. Menstrual dating is the standard for clinical care, but many embryology textbooks state the age of the pregnancy from conception. Ovulation occurs 14 days before the next menses would begin. For a woman with regular monthly menses, this means that ovulation occurs between days 13 and 17 of the menstrual cycle. Conception must occur within 24 hours of ovulation. Implantation occurs when the fertilized egg burrows into the lining of the uterus.

The process of implantation begins 6-9 days after ovulation. Once implantation is complete one week later, the pregnancy is entirely embedded within the lining of the endometrium.

When implantation begins, the early pregnancy tissue begins to secrete chorionic gonadotropin into the maternal blood. This hormone is commonly known as "hCG." hCG can be detected in blood or urine. Because only the beta-subunit of hCG differs from LH, the test for hCG levels is often referred to as a "beta-hCG" level.

5.2: Pregnancy Testing



This graphic shows an example of how hCG levels rise during the first seven weeks LMP.

Sensitive urine pregnancy tests measure hCG as low as 25 mIU/ml. The sensitive urine pregnancy test turns positive in nearly all women by the time of the first missed menses.

In normal intrauterine pregnancy, hCG levels increase very rapidly and usually at a predictable rate. At the time of the first missed menses, or four weeks LMP, hCG levels double every 1.5 to 2 days. By 8 weeks LMP, hCG levels double every 2 to 3 days.

Once the serum hCG reaches 2000 mIU/ml, the gestational sac is large enough that it should be seen in the uterus with transvaginal ultrasound. With transabdominal ultrasound, the gestational sac should be seen once the serum hCG reaches 5000 mIU/ml.

5.3: Physical Signs of Early Pregnancy

Bimanual exam can estimate gestational age.

The following conditions may make estimation of gestational age difficult:

- Obesity
- Retroverted uterus
- Multiple gestation
- Uterine fibroids

Experienced examiners can estimate gestational age by performing a bimanual pelvic examination, based on the fact that the uterus enlarges about 1 centimeter per week after four weeks. However, bimanual exam may be difficult and results may be misleading if the woman is obese, or has a retroverted uterus, multiple gestation or fibroids.

5.4: Gestational Age and Ultrasound

Time since start of last menses	Transabdominal Ultrasound Findings				Transvaginal Ultrasound Findings			
	Gest. Sac	Yolk Sac	Embryo	Cardiac Motion	Gest. Sac	Yolk Sac	Embryo	Cardiac Motion
3 weeks (21 to 27 days)	-	-	-	-	-	-	-	-
4 weeks (28 to 34 days)	-	-	-	-	+	±	-	-
5 weeks (35 to 41 days)	+	±	-	-	+	+	-	-
6 weeks (42 to 48 days)	+	+	±	-	+	+	+	±
7 weeks (49 to 55 days)	+	+	+	±	+	+	+	+

This table correlates ultrasound findings and length of pregnancy dated from LMP. The first indication of an intrauterine pregnancy, the gestational sac, can be seen with transvaginal ultrasound between 28-34 days LMP.

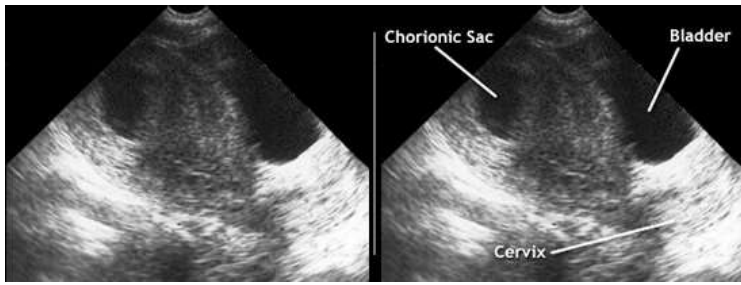
Transvaginal scanning will reveal the pregnancy structures several days to a week earlier than transabdominal scanning.

5.5: First Trimester Structures Used for Pregnancy Identification and Dating

Structures visible during the early first trimester:

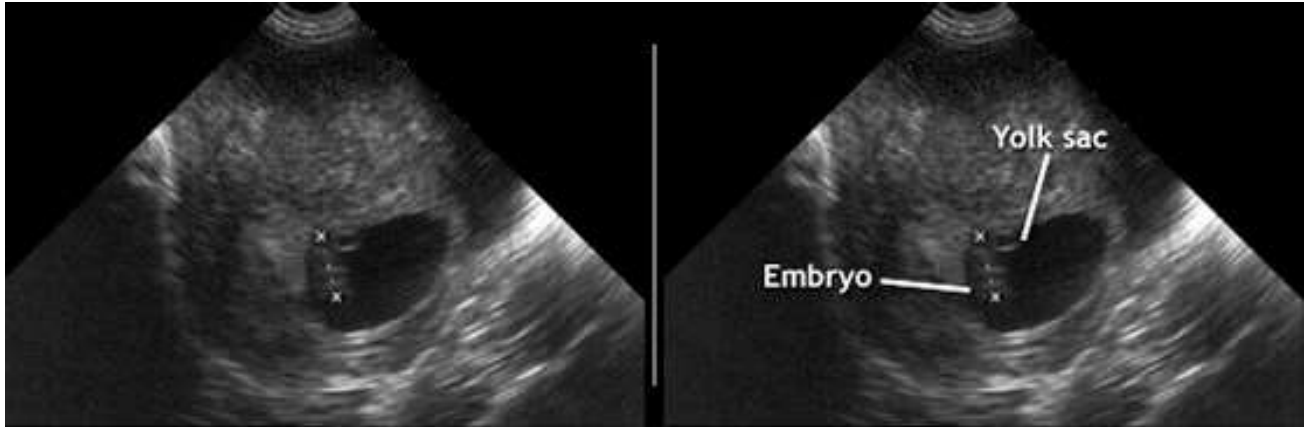
- Gestational sac first visible by 5 weeks LMP
- Yolk sac first visible at 5 1/2 weeks LMP
- Fetal pole first visible at 6 weeks LMP
- Embryonic cardiac activity visible at 6 1/2 weeks LMP

Early in the first trimester, the gestational sac, yolk sac and fetal pole are the sonographically identifiable structures that make it possible to confirm intrauterine pregnancy. The gestational sac and the fetal pole can be measured to date the pregnancy.



Transabdominal scan route

The gestational sac is first visible at 5 weeks. The yolk sac is visible by 5 1/2 weeks; the fetal pole by 6 weeks; and cardiac activity first appears at 6 1/2 weeks.

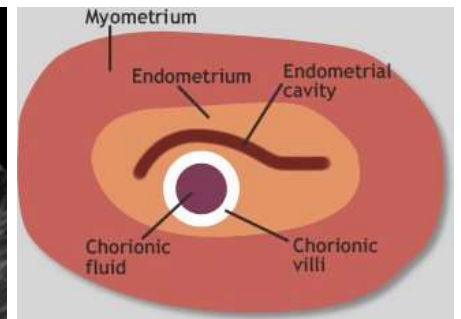
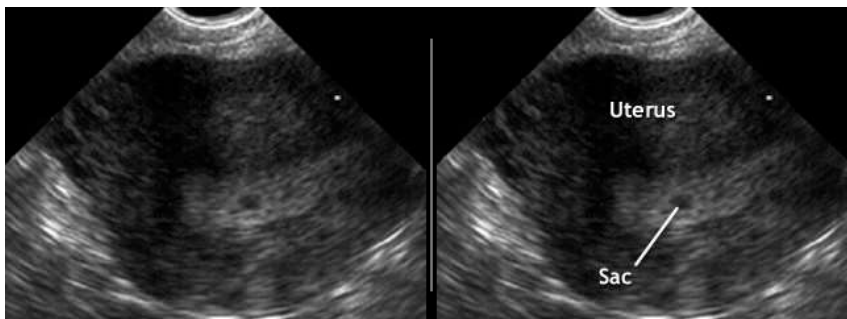


Transvaginal scan route

5.6: The Gestational Sac



Early gestational sac

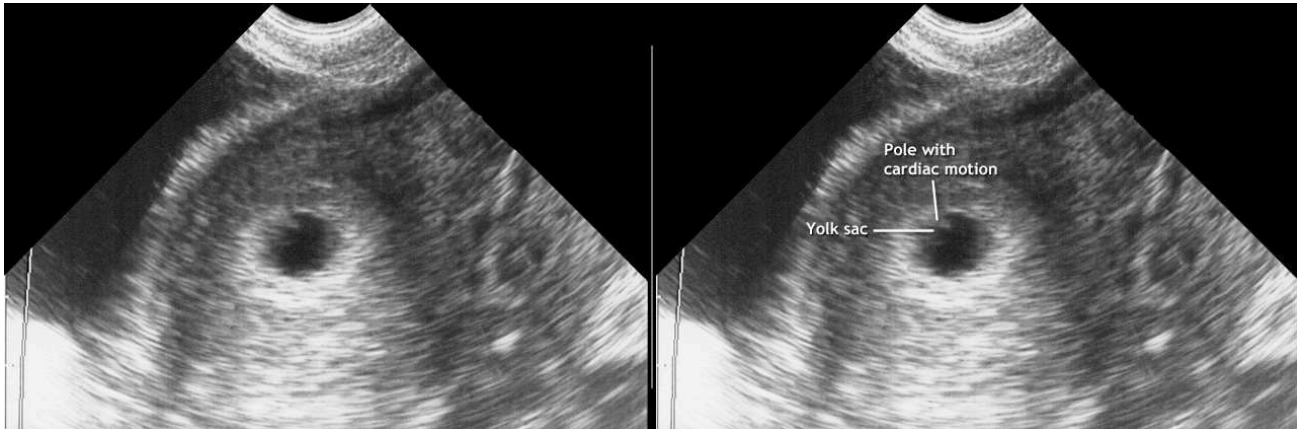


Transverse

The first structure visible on ultrasound is the gestational sac, or chorionic sac. The sac is first visible by 5 weeks LMP. A normal gestational sac will appear as a round, sonolucent structure, surrounded by an echogenic ring located in the fundal part of the uterus. The dark sonolucent fluid within the gestational sac is chorionic fluid. The bright echogenic ring that surrounds the sac is the chorionic villi.

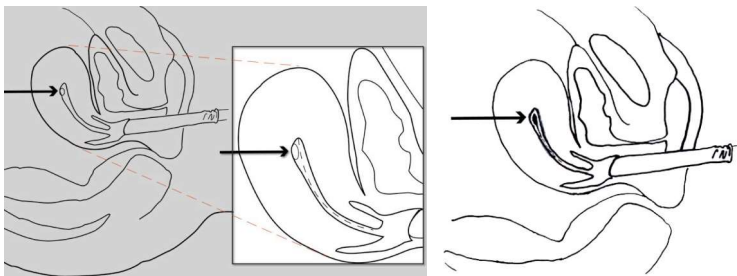
The diagram displayed here shows a very early pregnancy side-by-side with a magnified sonogram of a uterus containing a normal gestational sac at 5 weeks LMP marked by an arrow. Initially, no structures are visible within the chorionic fluid.

Gestational sac eight days later



The second image shows a sonogram taken eight days later from the same patient. The gestational sac grows 1 millimeter per day initially. In these images, the gestational sac had grown from 3 millimeters to 15 millimeters and a yolk sac and fetal pole with cardiac motion had appeared.

5.7: Eccentric Implantation of the Gestational Sac



Eccentric implantation

Pseudosac

When a fertilized egg implants into the thickened endometrium, it doesn't float in the uterine cavity; it burrows into the thick secretory endometrium. Consequently, it is off-center or eccentrically placed within the endometrial cavity.

The uterine cavity is the potential space between the endometrium lining of the interior of the uterus. It can be seen

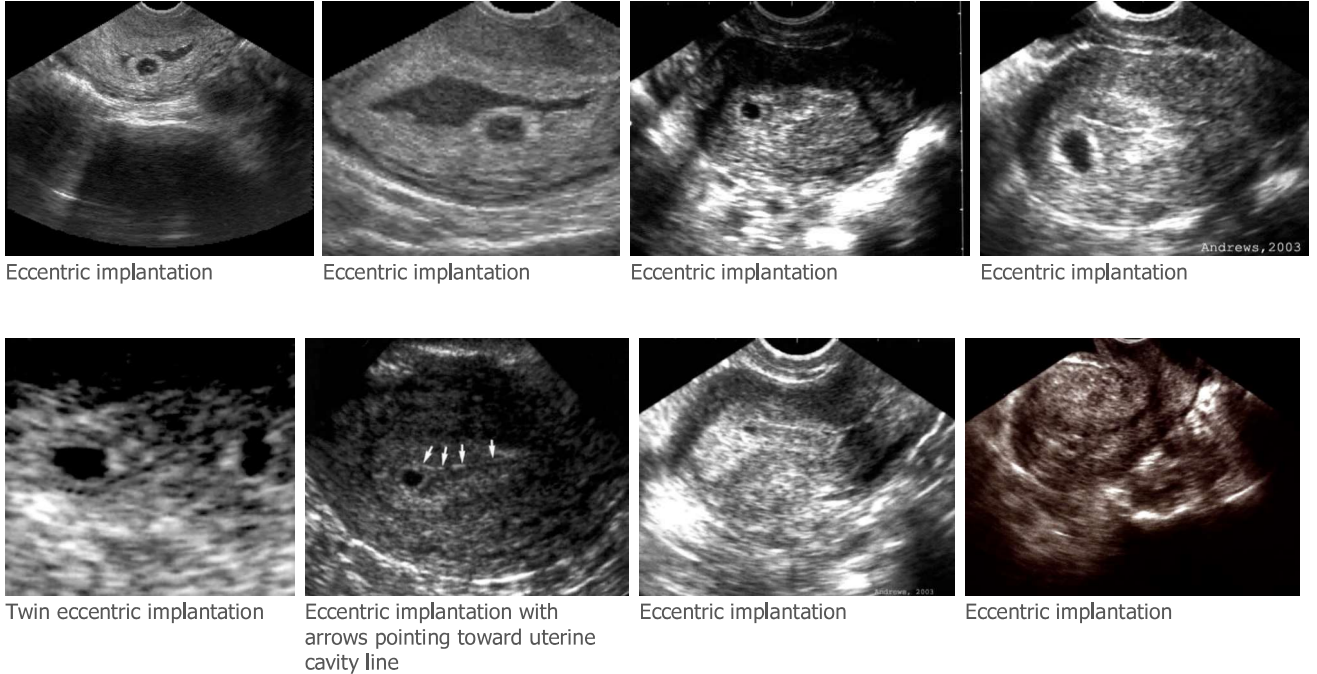
sonographically and travels down the middle of the uterus from the cervix, between the layers of the endometrium, to the fundus.

The first of these three diagrams represents the normal eccentric implantation of an early pregnancy. The pregnancy implants along a wall of the endometrium, not in the center of the endometrial cavity. The dotted line in the middle image represents the uterine cavity.

In contrast, the diagram on the right represents a pseudosac. A pseudosac is a collection of fluid in the uterine cavity- it is not a true gestational sac. It is not implanted in the wall of the endometrium but instead is seen in the midline of the cavity.

5.8: Eccentric Implantation Images

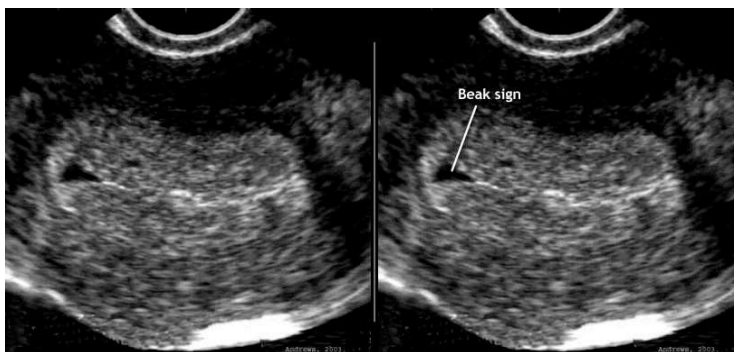
Image gallery



These ultrasound images show the eccentric implantation of early gestational sacs.

In the first two images, there is blood within the endometrial cavity. This blood makes the relationship between the gestational sac and the endometrial cavity more readily apparent. The eccentric implantation of the sac is visible. Although the endometrium is very thin, it completely covers the gestational sac.

Beak sign

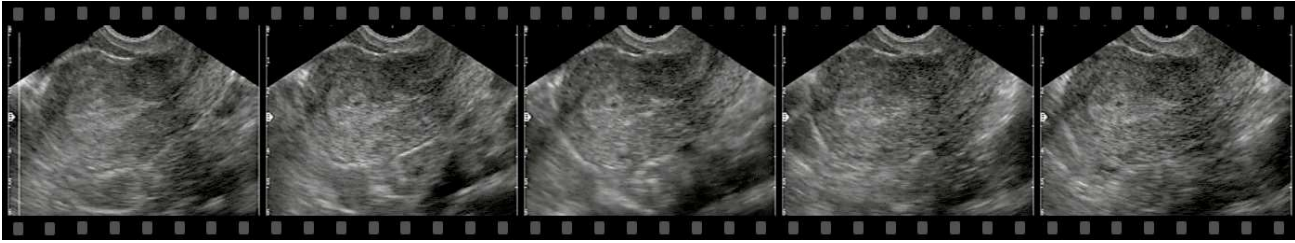

Beak sign

In contrast to the normal eccentric implantation, this image shows an intrauterine fluid collection that connects with or points toward the uterine cavity line. This is known as the "beak sign." It is mid-line in the uterine cavity. This is highly suggestive of a fluid collection or of a pseudogestational sac associated with an ectopic pregnancy. Also visible in this image is a small cyst within the endometrium. This is a common finding in very thick secretory endometrium which can be confused

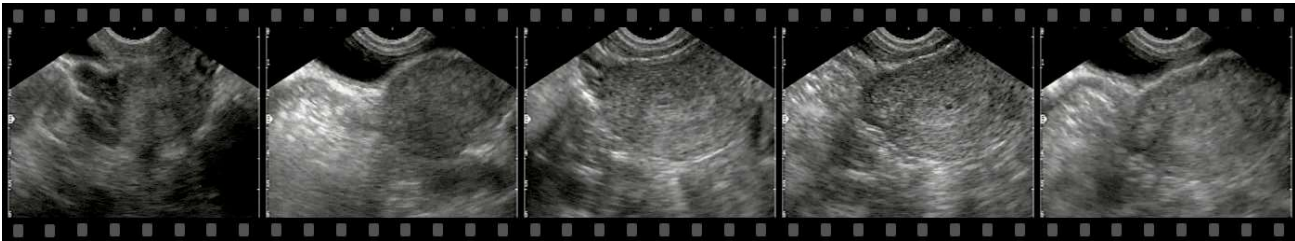with a very early gestational sac.

Video frames: case #1



Normal eccentric implantation - longitudinal view

These video frames show a normally implanted very early gestational sac.



Normal eccentric implantation - transverse view

5.9: Characteristics of the Normal Gestational Sac



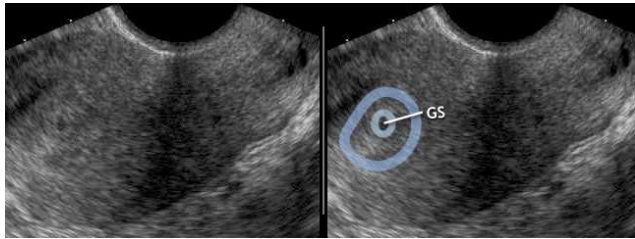Characteristics of a normal very early gestational sac:

- Surrounded by a thick, multi-layered choriodecidual reaction
- Round or oval in all views
- Off-center to the midline
- Located in mid- to upper uterus

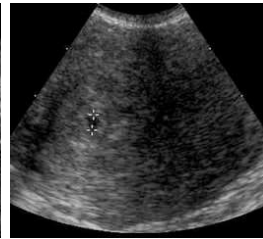
In review, it's important to do a systematic scan to view the gestational sac in both the longitudinal and transverse planes to be sure that the sac meets all the characteristics of an intrauterine gestational sac:

- It is surrounded by a thick, multi-layered choriodecidual reaction
- It is round or oval in all views
- It is off-center to the midline
- It is located in the mid- to upper uterus

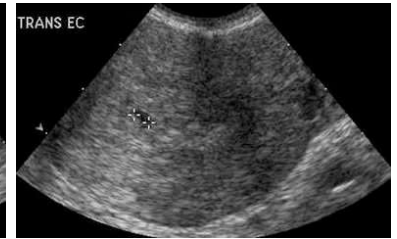
5.10: Double Decidual Sac Sign



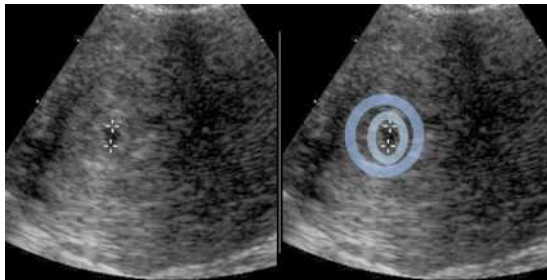
Double decidual sac



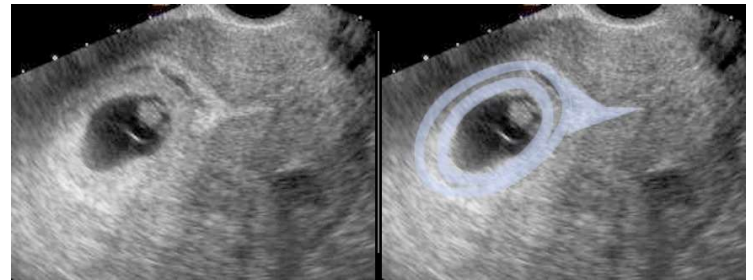
Early gestational sac showing the double decidual sac sign



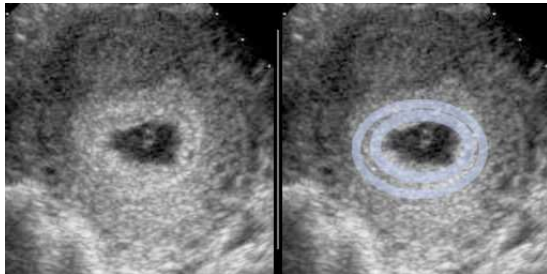
Early gestational sac showing the double decidual sac sign



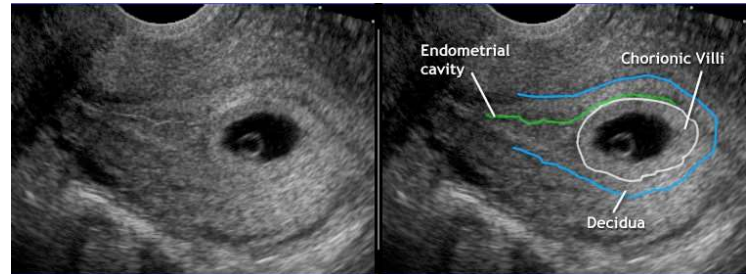
Double decidual sac sign



Double decidual sac sign



Double decidual sac sign



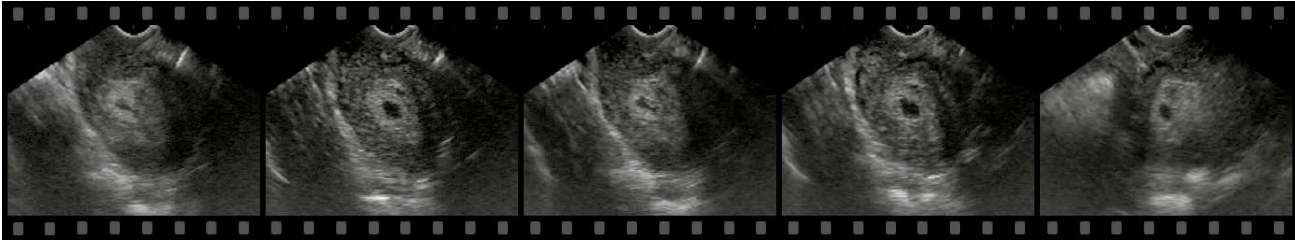
Double decidual sac sign

The normal gestational sac should be surrounded by two echogenic (white) rings with a distinct separation between the two rings. This is commonly called the Double Decidual Sign, and is also referred to as the chorio-decidual reaction. The inner ring is the chorionic tissue with some of the surrounding decidua where the sac has implanted. The outer ring is the thickened decidua of the opposing wall of the endometrium and may not form a complete ring as it will follow the contours of the uterine wall towards the cervix. The Double Decidual Sign only roughly corresponds to true anatomic layers. Once the gestational sac reaches 5 1/2 to 6 weeks, the "double decidual sign" becomes visible. These sonograms show early gestational sacs with double decidual signs.

5.11: Normal Gestational Sac Video Frames

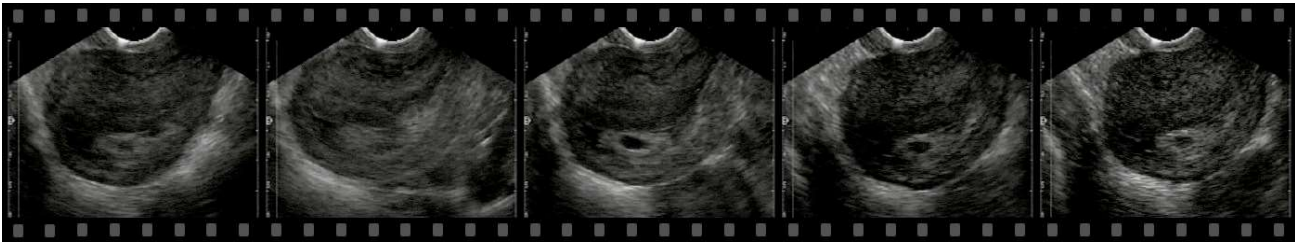These video frames show early pregnancies with all the characteristics that should be seen in normal gestational sacs.

Case 1



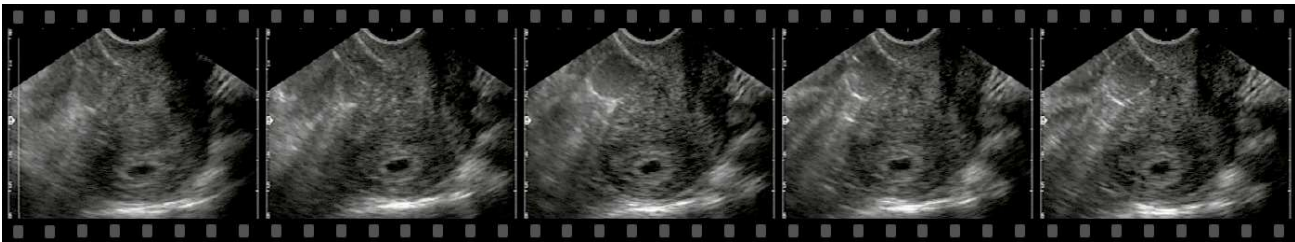Double decidual sac - case #1

Case 2



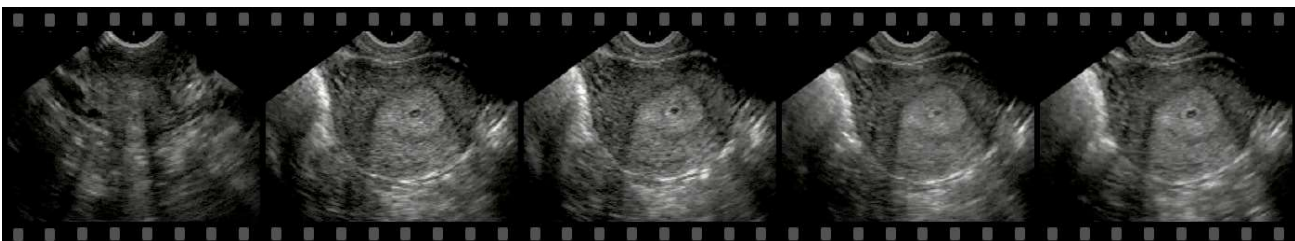
Double decidual sac - case #2

Case 3



Double decidual sac - case #3

Case 4



Double decidual sac - case #4

5.12: What Confirms Intrauterine Pregnancy?

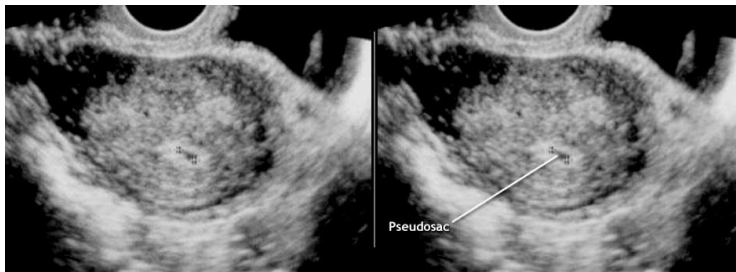
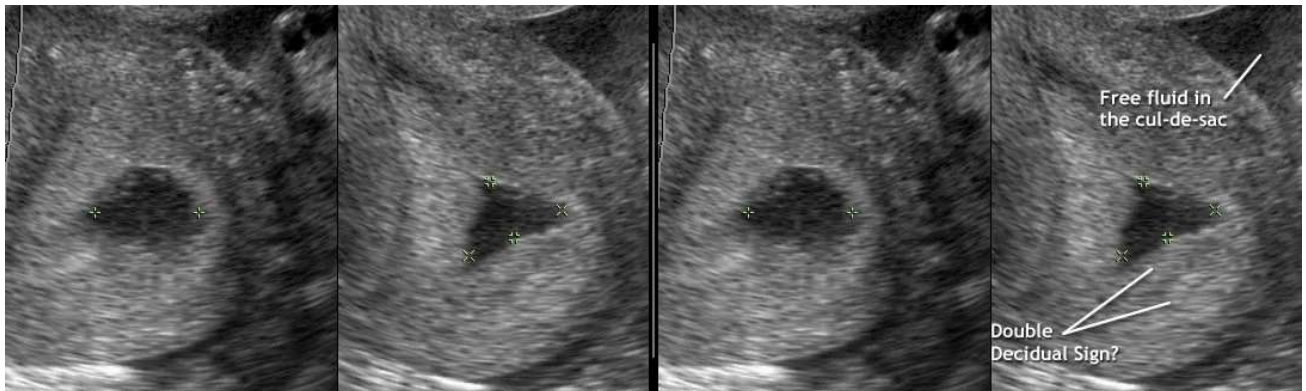
What confirms that a pregnancy is intrauterine?

- An intrauterine gestational sac containing a yolk sac or embryo

A very early gestational sac that contains no embryonic structures may be indistinguishable from a small intrauterine collection of blood or fluid called a "pseudosac." Pseudosacs are seen in approximately 20 percent of ectopic pregnancies. Therefore, a gestational sac without embryonic structures does NOT provide conclusive evidence of an intrauterine pregnancy. Visualization of a structure of embryonic origin -- the yolk sac -- or of the embryo itself within the uterus confirms that the pregnancy is intrauterine and not ectopic. The other possible diagnostic pitfall is "heterotopic pregnancy", or simultaneous intrauterine and ectopic pregnancy. Fortunately, this condition is

very rare unless assisted fertility treatments were used.

5.13: True Gestational Sac Versus Pseudosac

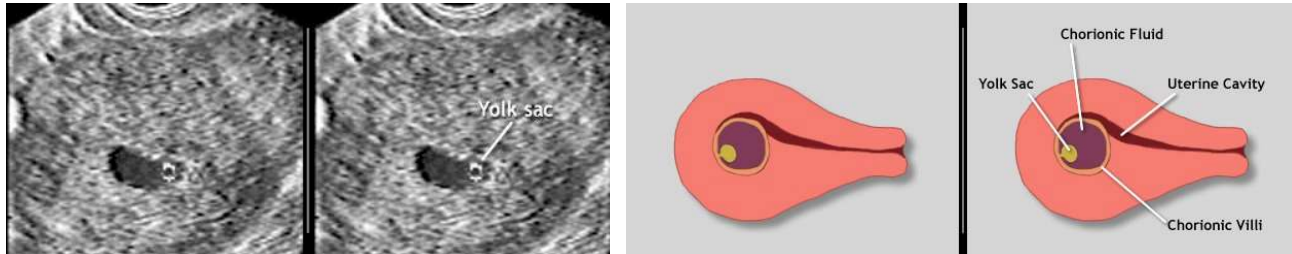


The image on the left shows a pseudosac. If this were mistakenly thought to be a gestational sac, diagnosis of ectopic pregnancy could be delayed, and possible rupture of the ectopic pregnancy could occur.

The above sonogram shows a large fluid collection within the uterus. It seems slightly off center, and something similar to the double decidual sign is visible around the fundal (lower right) portion of the sac. However, the sac is irregular and the "beak sign" is present. Importantly, no embryonic structures are present. Whether you feel that this is or is not an intrauterine gestation, it is important to realize that you cannot be sure. The clue to the diagnosis is the fluid outside the uterus in the cul-de-sac (in the top right of the image). This woman had an ectopic pregnancy. The small sac seen in the image in the bottom row is not round, and it is mid-line in the uterine cavity. Although it has a single thick echogenic rim, it is not a double decidual sign. Most importantly, no embryonic structures are visible. Therefore, it is not possible to conclude that this sac is a gestational sac. In fact, this was a pseudosac; the woman had an ectopic pregnancy.

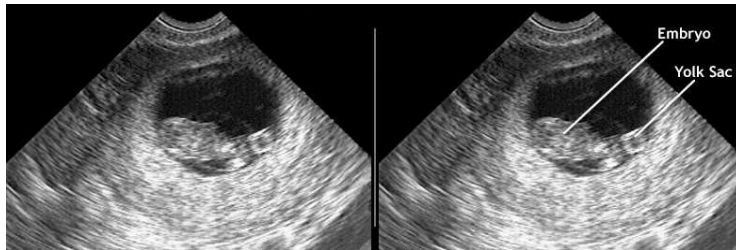
5.14: Growth of the Gestational Sac and Appearance of the Yolk Sac

Growth of gestational sac



The gestational sac grows rapidly, at the rate of about 1mm per day in diameter. Between 5- 6 weeks LMP, the yolk sac becomes visible. Since the yolk sac is of embryonic origin, its appearance inside the uterus provides conclusive evidence that an intrauterine pregnancy is present. The sonogram displayed here shows a 5 to 6 week intrauterine pregnancy with a yolk sac within the gestational sac; next to it is a diagram demonstrating the gestational sac and yolk sac.

Yolk sac



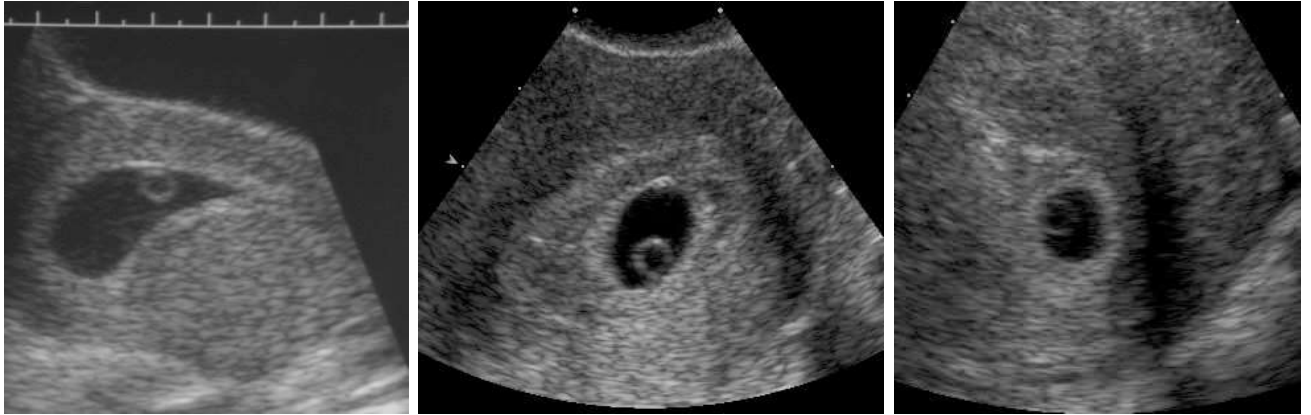The yolk sac is a spherical structure located inside the gestational sac. The yolk sac should be visible in a normal pregnancy once the mean diameter of the gestational sac is 13 mm. Occasionally, the yolk stalk may be seen connecting the yolk sac to the embryo, this is a normal finding. The yolk sac is usually visible until about 10 weeks of

pregnancy.

Because the yolk sac is embryonic tissue, its appearance within the gestational sac confirms an intrauterine pregnancy, assuming of course that the gestational sac is within the uterus.

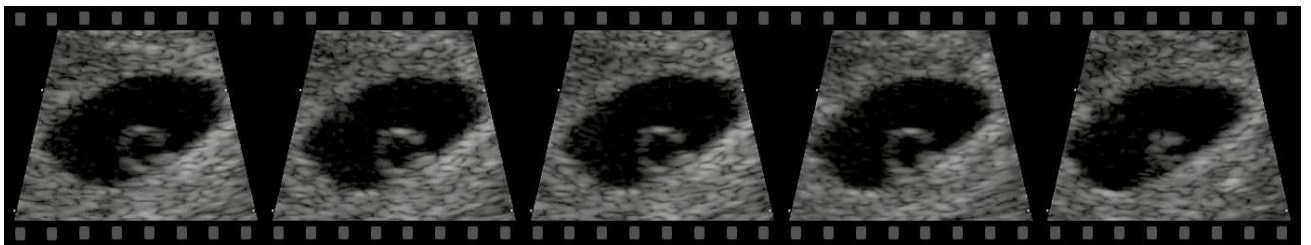
5.15: Appearance of the Yolk Sac

Images

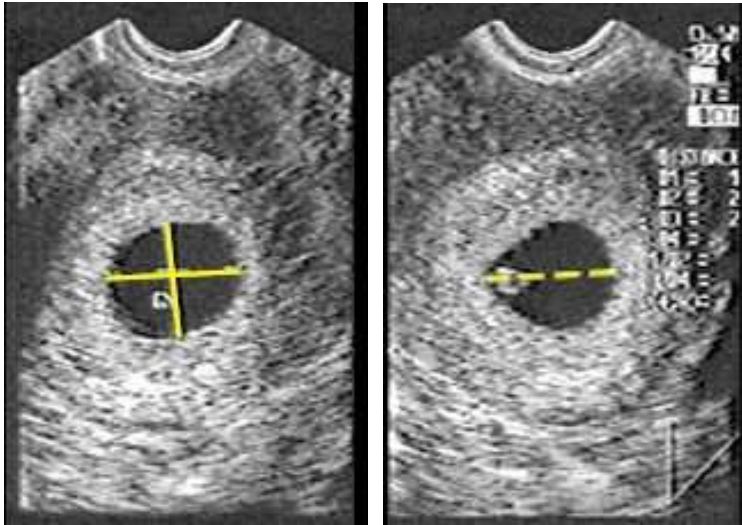


These images and the video frames that follow show the early appearance of the yolk sac. You should also be able to identify the double decidual sign in these images.

Video frames



5.16: Measuring the Gestational (Chorionic) Sac

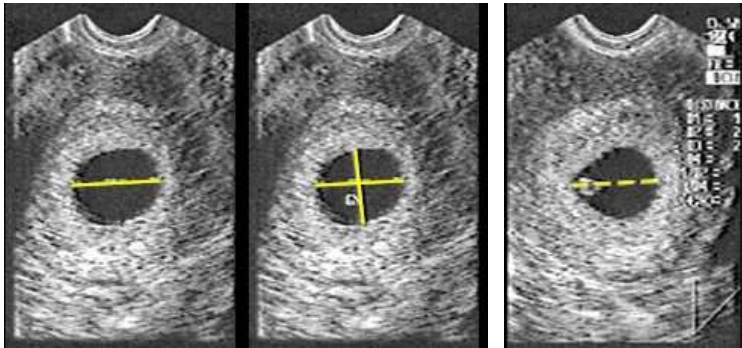


Longitudinal

Transverse

The chorionic sac is measured in three dimensions using electronic calipers. These three dimensions are length, width and height. This requires two views of the uterus at right angles to one another. By convention the length and height of the sac are measured on a longitudinal image and the width is measured on a transverse image. These images show two views of a chorionic sac being measured in 3 dimensions.

5.17: Animation of Measurements Being Taken



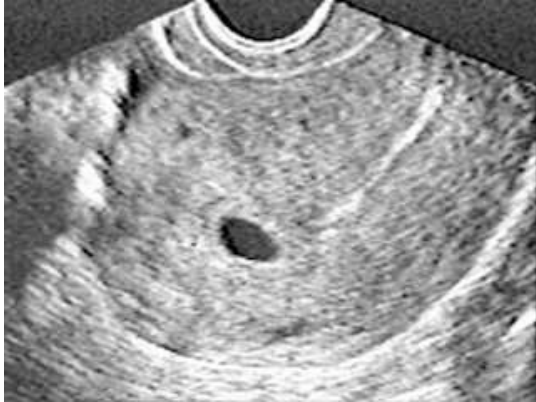Longitudinal

Transverse

A longitudinal view of the uterus is located, and frozen; then the sac is measured in length and height. Next, a transverse view is located and frozen; then the sac is measured in width.

5.18: Practice Measurements of the Gestational Sac

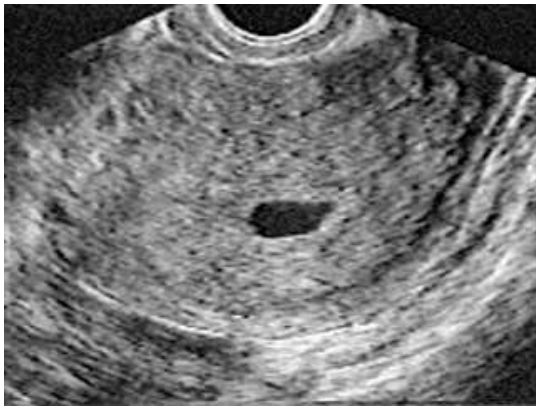
Longitudinal plane



Now practice making these measurements yourself on this set of two images. The first image is in the longitudinal plane; use it to measure the sac length and height. The second image is in the transverse plane; use it to measure the sac width.

The answer key is at the back of this workbook.

Transverse plane



5.19: Calculating Gest. Age from the Chorionic Sac

Formula for gestational age based on mean sac diameter:

$$\text{Mean sac diameter (MSD)} = \frac{(\text{length} + \text{width} + \text{height})}{3}$$

$$\text{Gestational age (days)} = \text{MSD (mm)} + 30$$

Margin of error: +/- 4 days

Gestational age may be calculated using the mean diameter of the gestational sac. The mean diameter is determined by adding the three measurements and dividing by three:

$$\text{MSD} = \frac{[(\text{length} + \text{height} + \text{width}) / 3]}$$

The resultant number in millimeters, when added to 30 equals the gestational age in days plus or minus about 4 days.

Gestational age should be calculated based on measuring the gestational sac when an embryonic pole is not yet visible. In the example you just

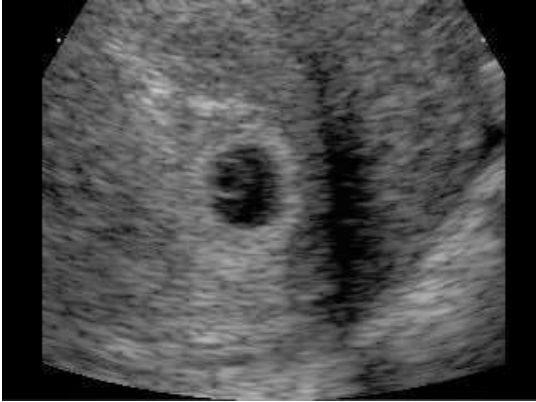
completed, the mean sac diameter (MSD) was 12 mm corresponding to a gestational age of 42 days plus or minus 4 days.

5.20: More Practice Measuring the Gestational Sac

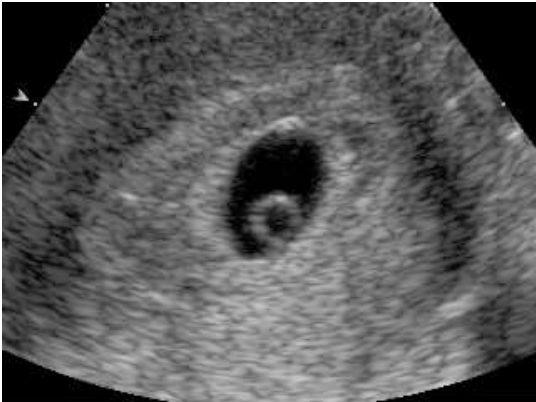


Practice measuring the length and width of the gestational sac in these cases. The answer key is at the back of the workbook.

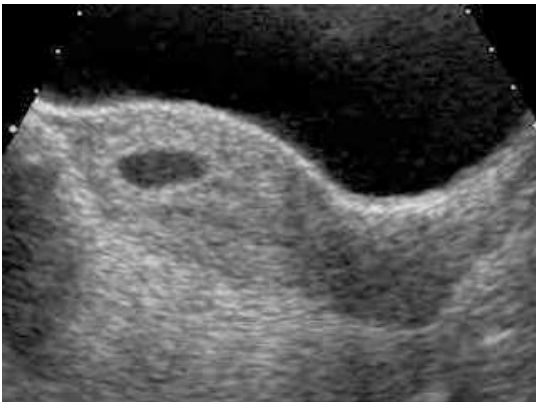
Case 1



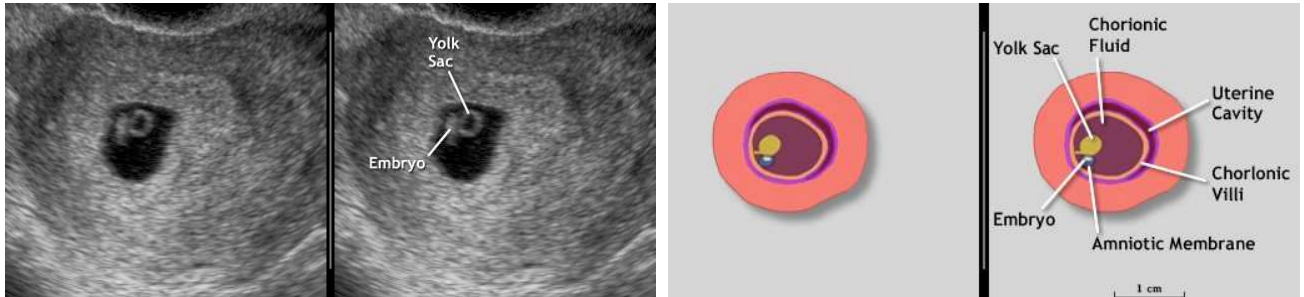
Case 2



Case 3

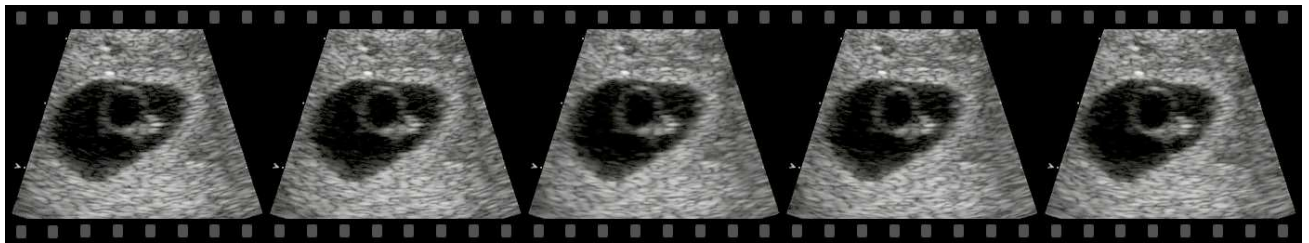

5.21: Identifying the Embryo

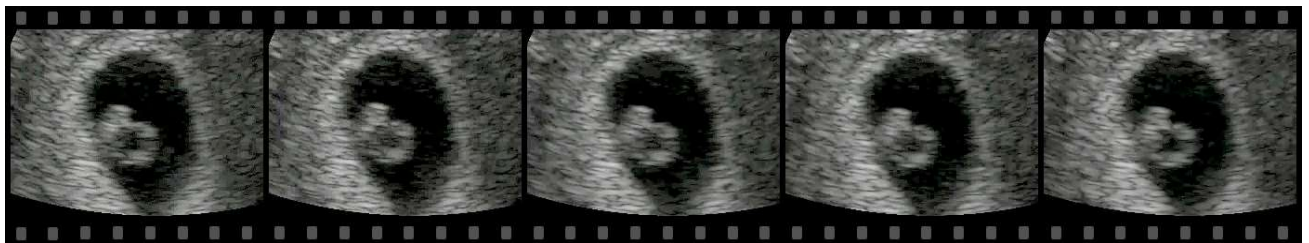

After 6 weeks, the embryo is first visible as a tiny speck in the gestational sac, usually close to the yolk sac. When first visible, it is only few millimeters in length and may be identifiable only during real-time scanning by visualization of the embryonic cardiac motion. This tiny early embryo is often called the "embryonic pole." The embryo is surrounded by the amniotic membrane but it is not visible until the embryo is larger.

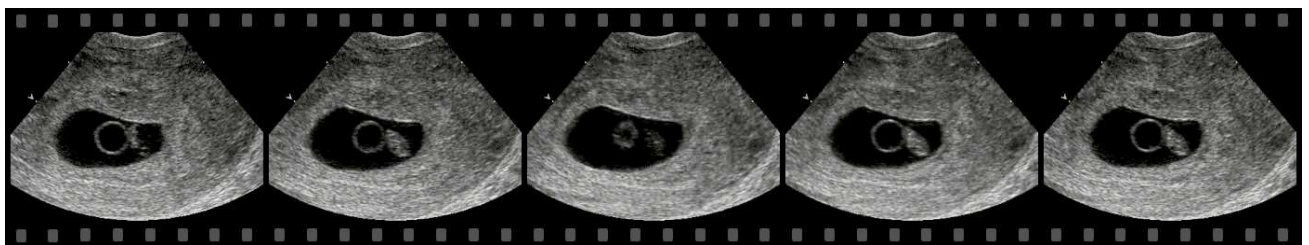5.22: Video Frames of Fetal Pole



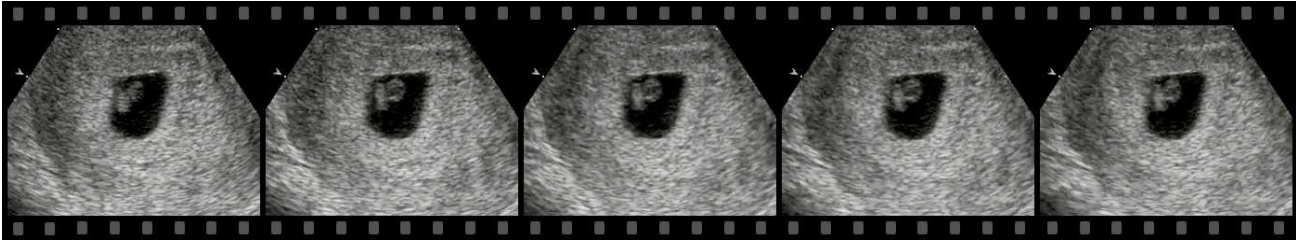These video frames show embryonic poles with embryonic cardiac motion. The embryonic cardiac motion can be seen in real time.



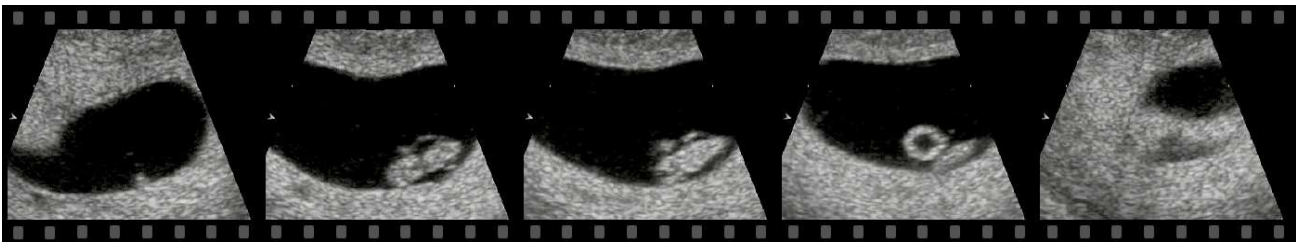5.23: The Embryo at 6 Weeks LMP



When the pregnancy reaches six and a half weeks LMP, cardiac motion is usually readily apparent. If the crown-rump length measures 5 mm or more and no cardiac motion is seen, then an embryonic demise is diagnosed. The embryo in the video frame on the right measures 3.5 mm.

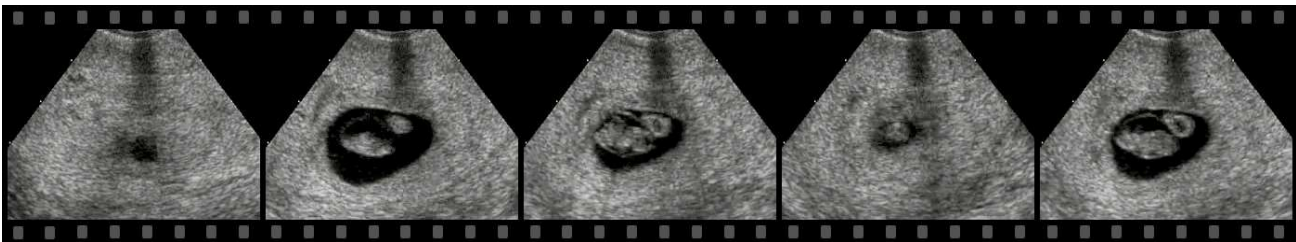

5.24: The Embryo at 7 Weeks LMP

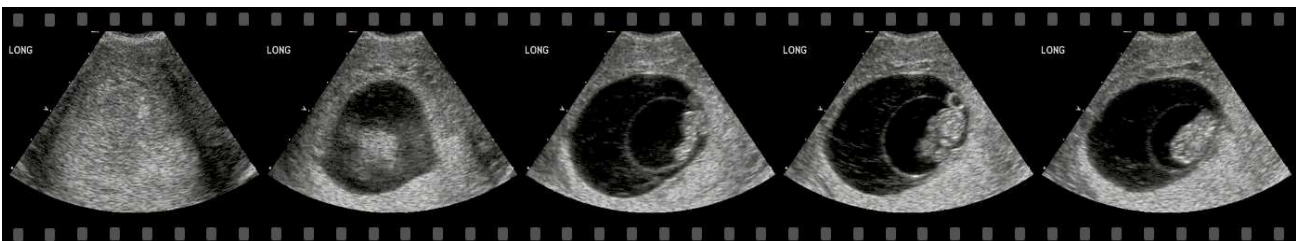


These video frames show the embryo at 7 weeks.

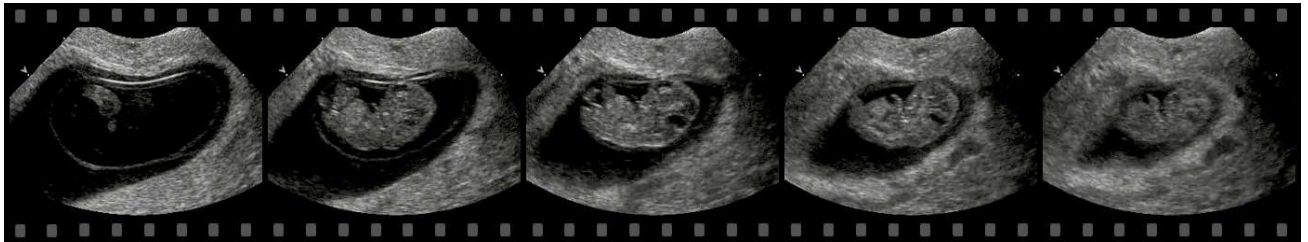5.25: The Embryo at 8 Weeks LMP



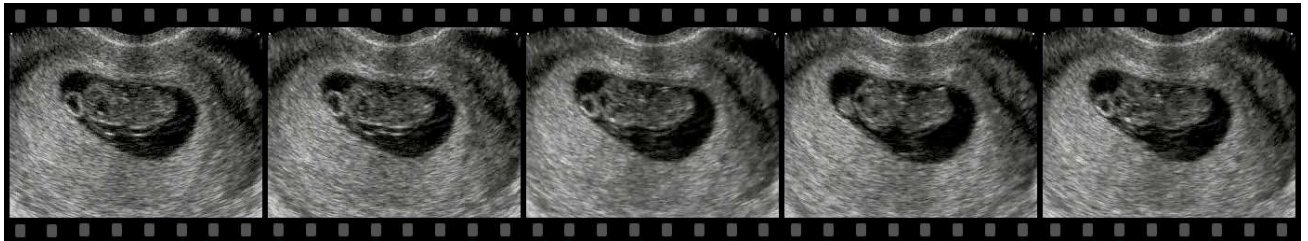These video frames show the embryo at 8 weeks LMP. The embryo is usually seen well by 8 weeks. The embryo should fill the amnion, as seen in these video frames.



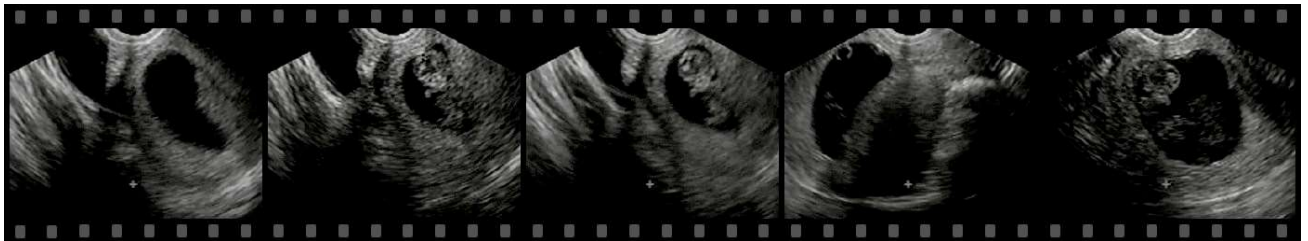5.26: The Embryo at 9 Weeks LMP



These video frames show the embryo at 9 weeks LMP. By this stage, body motion and limb buds with limb motion are commonly seen.

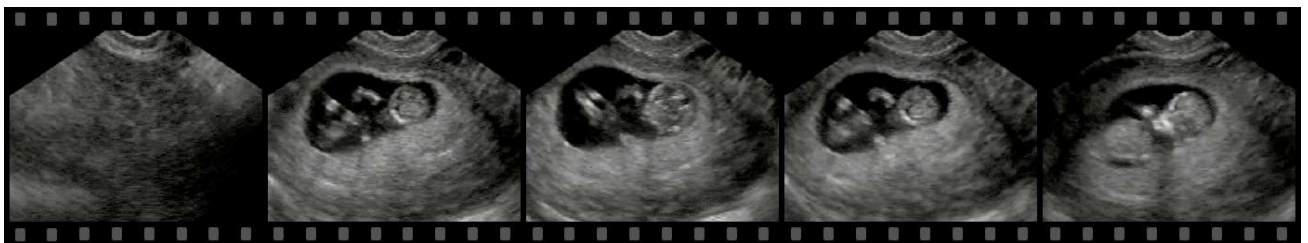

5.27: The Embryo at 10 Weeks LMP



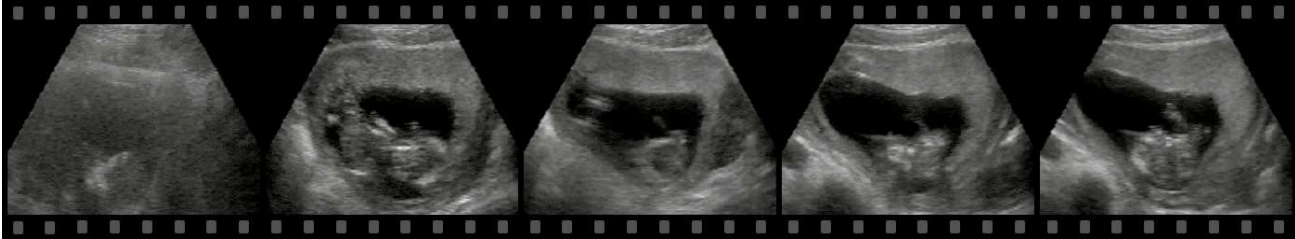These video frames show the embryo at 10 weeks LMP.

5.28: The Embryo at 11 Weeks LMP



These video frames show the embryo at 11 weeks LMP.

5.29: The Embryo at 12 Weeks LMP

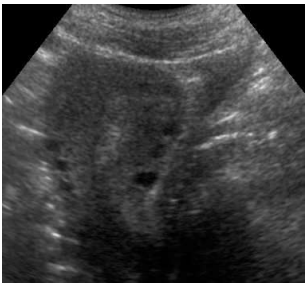


These video frames show the embryo at 12 weeks LMP.

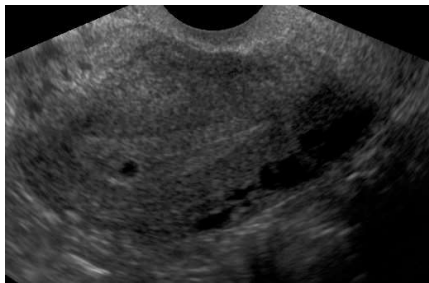5.30: Transvaginal Scanning Improves Diagnostic Ability

Particularly during the early weeks of the first trimester, transvaginal scanning improves diagnostic power as shown in these two cases comparing the two scan routes on the same patient.

Case 1



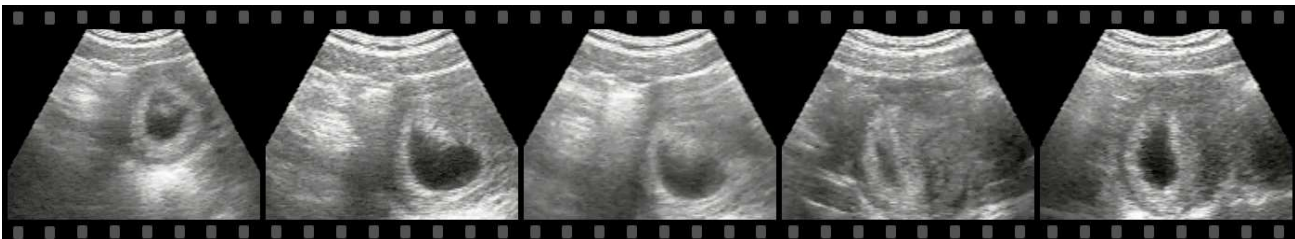Transabdominal scan



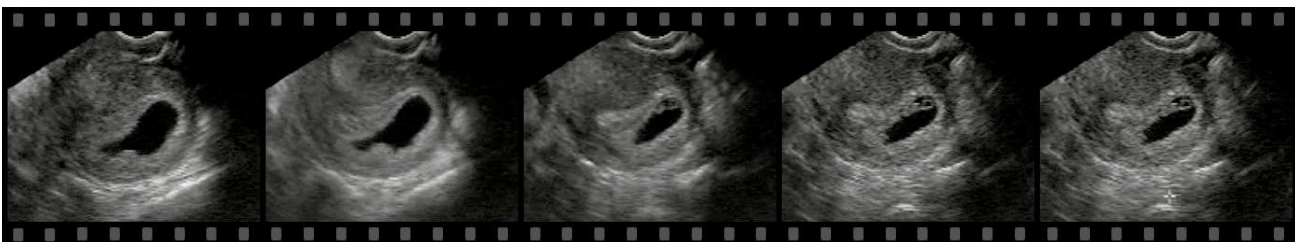Transvaginal scan

- Use the transvaginal probe to about 10 weeks gestation;
- Measure CRL with the abdominal probe up to about 13 weeks;
- At about 13 weeks and beyond, switch to head and femur measurements.

Case 2



6 weeks LMP: Transabdominal scan



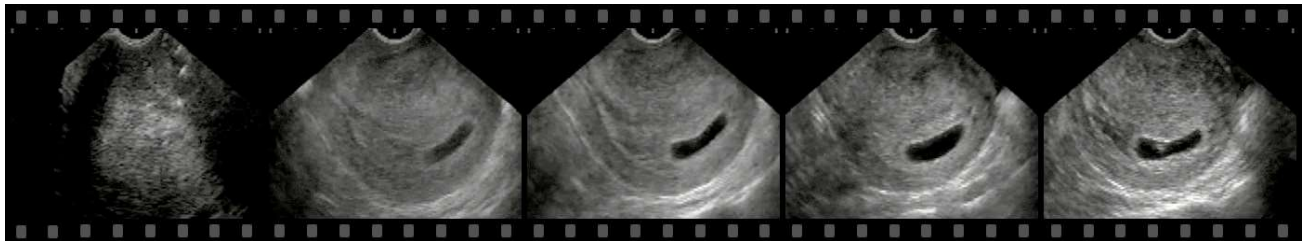6 weeks LMP: Transvaginal scan

5.31: Adjusting Frequency to Improve Diagnostic Power

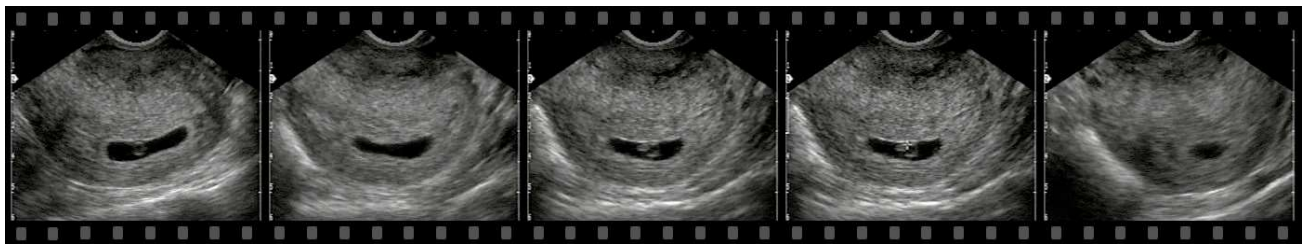Many transvaginal transducers have the capacity to choose between two or more frequencies, usually between 5 and 7.5 megahertz. Selecting the higher frequency can improve the resolution and therefore aid in making a sonographic diagnosis, particularly during the early weeks of the first trimester as shown in these two cases scanned at both 5 and 7.5 megahertz.

The 5 MHz setting may be useful in early pregnancy in imaging a uterus with fibroids or a mid-position uterus where it may be difficult to position the probe close to the pregnancy.

Case 1

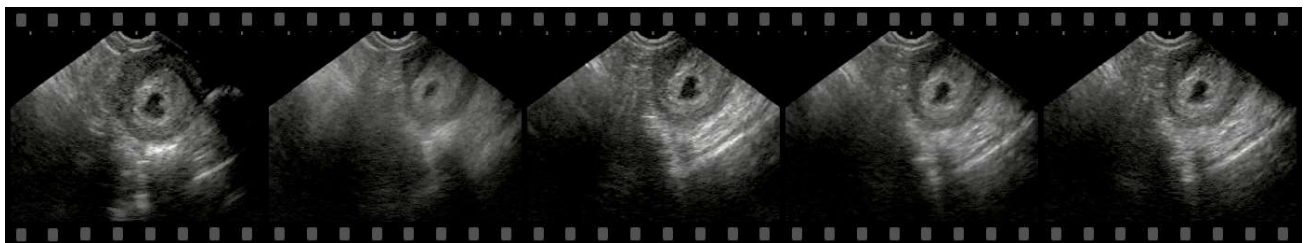


5 MHz

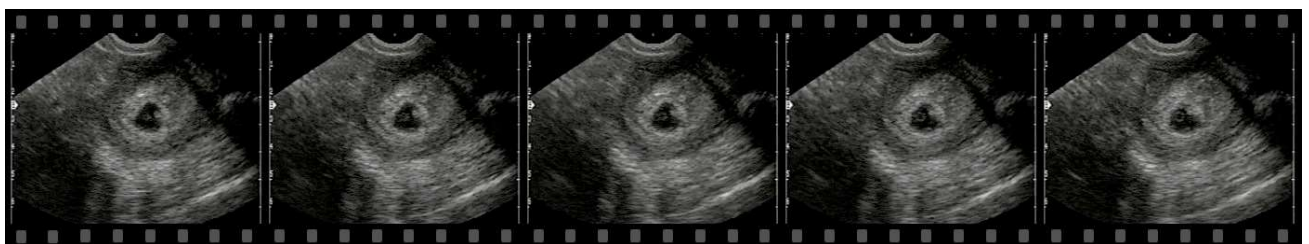

7.5 MHz

Case 2

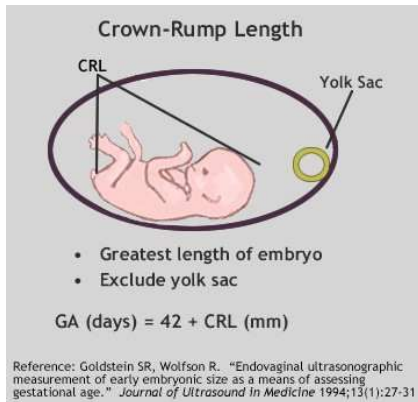


5 MHz



7.5 MHz

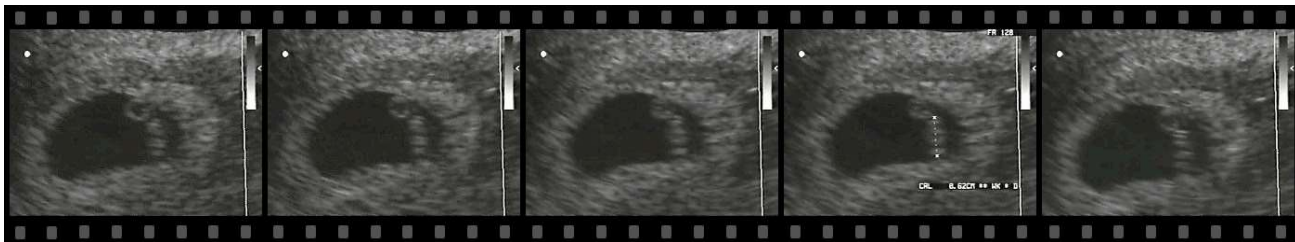5.32: Measuring the Embryo and Calculating Menstrual Age



The embryo is measured in longest dimension using electronic calipers. This is called the crown-rump length. The yolk sac must NOT be included in this measurement.

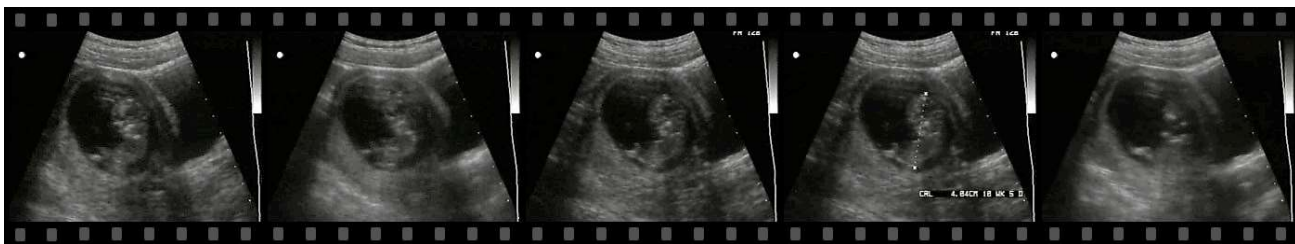The Goldstein Formula is used to calculate gestational age based on the crown-rump length. The gestational age in days is equal to 42 plus the crown-rump length in millimeters. Thus, an 8 week embryo should measure 14 mm. This formula was developed using transvaginal ultrasound and will give slightly different results from the software in most ultrasound machines. It is valid through 9 weeks gestation. After 9 weeks gestation, the Goldstein formula should no longer be used. The software package in most ultrasound machines will reliably calculate the gestational age.

5.33: Video Frames of Crown-Rump Length Being Measured



In these video frames, the embryo is located, and the image is frozen showing the longest possible crown-rump length, excluding the yolk sac. Then the embryo is measured.

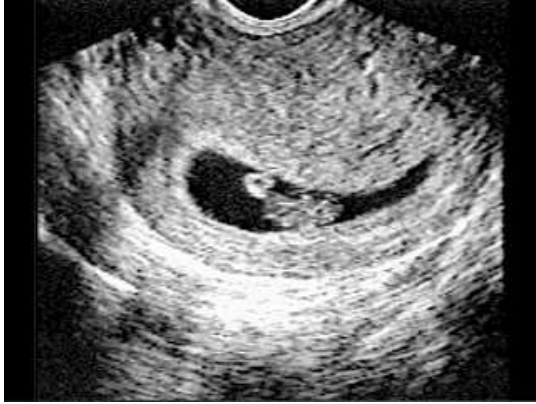In the top set of video frames, the embryo measures 6 mm. It is too small at this point for the ultrasound software package to calculate gestational age. By using the Goldstein formula, 42 is added to 6 to get a gestational age of 48 days or 6 weeks 6 days.



5.34: Practice Measurements of CRL

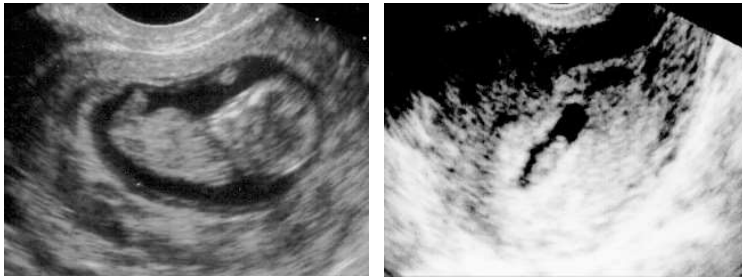
Practice measuring the crown-rump length of these embryos. The answer key is at the end of the workbook.

Case 1

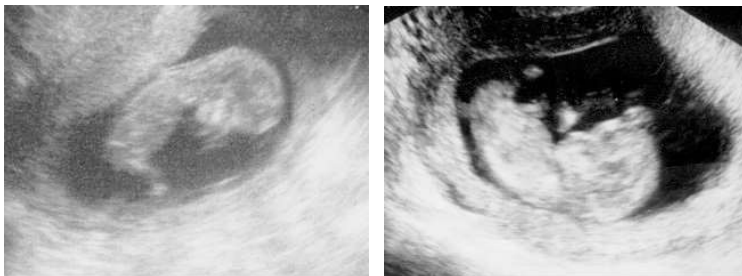


Be sure that you do NOT include the yolk sac in your measurement.

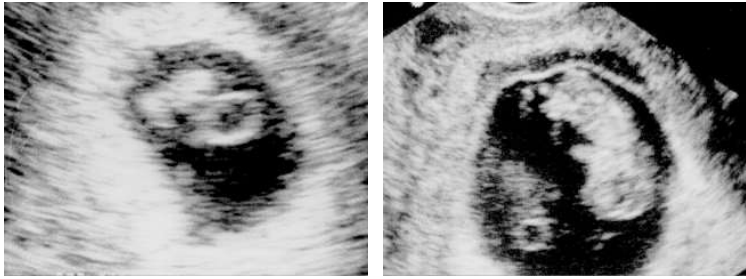
Case 2-3



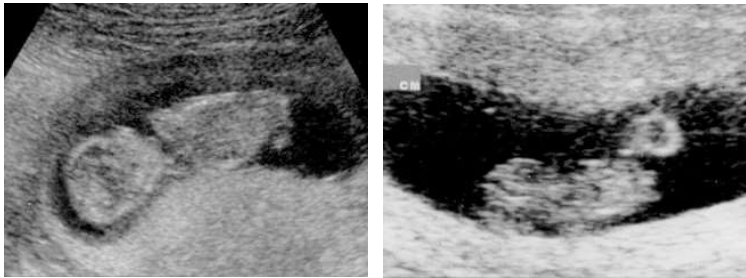
Case 4-5



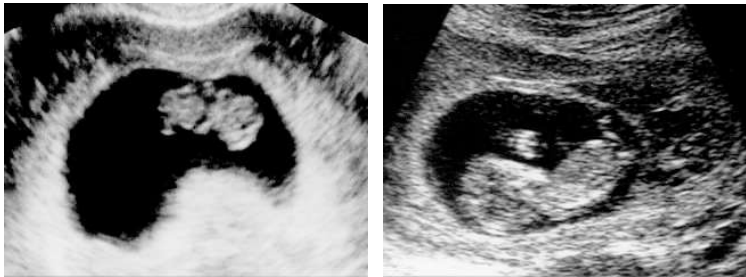
Case 6-7



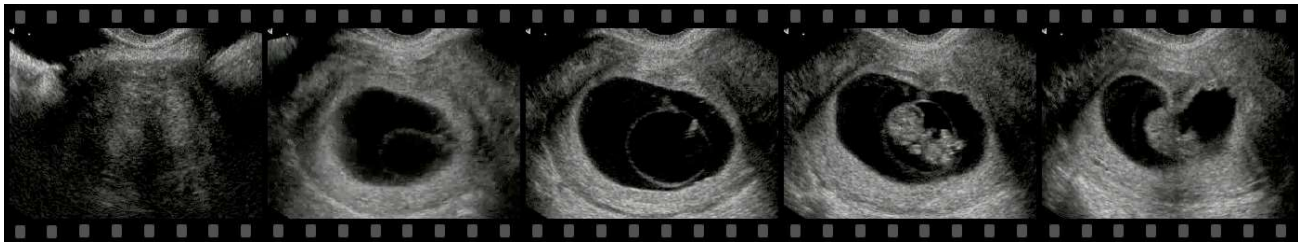
Case 8-9



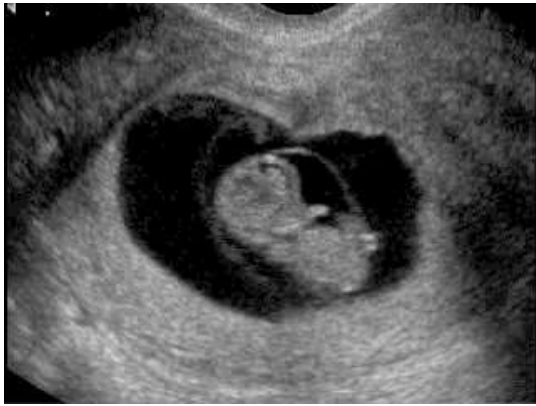Case 10-11



5.35: Practice selecting the appropriate frame for CRL Measurement



Choose the image in this set of video frames that is the appropriate image for measuring crown-rump length. The answer key is at the back of the workbook.



Practice measuring the crown-rump length on this image. The answer key is at the end of the workbook.

5.36: Review of the Systematic Scan



Systematic Scan

- Visualize the uterus
- Scan the uterus in longitudinal & transverse view
- Gestational sac
 - Look for as much detail as possible within the sac
 - Look for all the characteristics of a normal sac
- If an embryo is present, measure embryonic length
 - Do not include the yolk sac in the measurement

Since so much information was contained in this chapter, we'll review:

- First, visualize the uterus
- Then perform a systematic scan, looking at the uterus and its contents in the longitudinal and transverse view
- The first sonographic appearance of a pregnancy is the gestational sac
- Use the zoom, depth or megahertz settings to be sure as much detail as possible is seen within the gestational sac
- Look at all the characteristics of the sac to see if it appears to be a true sac, not a pseudosac:

1) it's round or oval in all views

2) it is surrounded by the double decidual sign

3) it's off-center to the midline

- If no embryo is seen, measure the gestational sac to determine gestational age

- Once the embryo is seen, measure the embryonic length, not the gestational sac, to calculate gestational age

- Do not include the yolk sac in the measurement

- The adnexal structures and cul-de-sac should also be scanned if clinically indicated.

5.37: Review of Beta hCG and Sonography Findings



Highly sensitive urine pregnancy test turns positive at 25 mIU/ml

Less sensitive pregnancy test turns positive at the discriminatory zone- 1500 to 2000 mIU/ml

If beta hCG is above the discriminatory zone but no pregnancy is seen in the uterus, ectopic pregnancy should be highly suspected.

The beta subunit of human chorionic gonadotropin (hCG) doubles every 1.5 to 2 days in early pregnancy.

By the time of the first missed period, a pregnancy test is almost always positive. The sensitive urine pregnancy tests turn positive at 25 mIU/ml of beta hCG.

By the time the beta hCG is 2000 mIU/ml, the gestational sac should be visible with transvaginal ultrasound. This is called the discriminatory zone. There are commercial urine pregnancy tests that turn positive at 1500-2000 mIU/ml.

Any patient whose highly sensitive pregnancy test is positive but who has an empty uterus with transvaginal ultrasound should be carefully evaluated. The possibilities are that the patient:

- 1) is pregnant, but it is too early for the pregnancy to be seen in the uterus with transvaginal ultrasound; it is too early to confirm the location of the pregnancy
- 2) has an ectopic pregnancy
- 3) is experiencing a pregnancy loss, i.e, failing intrauterine pregnancy or miscarriage

At this point, it should be determined if beta hCG is above the discriminatory zone, either by a less sensitive pregnancy test in the health center or a quantitative beta hCG sent to the reference lab or both. If the beta hCG is below 1500 mIU/ml, the patient is asymptomatic and her menstrual dates indicate that she is less than 5 weeks pregnant, the location of the pregnancy still can't be confirmed but the likelihood is that it's an intrauterine pregnancy too early to visualize.

If the beta hCG is above the discriminatory zone and no pregnancy is seen within the uterus, whether or not a mass is seen in the adnexa, it should be assumed that the pregnancy is ectopic until proven otherwise.

6.1: Range of Diagnoses

- Early pregnancy failure
 - Anembryonic pregnancy
 - Embryonic demise
- Spontaneous abortion
- Hydatidiform mole
- Uterine anomalies, particularly bicornuate uterus
- Uterine fibroids
- Multifetal pregnancy
- Pregnancy in uterine cesarean scar

A variety of abnormal first trimester conditions and variations are visible with sonography. These include early pregnancy failure, spontaneous abortion, hydatidiform mole, uterine anomalies (particularly bicornuate uterus), uterine fibroids, multi-fetal pregnancy, and pregnancy implanted in a uterine cesarean scar. These conditions will be discussed and illustrated in the lessons that follow. The first entity, anembryonic pregnancy, is one of the most common and is sometimes called "blighted ovum" or "missed abortion", although those older terms should no longer be used.

6.2: Anembryonic Gestation

Diagnostic criteria for anembryonic gestation:

- No yolk sac with a mean sac diameter of >13 mm
- No embryo with a mean sac diameter of >16 mm

Other findings with an anembryonic pregnancy:

- The gestational sac is irregularly shaped
- The gestational sac is not in the fundus
- The gestational sac is not surrounded by an echogenic ring (the inner ring of the double decidual sign)

If transvaginal scanning is performed, a yolk sac is usually seen within the gestational sac when the sac mean diameter is 8mm, at approximately 5 1/2 weeks gestation. The pregnancy is anembryonic if a yolk sac is not seen once the mean sac diameter is more than 13mm. A variety of older terms have been used to describe an anembryonic gestation, such as blighted ovum and missed abortion.

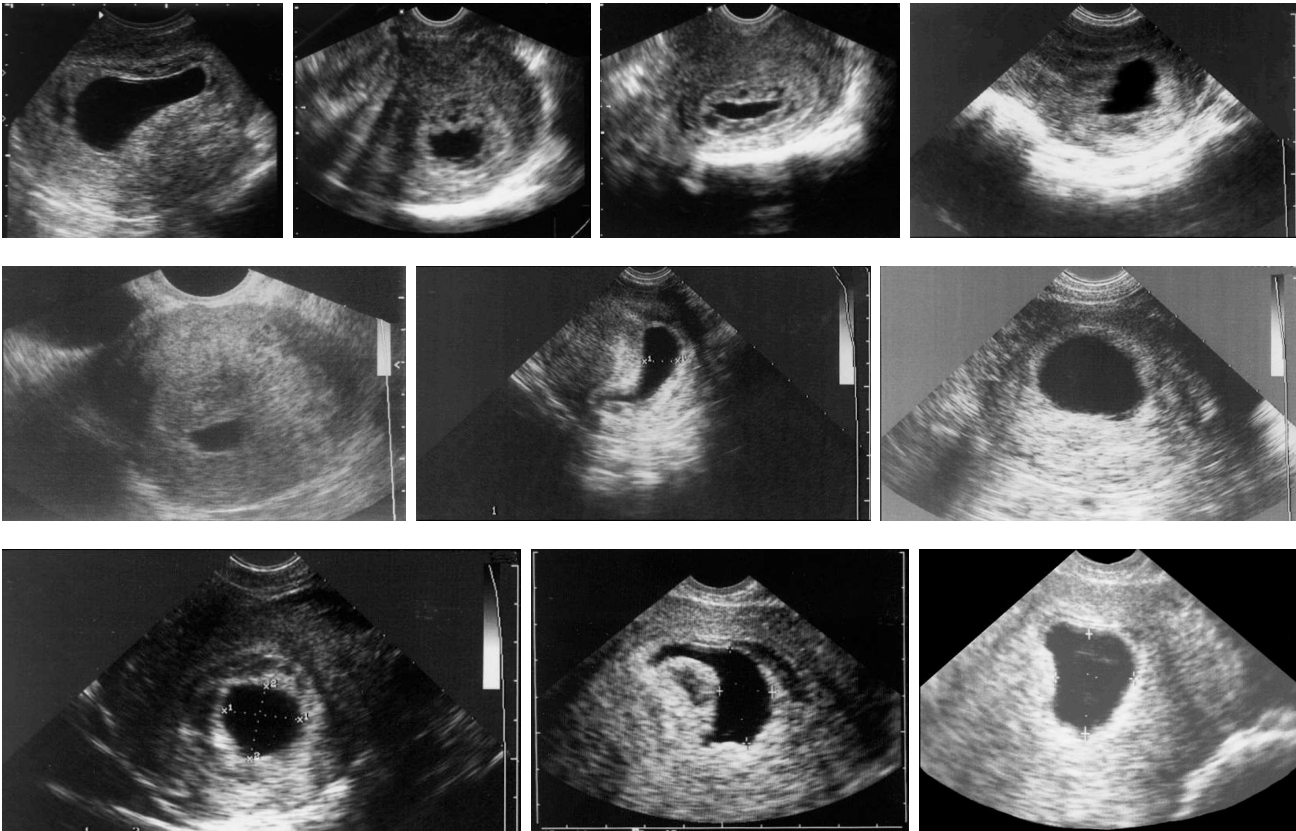
Abnormal gestational sacs are frequently irregular in shape, are not located in the fundal area of the uterus, and do not have a normal surrounding, bright, echogenic rind of healthy chorionic villi.

Caution must be taken as the pseudosac that accompanies an ectopic pregnancy has the same

triad of findings: lack of a yolk sac, irregular shape, and absence of the double decidual sign. When the gestational sac mean diameter is 16mm or more, an embryo should always be identifiable.

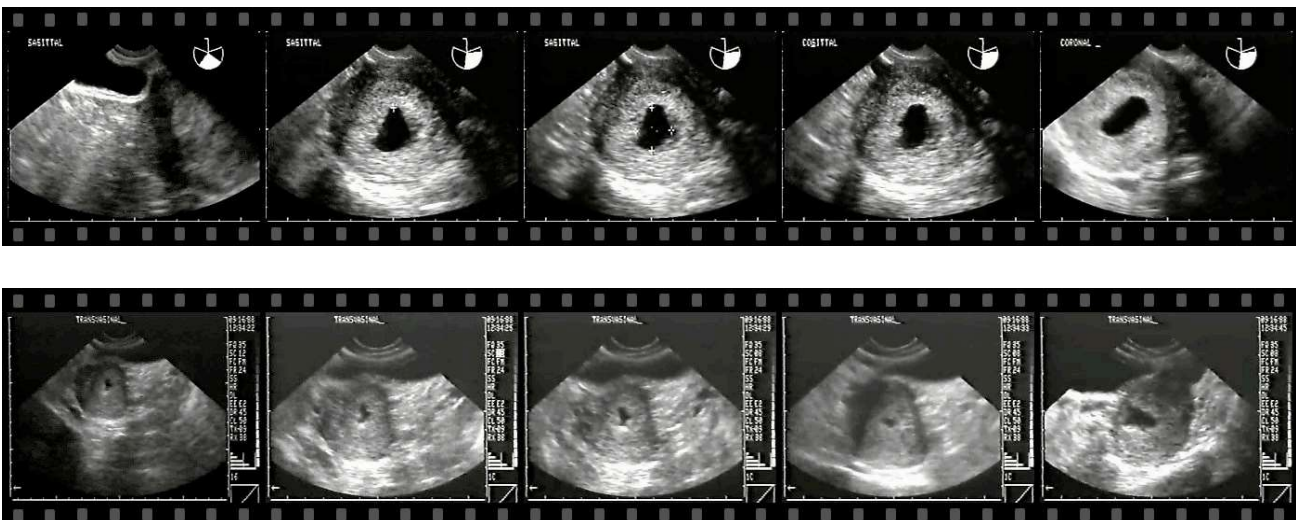6.3: Images of Anembryonic Gestations

Images



The images in this gallery show the features of anembryonic gestations including no yolk sac or embryo, abnormal shape and loss of the bright echogenic ring of chorionic villi.

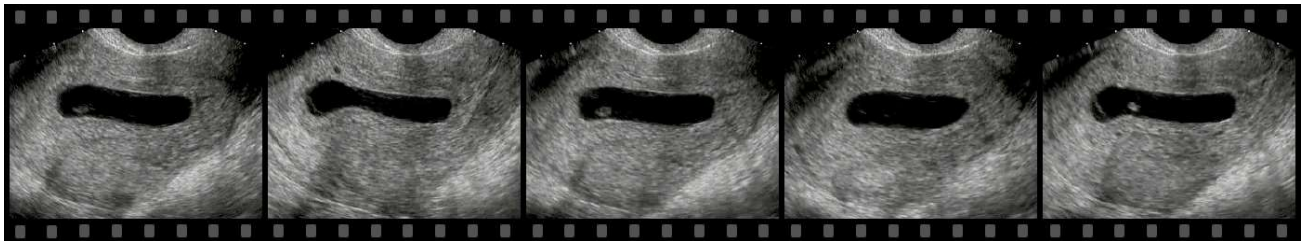Video frames



6.4: The Empty Amnion Sign

These cases show examples of the "empty amnion sign." The amnion usually becomes visible between 7 and 8 weeks gestation. In a normal pregnancy, the embryo fills the amniotic sac. In early pregnancy, the diameter of the amniotic sac is usually only 1-2 mm greater than the crown-rump length. If the amnion is readily visible but the embryo is not obvious, the pregnancy is abnormal. Because the embryo may be in different stages of development at the time of demise, this finding may be categorized either as an anembryonic pregnancy (if no embryo is apparent) or as an embryonic demise (if the embryo is apparent). This emphasizes the concept of early pregnancy failure as one entity.

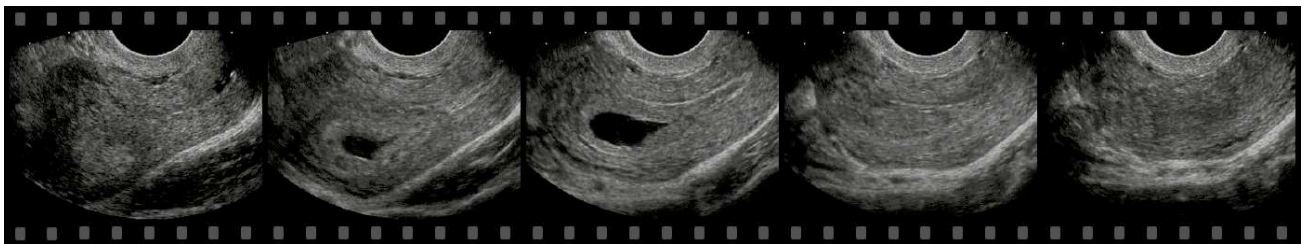Case 1



Eight week anembryonic pregnancy

In this longitudinal view, the amnion is visible in the fundal (left) aspect of the gestational sac. A smaller embryo without cardiac motion is visible at the inferior (right) edge of the amnion. The yolk sac is visible briefly in the middle of this set of video frames and then again at the end. This case would be considered an embryonic demise.

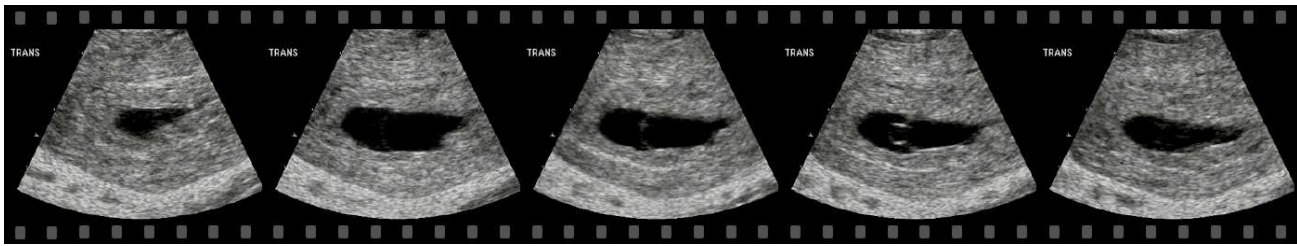
Case 2



Anembryonic pregnancy

In this longitudinal view, the yolk sac is above the larger but empty amnion. Note the irregular shape of the gestational sac.

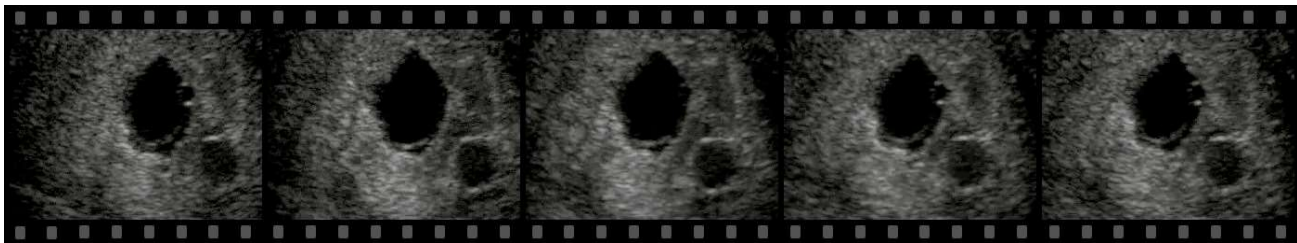Case 3



Anembryonic pregnancy

In this transverse view, the yolk sac is to the right of amnion. On the screen, it appears to the left of the amnion but this is the patient's right side. No embryo is apparent, and the gestational sac is irregular in shape.

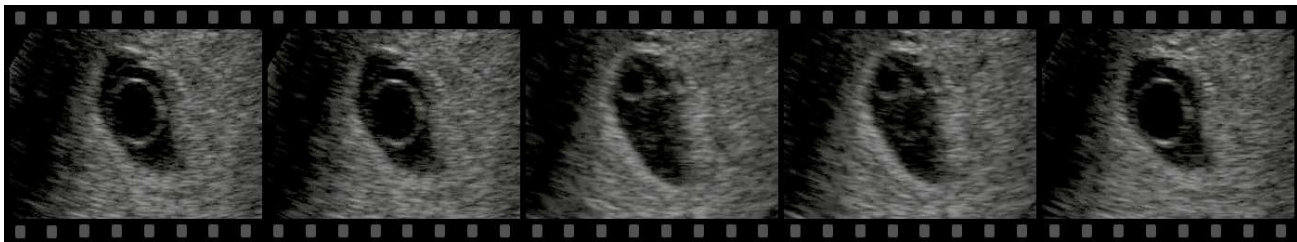Case 4



Anembryonic pregnancy

The amnion fills the gestational sac in this case, with the yolk sac squeezed to the side.

Case 5



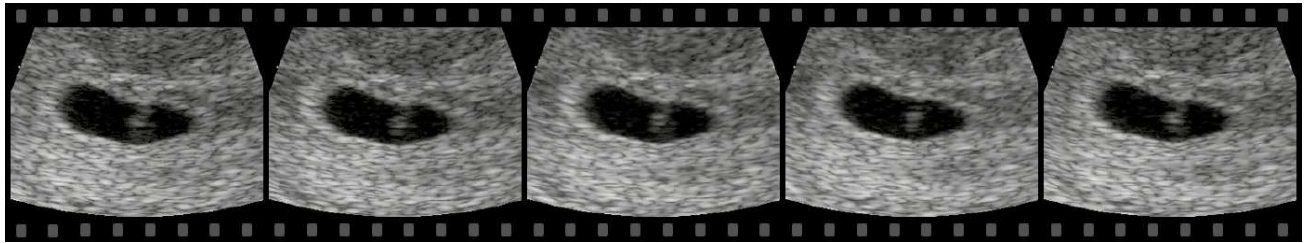Anembryonic pregnancy

In abnormal pregnancies, the amnion is often more prominent than expected for the gestational age. In this example, the mean sac diameter is only 16mm. One would not expect the amnion to be visible at this point in gestation if this were a normal pregnancy.

6.5: When Should Embryonic Cardiac Motion be Visible?

Embryonic cardiac motion should be seen by transvaginal scanning when the crown-rump length is 5mm or more

Finding an embryo with cardiac activity within the uterus is the "gold standard" for diagnosis of viable intrauterine pregnancy. Cardiac activity can usually be seen once the crown rump length reaches 3 mm, at roughly 6 1/2 weeks gestation. It should always be seen once the crown rump length reaches 5 mm. When using transvaginal imaging, the diagnosis of an embryonic demise can be confidently made if the crown-rump length is 5mm or more and no cardiac motion is seen.

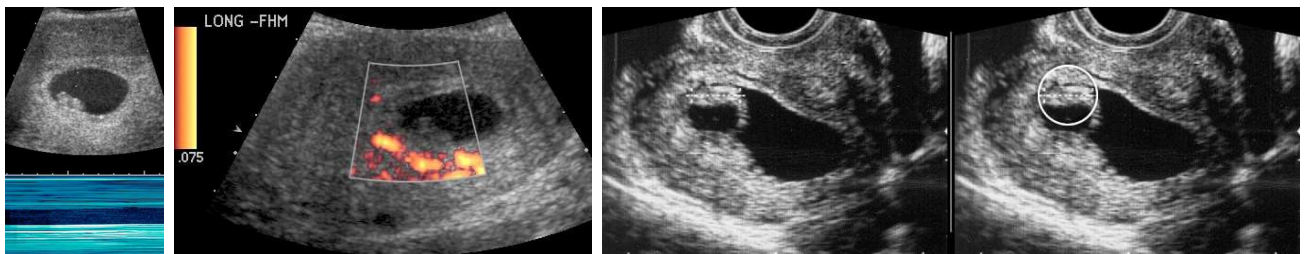


In real-time ultrasound of a normal pregnancy, embryonic cardiac activity is readily apparent. The crown-rump length is 3 mm.

6.6: Embryonic Demise

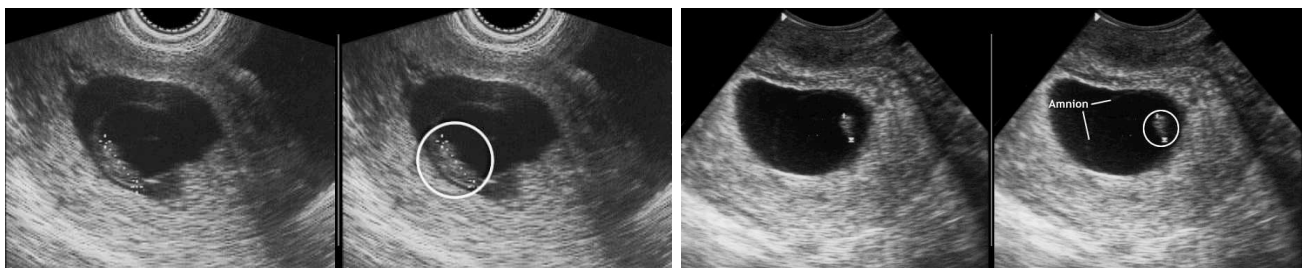


Images



Dead 7 week embryo: M-Mode

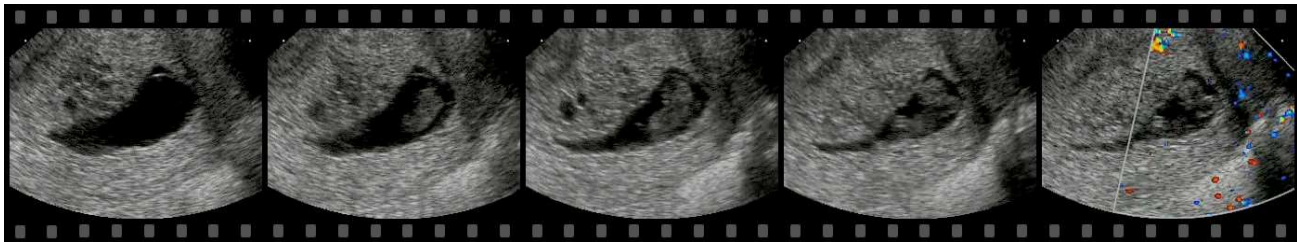Dead 7 week embryo: power doppler



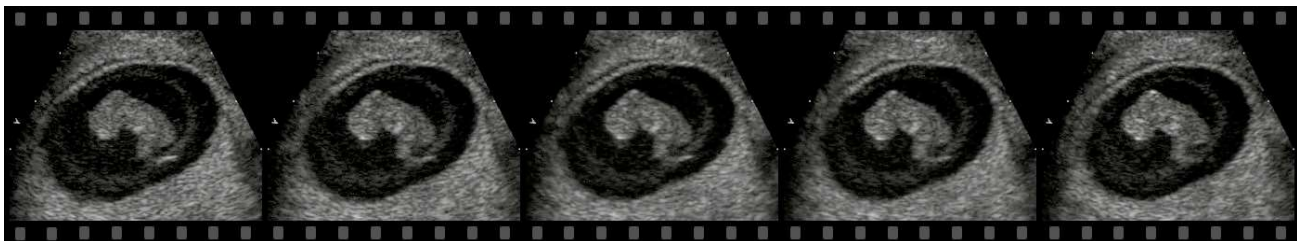Embryos with crown-rump length of 5 mm or more should exhibit cardiac motion. Cardiac motion can usually be seen earlier with transvaginal scanning. Diagnosis of an embryonic demise in a stable patient is not a medical emergency. Consultation and follow-up scanning for confirmation may be appropriate. These images show the variable sonographic appearance of embryonic demises between 7 and 9 weeks. The dead embryo often appears abnormally indistinct or "fuzzy," and smaller than expected for the patient's menstrual history since the embryo may have died several weeks earlier. In addition, the gestational sac is often abnormally shaped and loses its bright, echogenic rind of chorionic villi. The amnion is often much larger in diameter than the length of the embryo in case of demise, and can be considered a variant of the "empty amnion sign."

In the first two images, two different means of confirming an embryonic demise can be seen. In the first image, M-mode is used to document that there is no cardiac motion. In the second image, power Doppler is used to verify that no cardiac motion is present. The orange color shows blood flow around the gestational sac, but none is seen in the embryo. In general Doppler should be avoided in early pregnancy unless a demise is already strongly suspected; Doppler subjects the pregnancy to much greater sonographic energy than regular grayscale imaging.

Video frames

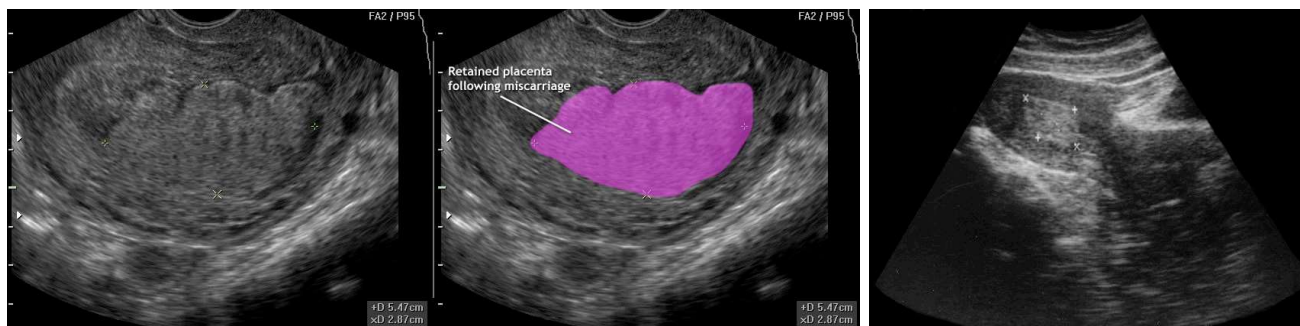


Dead 8 week embryo



Dead 9 week embryo

6.7: Incomplete Abortion

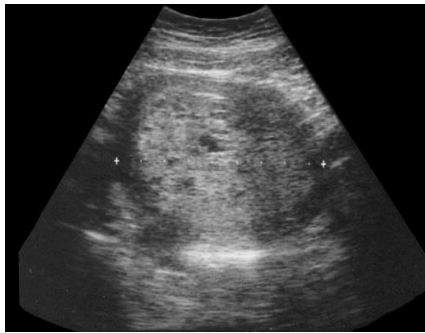


Complete abortion is characterized by visualizing an empty uterus. Incomplete abortion is characterized by visualizing echogenic material within the uterus. The thickness of the endometrial stripe of spontaneous abortion can be managed in the same way that it would be for a patient undergoing medication abortion. The sonographic demonstration of retained products of conception does NOT mean that the patient needs a dilatation and curettage, since the majority will proceed to completion without surgical intervention. These images show retained tissue measuring 20 to 30 millimeters within the uterus. Unless an intrauterine pregnancy was verified previously, an ectopic pregnancy must still be considered a possibility.

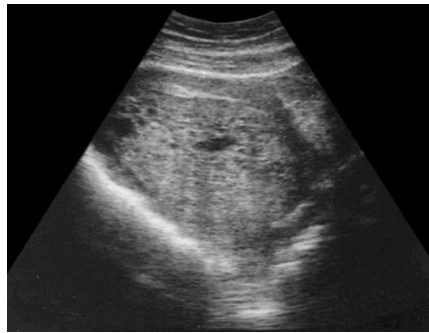
6.8: Molar Pregnancy

Although hydatidiform mole (known as molar pregnancy) is intrauterine, it is not a normal pregnancy. It is caused by chromosomal abnormalities. The early embryonic tissue grows abnormally so that in a complete mole, there is not an embryo or fetus. Hydatidiform mole, or molar pregnancy, produces heterogeneous echoes, often called the "snow storm" appearance. This appearance is the result of multiple small cystic spaces. The larger cysts are visible as sonolucent spaces while the smaller cysts create echogenic areas due to the multiple interfaces between the cysts. Molar pregnancies are often accompanied by theca lutein ovarian cysts. These images show hydatidiform mole.

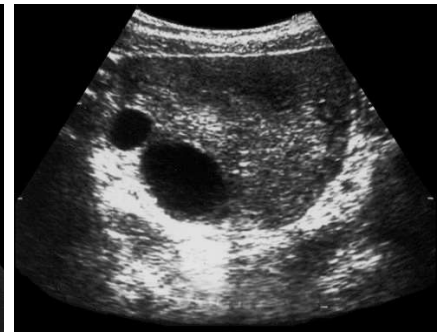Images



Transverse image of uterus filled with molar tissue

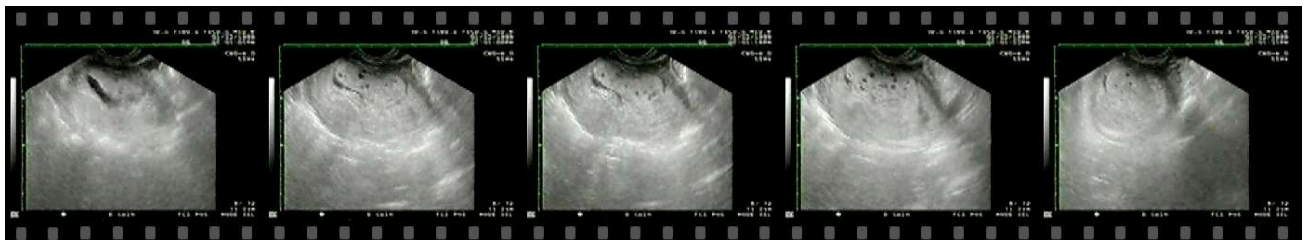


Longitudinal image of uterus filled with molar tissue



Transverse image of uterus filled with molar tissue and showing right-sided ovarian theca lutein cysts

Video frames

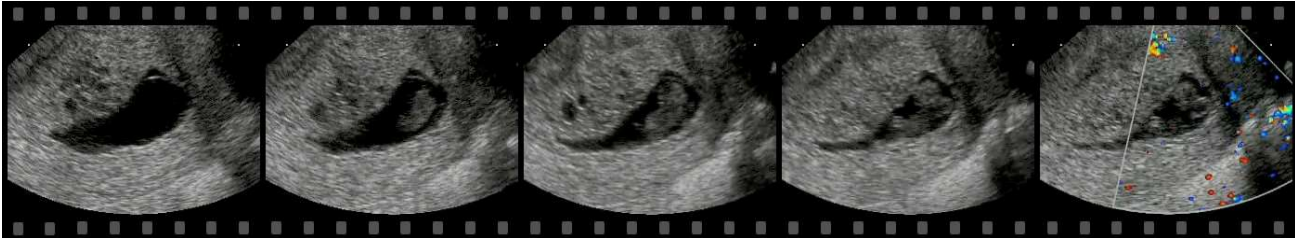

Video frames of uterus filled with molar tissue

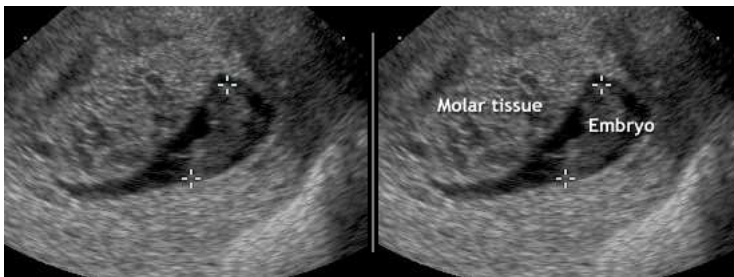
6.9: Partial Molar Pregnancy

Molar tissue may also accompany an embryo. This condition is termed "partial mole" and is illustrated in these still images and video frames.

Case 1

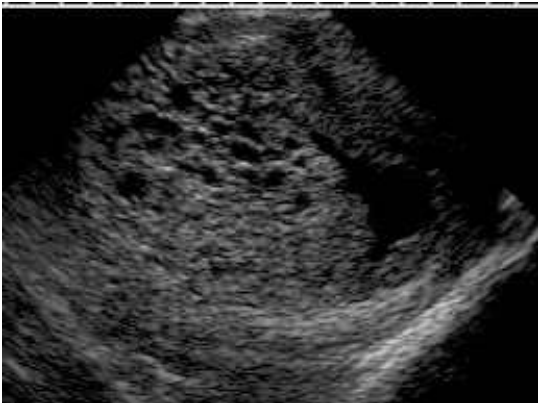

Video frames of partial molar pregnancy



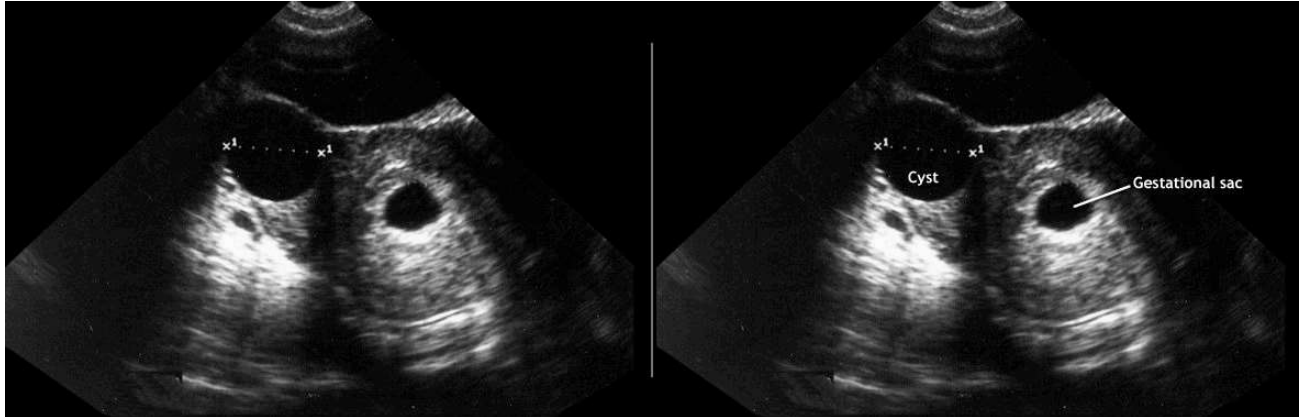
Still image of partial molar pregnancy

Case 2



12 week partial mole

6.10: Ovarian Cysts



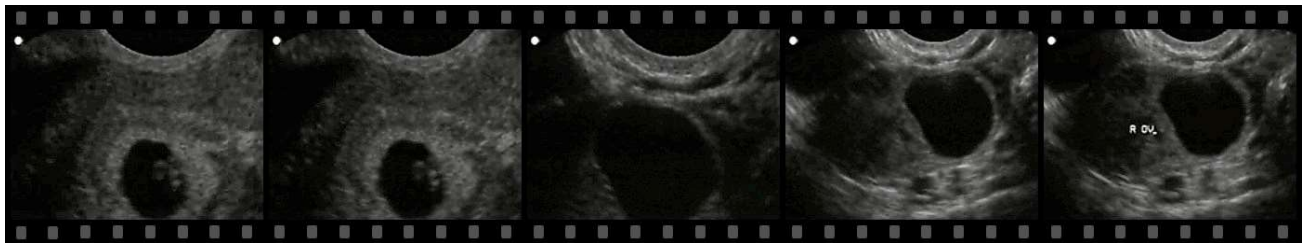
3 cm right adnexal cyst

During the first trimester, adnexal cysts are commonly seen. Usually, these represent normal corpus luteum cysts, which are often asymptomatic, incidental findings. They usually do not represent a pathologic process if other clinical and sonographic findings are normal. The still image shows a 3 centimeter cyst on the patient's right ovary, consistent with a corpus luteum cyst, adjacent to a pregnant uterus. The embryo is not visible inside the gestational sac in this image. The video frames show a 6 week pregnancy with an adjacent right ovarian cyst.

The most common mass seen on ultrasound is the corpus luteum cyst of the ovary. The corpus luteum cyst secretes progesterone to support pregnancy until the placenta can take over this hormone function at approximately 10 weeks LMP. The corpus luteum cyst of pregnancy is usually less than 5 cm in diameter and most commonly appears as a thin-walled, unilocular cyst. They may be much larger, occasionally attaining a size greater than 10 cm. Internal septations and echogenic debris may be secondary to internal hemorrhage. The cyst wall and septations may be thick.

Corpus luteum cysts usually regress or decrease in size between 14-18 weeks LMP. Cystic masses that persist should be followed.

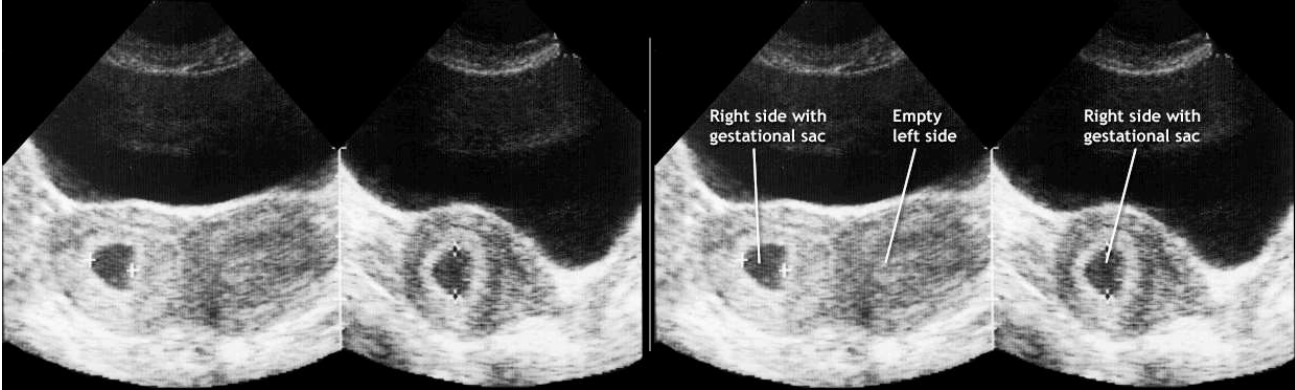
With careful sonographic examination, a corpus luteum can usually be identified during early pregnancy.



Six week pregnancy with adjacent ovarian cyst

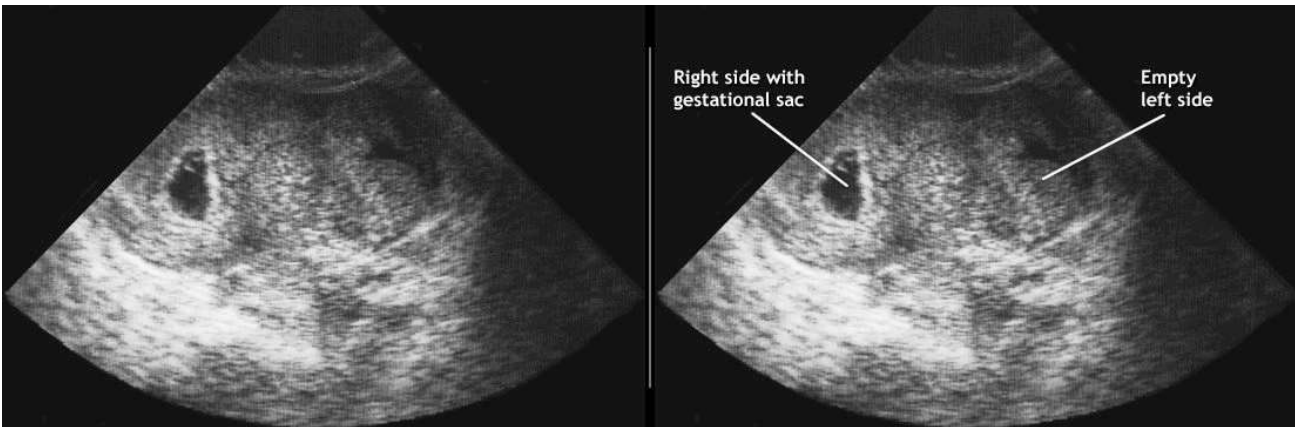
6.11: Pregnancy in an Anomalous Uterus

Bicornuate uterus sonograms



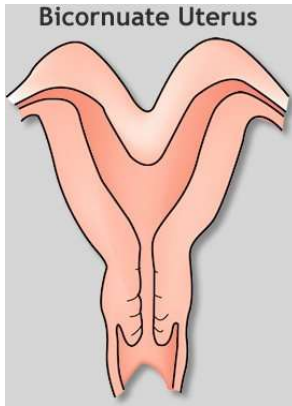
Transverse scan; Longitudinal scan right

Patients with bicornuate uterus or another type of abnormally shaped uterus may present a confusing clinical and sonographic picture. The empty side of the uterus may be mistaken for an adnexal mass or uterine fibroid.



Transverse transvaginal scan

Bicornuate uterus illustration



These images show a normal early pregnancy in the right horn of a patient's bicornuate uterus. At the time of uterine aspiration, it may be difficult to enter the correct horn without sonographic guidance. Rarely, more complex anomalies are seen. In very rare cases, uterine aspiration may not be possible.

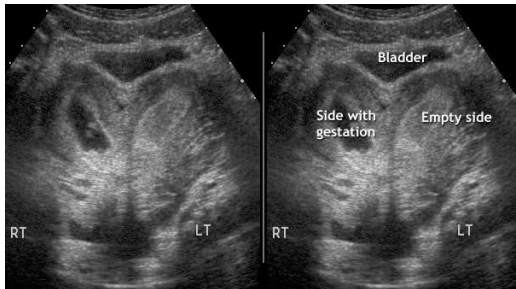
Bicornuate uterus

6.12: Pregnancy in an Anomalous Uterus: Cases

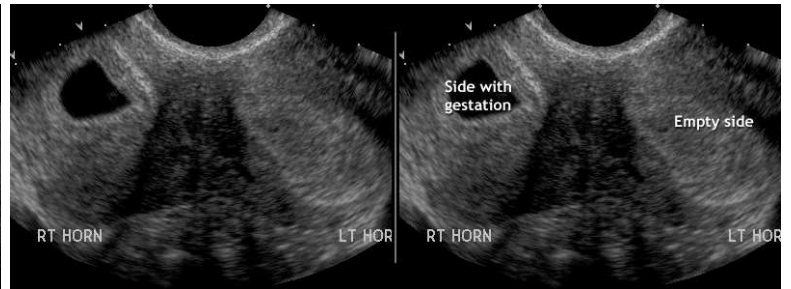

These images show additional cases of pregnancy in bicornuate uteri.

Case 1

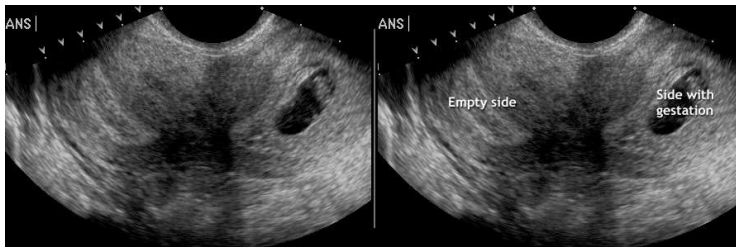


Transabdominal scan



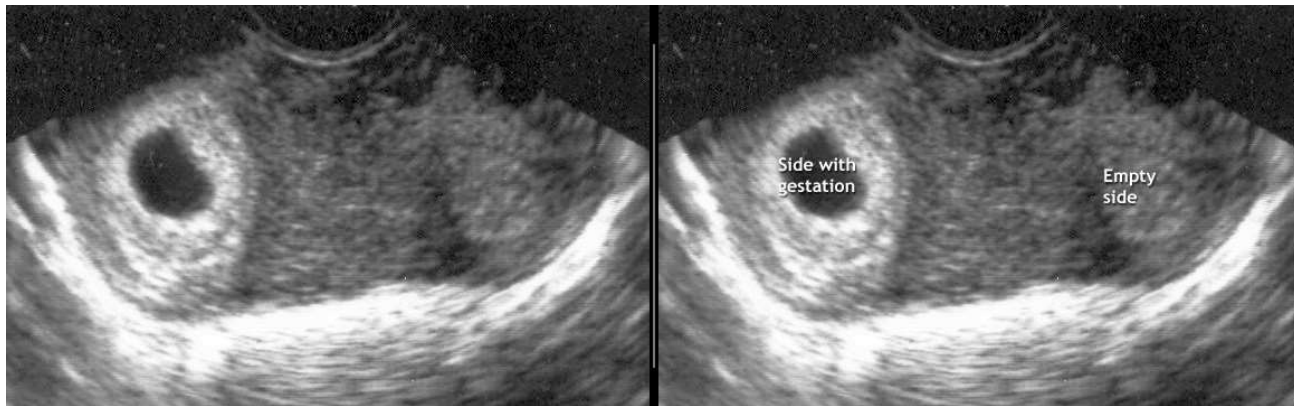
Transvaginal scan

Case 2



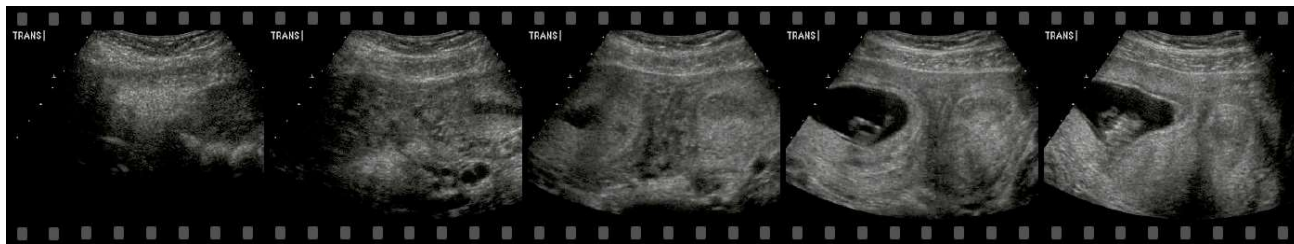Case 2

Case 3



Case 3

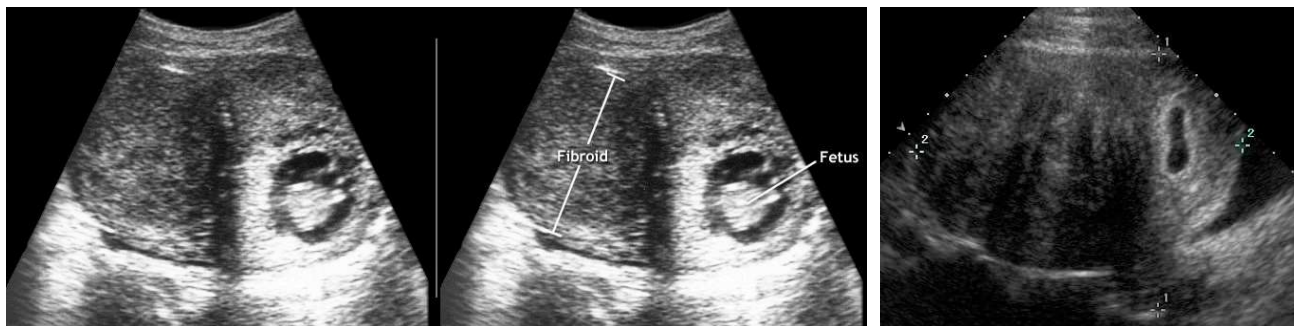
Case 4



Case 4

Notice the fluid in the endometrial cavity of the empty horn, in the first video frames. This finding is common.

6.13: Fibroids Accompanying Pregnancy



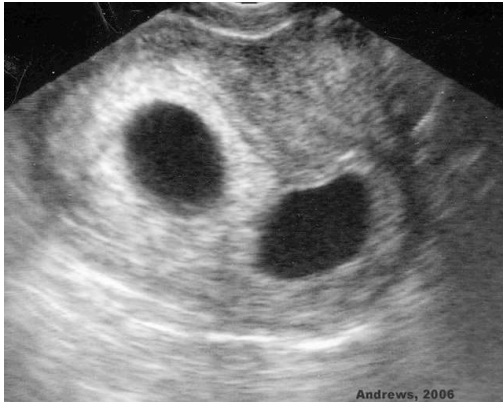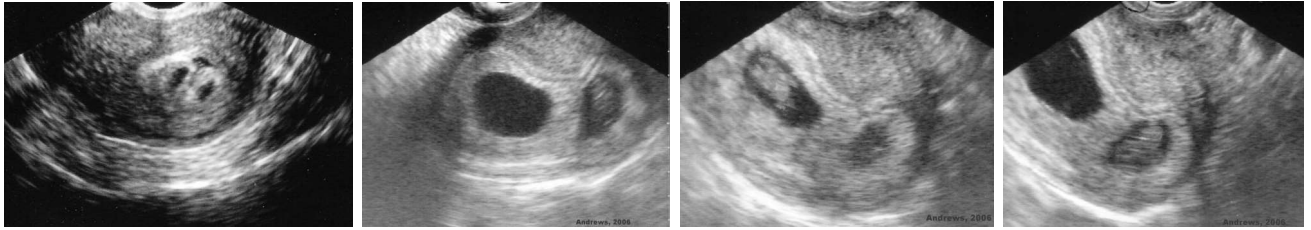6 cm Fibroid on right side of uterus

9 cm fibroid in first trimester

Uterine fibroids can distort the uterine shape and be mistaken for adnexal masses. They can become quite large during pregnancy and can cause pain. The left image shows a large 6 centimeter fibroid on the right side of a pregnant uterus in the first trimester. The right image show an early gestation adjacent to a 9 cm fibroid.

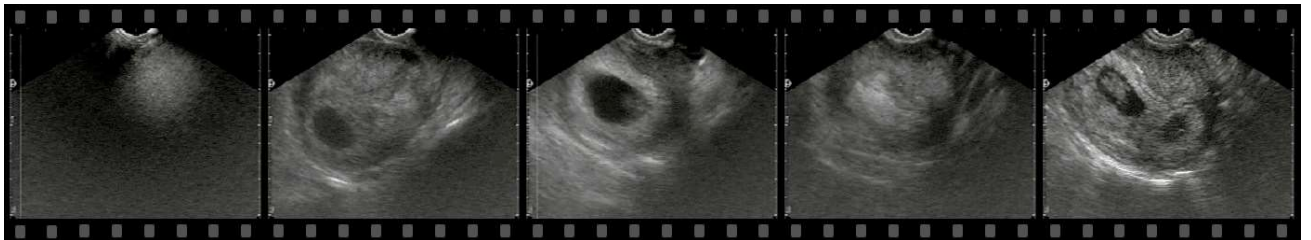6.14: Multiple Gestations

Images



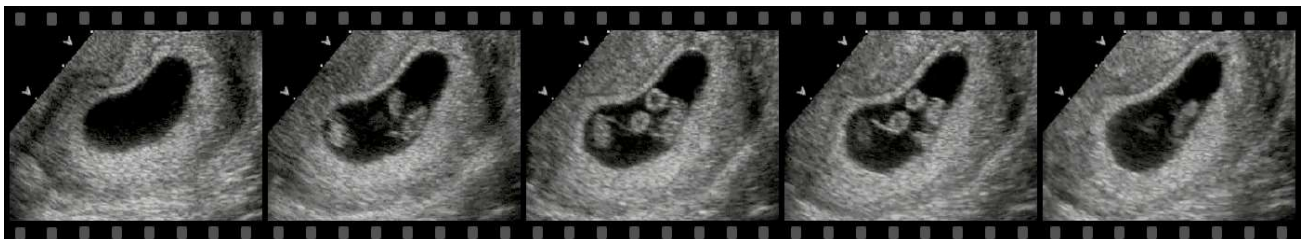When two gestational sacs are seen within the uterus in early pregnancy, a dichorionic twin pregnancy is diagnosed. Images should be obtained clearly demonstrating the presence of two sacs within the uterus. Each sac should be examined separately as a single gestation would be. This gallery of images shows twin pregnancies.

Video #1 frames



The first set of video frames shows the scanning process in a twin pregnancy.

Video #2 frames



Rarely, monozygotic twin pregnancies occur. In this case, two embryos will be identified within one gestational sac. The second set of video frames shows a monozygotic twin pregnancy. Two

embryos and two yolk sacs are visible. Later in pregnancy, knowledge of chorionicity is important but determination of chorionicity becomes more difficult. If a patient wishes to continue a twin pregnancy, images from the first trimester provide the best basis for determining chorionicity. Higher order gestations (triplets & quadruplets) may occur spontaneously but are extremely rare.

For patients wishing to continue a twin pregnancy to term, it's important to note in the first-trimester sonogram whether they were monochorionic (both embryos in the same sac) or dichorionic (two separate sacs). Monochorionic twins are at high risk for twin-to-twin transfusion syndrome and intrauterine growth restriction and need close surveillance as the pregnancy progresses.

7.1: Epidemiology of Ectopic Pregnancy

Risk factors for ectopic pregnancy:

- History of previous ectopic pregnancy
- History of pelvic inflammatory disease
- History of tubal surgery
- Current intrauterine contraceptive device

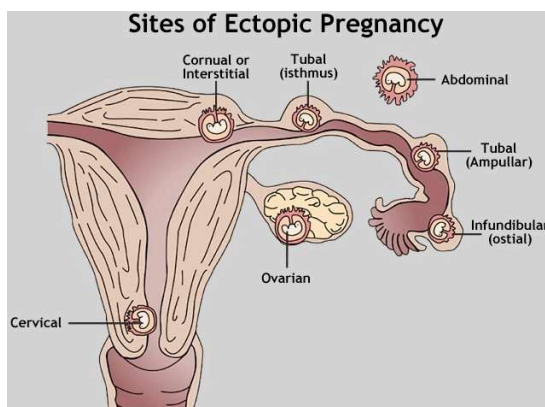
Ectopic pregnancy can lead to significant morbidity and even to mortality, so it is very important to keep this condition in mind when examining any woman in early pregnancy. The incidence of ectopic pregnancy has increased in recent decades to approximately reaching 1 in 50 pregnancies. The ectopic pregnancy rate is lower among women seeking abortion than it is in the general population, presumably since patients seeking abortion have a lower incidence of impaired fertility. (Creinin, MD and Edwards J. 1997. Early abortion: surgical and medical abortions. *Current Problems in Obstetrics, Gynecology and Fertility*, 20(1), 3-32.)

The single greatest risk factor for ectopic pregnancy is a history of previous ectopic pregnancy. Other risk factors for ectopic pregnancy include: a history of pelvic inflammatory disease, Chlamydia, or tubal surgery or current intrauterine contraceptive device use.

The starting point for ectopic pregnancy screening is always assessment of the uterus. Definitive identification of an intrauterine pregnancy effectively excludes ectopic pregnancy. Heterotopic pregnancies (with one intrauterine and one extrauterine gestation) are extremely rare in women not using assisted reproductive technologies. Therefore, the identification of an intrauterine pregnancy is sufficient to exclude ectopic pregnancy in most situations.

If uterine aspiration does not yield products of conception, despite presumed sonographic identification of an intrauterine pregnancy prior to the procedure, the patient should be evaluated as if she has an ectopic pregnancy until proven otherwise.

7.2: Locations of Ectopic Pregnancy



Ectopic pregnancies may become implanted anywhere in the fallopian tube, ovary, or abdominal cavity. 95-97% of ectopic pregnancies occur in the fallopian tube. Rarely, ectopic pregnancies can occur within the uterus but outside the endometrial cavity. These include cervical, cornual, interstitial, and Cesarean section scar ectopic pregnancies.

7.3: Clinical Findings with Ectopic Pregnancy



Symptoms:

- Abnormal bleeding
- Pelvic pain

Pelvic exam findings:

- Uterus smaller than expected
- Adnexal mass or tenderness

HCG findings:

- Above 2000 mIU/ml and uterus empty on transvaginal scanning
- Above 3600 mIU/ml and uterus empty on transabdominal scanning

Although any pregnant woman may have an ectopic pregnancy, those who present with certain signs and symptoms warrant close attention including an ultrasound examination by a provider with experience in first trimester scanning.

Symptoms that should arouse suspicion include abnormal bleeding or pelvic pain, particularly pain that is not midline. Suspicious signs found on pelvic exam are a uterus that feels smaller than expected and any adnexal mass or tenderness. Quantitative serum beta-hCG can also be a useful tool in the evaluation of a possible ectopic pregnancy. If the uterus appears empty on

transvaginal scanning and the beta-hCG is above 2000 mIU/mL, ectopic pregnancy is strongly suspected. Although transabdominal scanning is essential for a complete ultrasound examination, it should not be used alone to evaluate for an intrauterine pregnancy. If the beta-hCG is below this discriminatory zone in an asymptomatic patient, and the uterus appears empty, the pregnancy may simply be too early to identify sonographically. However, the majority of patients with an ectopic pregnancy present with a beta-hCG below 2000 mIU/mL. A low beta-hCG should not be used to conclude that an ultrasound would not be useful. Free fluid and an adnexal mass may still be visible when the beta-hCG is below 2000 mIU/mL.

Diagnosing an ectopic pregnancy can be difficult. Symptoms, examination findings and lab results vary greatly depending on the gestational age and location of the ectopic. For symptomatic patients, the evaluation for an ectopic pregnancy should be pursued in an emergency room or hospital setting.

7.4: Sonographic Findings that Suggest Ectopic Pregnancy



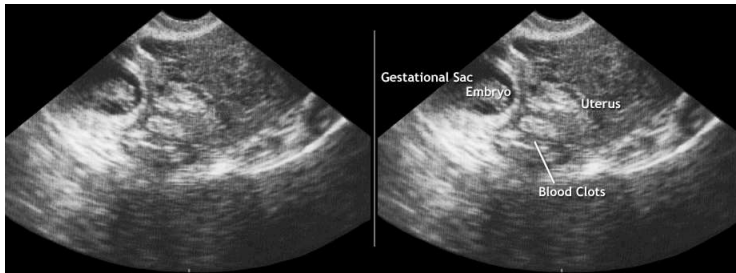
Sonographic Findings Suggestive of Ectopic Pregnancy:

- An adnexal mass outside the ovary
- Free fluid in the cul-de-sac
- Free fluid in the upper abdomen
- Abnormal-appearing fluid accumulation inside the endometrial cavity (pseudosac)
- IUD properly placed within uterus

During ultrasound scanning, there are several findings that strongly suggest ectopic pregnancy, even if an embryo is not seen outside the uterus. An embryo outside the uterus is seen in only a minority of cases of ectopic pregnancy. Strongly suggestive findings include: absence of a gestational sac 35 days after the last menses, absence of a yolk sac 40 days after the last menses, an abnormal-appearing fluid accumulation in the uterus, pain or bleeding noted during scanning, free fluid in the cul-de-sac, free fluid in the upper abdomen and presence of an intrauterine contraceptive device within the uterus. These sonographic findings will be illustrated in

subsequent lessons.

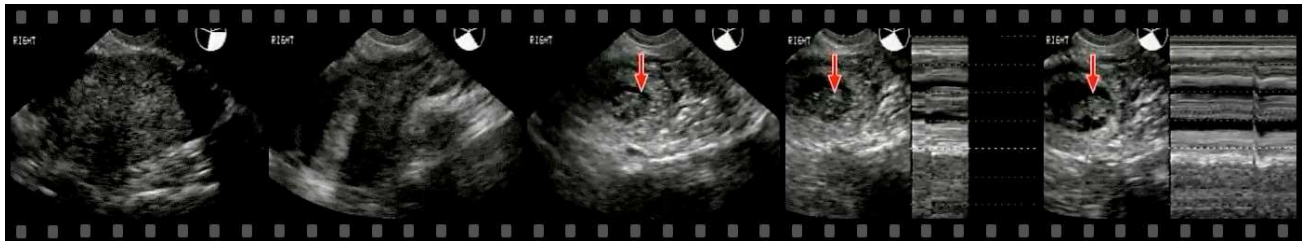
7.5: Advanced Ectopic Pregnancy



Ectopic pregnancy is diagnosed with certainty when the uterus is empty and an embryo with cardiac motion is identified outside of the uterus. This "gold standard" of ultrasonographic diagnosis is seen in only 5 to 10 percent of patients with ectopic pregnancies. Using both transabdominal and transvaginal scanning provides the greatest likelihood of correct diagnosis.

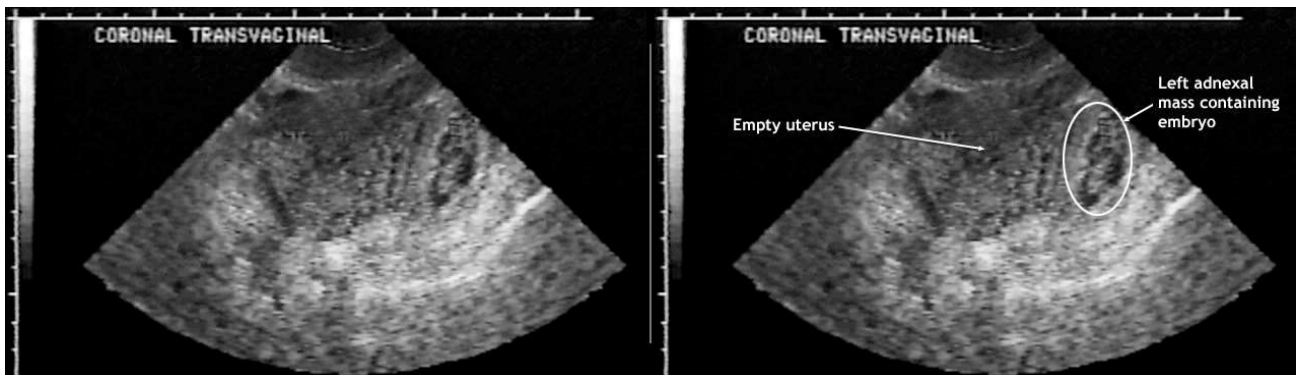
These images show an ectopic pregnancy at eight weeks. The uterus is empty. There are blood clots to the right of and behind the uterus. In the right adnexal area, a sac is seen that contains an embryo with clear cardiac motion documented with M-mode.

This advanced form of ectopic pregnancy is also the type most often incorrectly diagnosed by inexperienced ultrasound examiners. The thickened wall of the Fallopian tube can be misinterpreted as myometrium. However, with an ectopic pregnancy, a view where the pregnancy can be seen in line with the cervix is not possible. This is why the "papaya" view is an essential part of confirming an intrauterine pregnancy (see chapter 5).

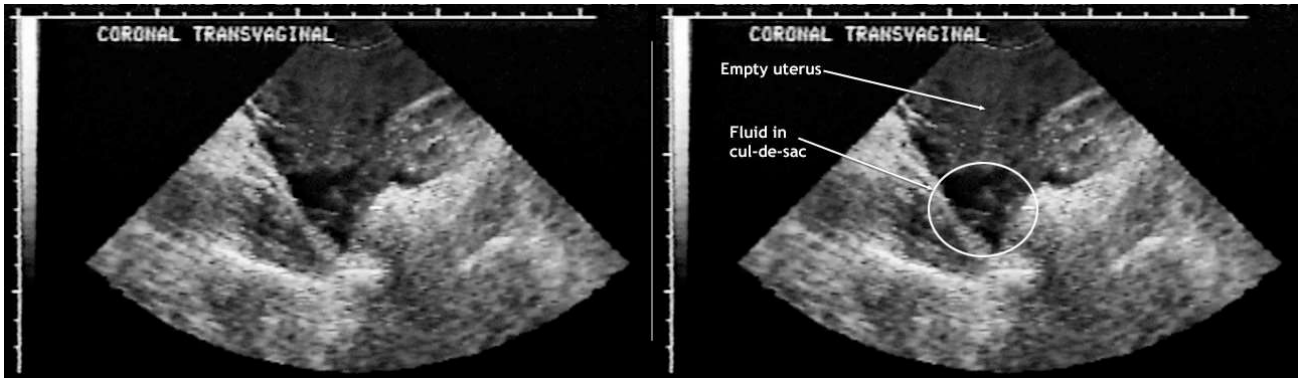


7.6: Another Obvious Ectopic Pregnancy

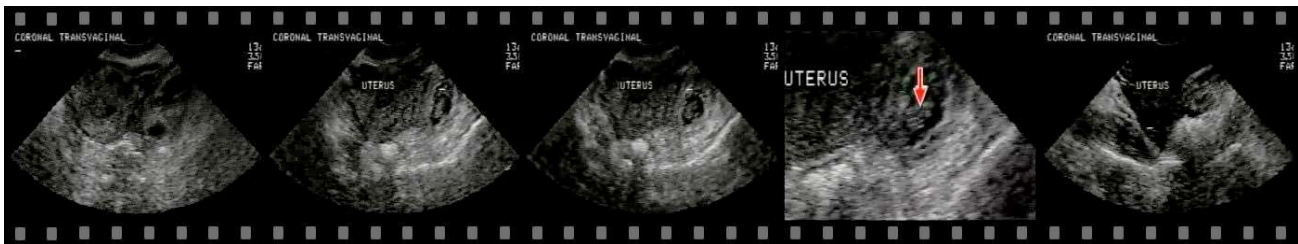Images



Here is another set of images of an obvious ectopic pregnancy. This one is at seven weeks. The video shows the empty uterus, the sac containing an embryo with cardiac motion in the left adnexal area, and free blood in the cul-de-sac.



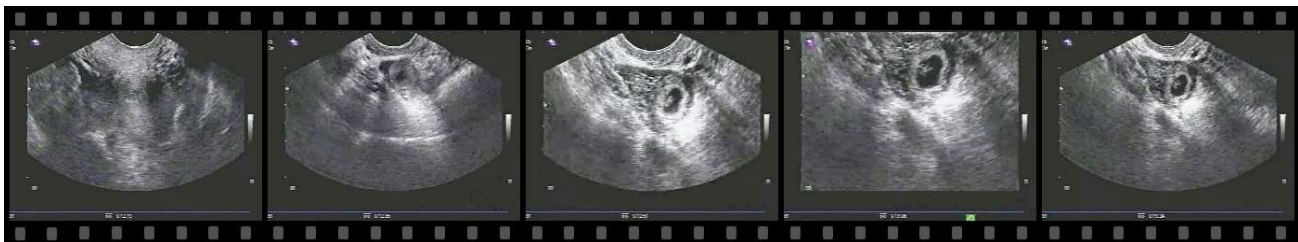Video frames



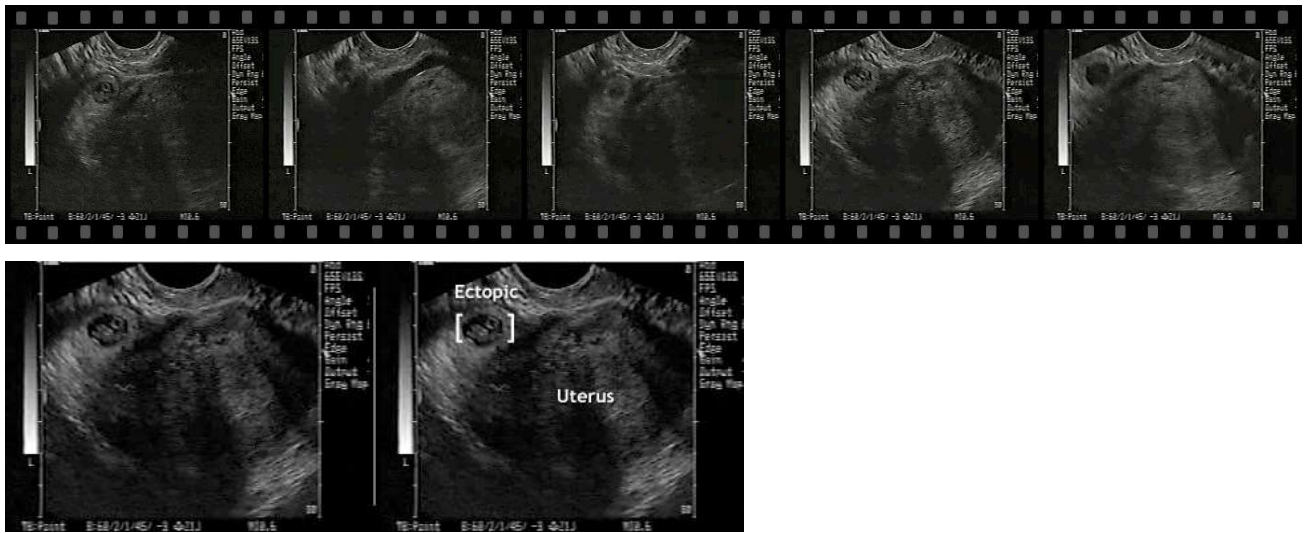
7.7: Ectopic Pregnancy Cases: Extrauterine Embryo with Cardiac Activity

These cases show extrauterine embryos with cardiac activity.

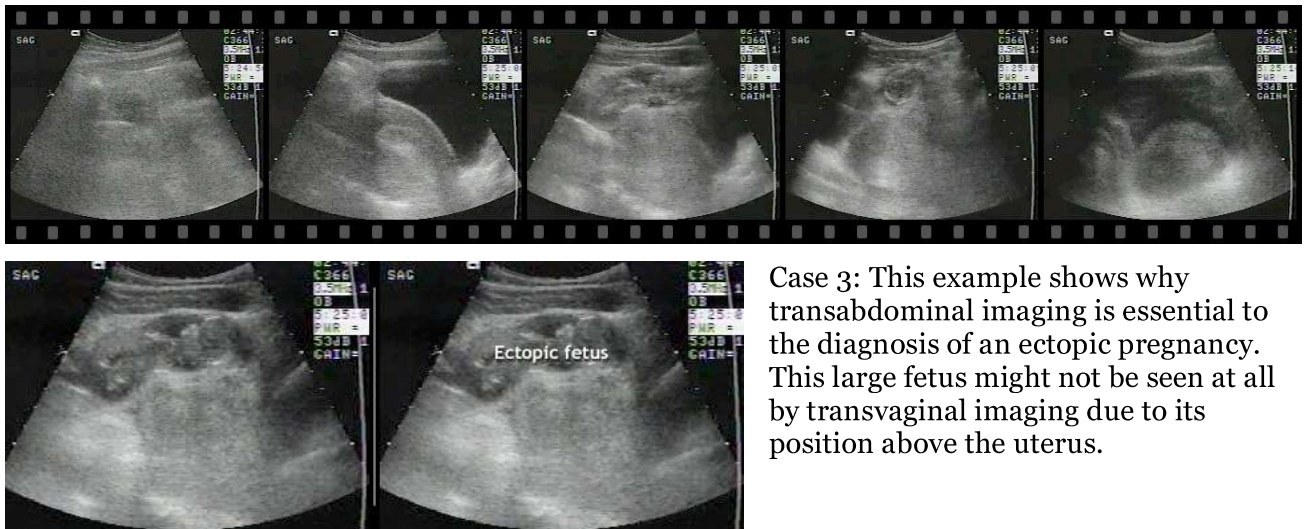
Case 1



Case 2



Case 3



Case 3: This example shows why transabdominal imaging is essential to the diagnosis of an ectopic pregnancy. This large fetus might not be seen at all by transvaginal imaging due to its position above the uterus.

7.8: Sonographic Signs of Ectopic Pregnancy: Fluid and Masses

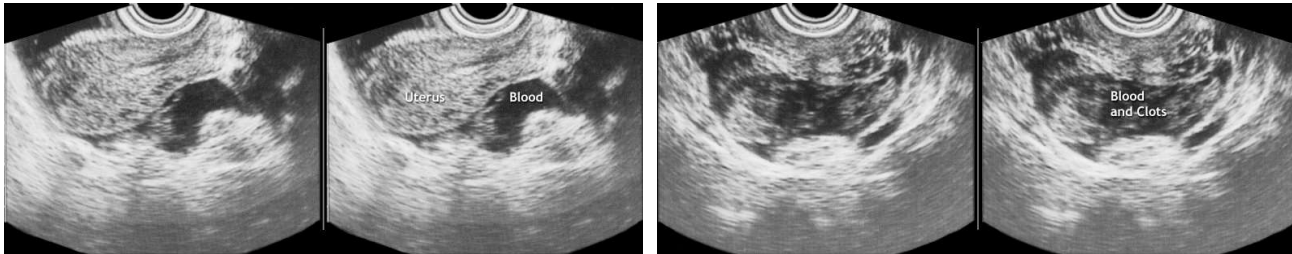
Finding:	Risk of ectopic:
• No mass or free fluid	20%
• Any free fluid	71%
• Echogenic mass	85%
• Moderate to large amt. fluid	95%
• Echogenic mass with fluid	100%

Mahony BS, Filly RA, Nyberg DA, Callen PW.
 "Sonographic evaluation of ectopic pregnancy."
J Ultrasound Med 1985; 4:221-228

Since an embryo outside the uterus is not usually seen in cases of ectopic pregnancy, other sonographic findings are extremely important clues to ectopic pregnancy. A patient with a positive pregnancy test and an empty uterus should be highly suspect for ectopic pregnancy. If there is any adnexal mass or free pelvic fluid, the suspicion should be extremely high as shown by this table. These data are from symptomatic patients presenting to the emergency room.

7.9: Free Fluid and Masses

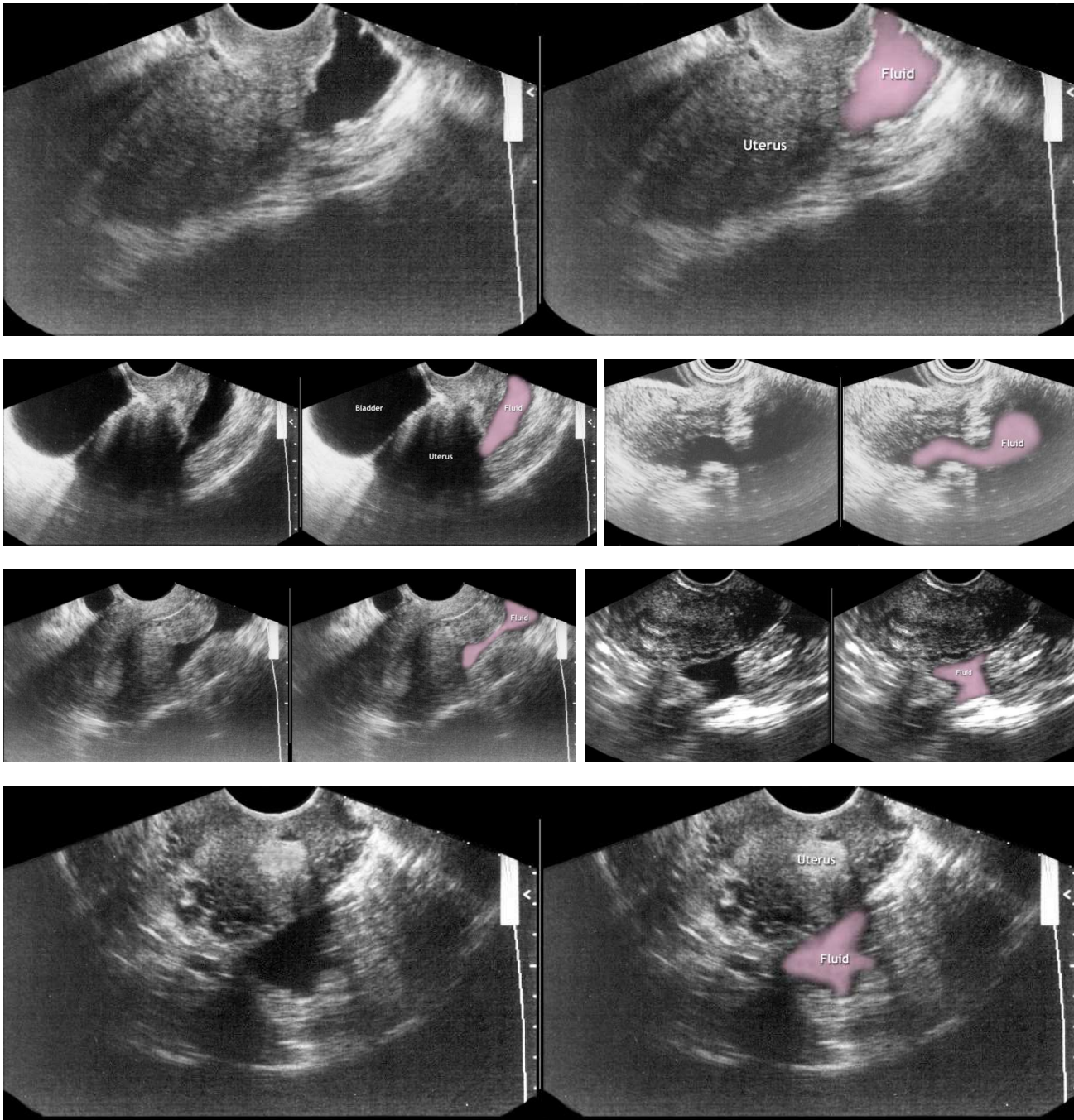
Images



Longitudinal transvaginal scan: empty uterus with an adnexal mass Transverse transvaginal scan: blood and clots in the cul-de-sac

Any patient with a positive pregnancy test, an empty uterus, and free pelvic fluid or a pelvic mass has an ectopic pregnancy until proven otherwise. The free fluid is fluid not contained within a body organ such as the bladder, bowel, or an ovarian cyst. In the case of ectopic pregnancies, the fluid is blood. Masses may represent the ectopic pregnancy itself, blood clots, or, more commonly, a combination of clots and the ectopic mass. These images and the video frames that follow show the sonographic appearance of free pelvic fluid and pelvic masses in patients with ectopic pregnancy but no visible embryo. For patients desiring termination of pregnancy, uterine aspiration allows definitive diagnosis.

7.10: Gallery of Images Showing Free Pelvic Fluid

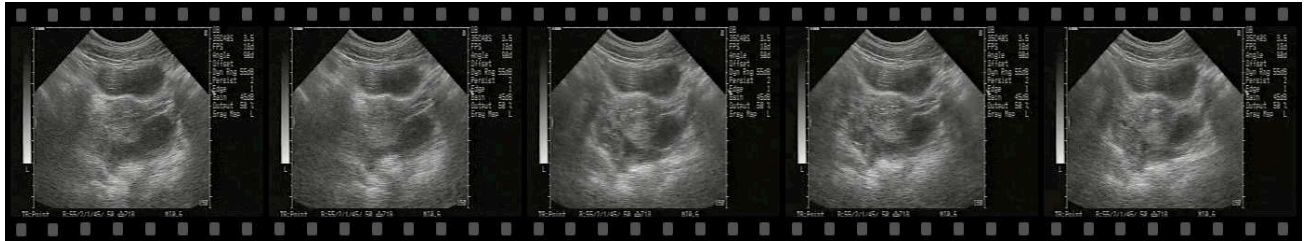


This gallery of images shows the sonographic appearance of free pelvic fluid in the cul-de-sac as seen during transvaginal scanning.

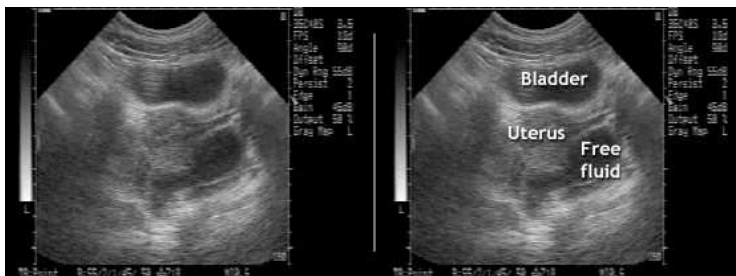7.11: Ectopic Pregnancy Cases: Mainly Free Intra-abdominal or Pelvic Fluid

These are examples of mainly free intra-abdominal or pelvic fluid. Although transvaginal imaging is essential to confirm absence of an intrauterine gestation, these examples demonstrate the importance of transabdominal imaging in assessing for free fluid and masses, which may extend out of the pelvis beyond the view of transvaginal imaging.

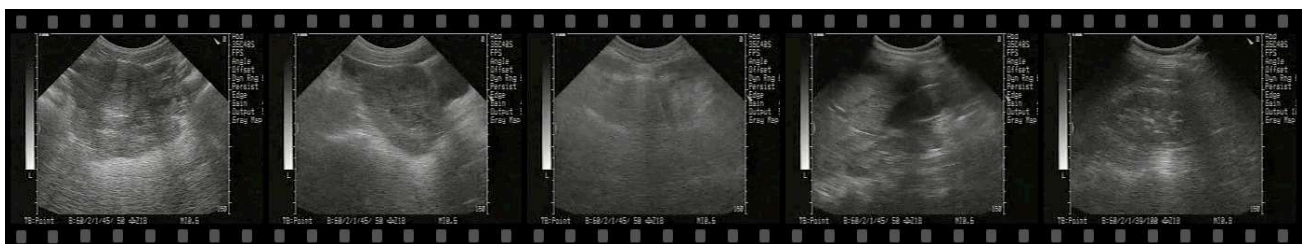
Case 1



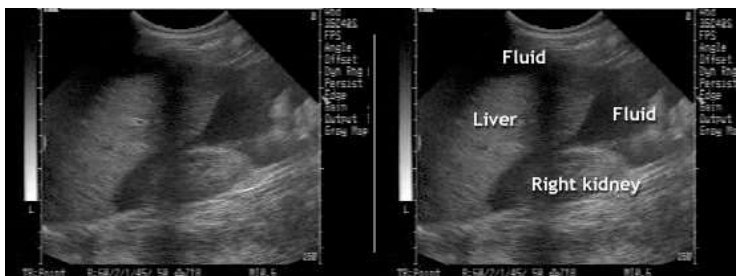
Transabdominal transverse imaging of free fluid



Case 2

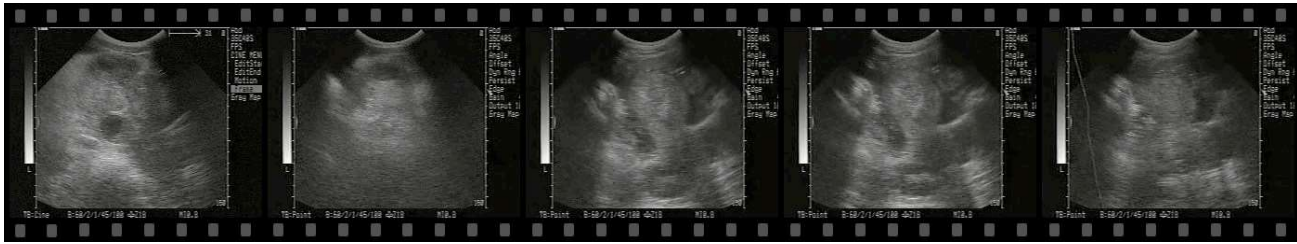

Transabdominal imaging from the uterus moving to the right upper quadrant

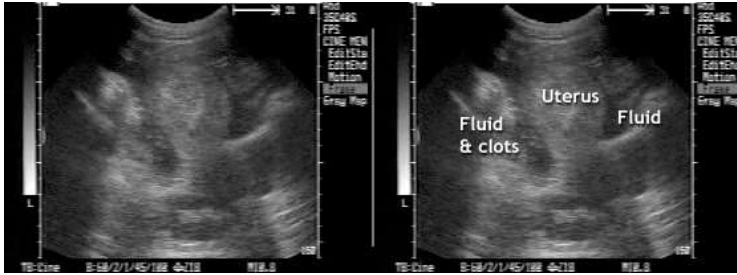


Free fluid between the right kidney and the liver (Morrison's Pouch); highly concerning for ruptured ectopic pregnancy.

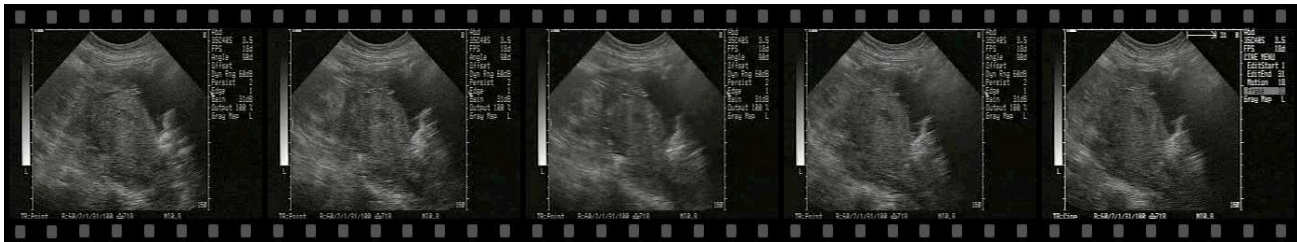
Case 3



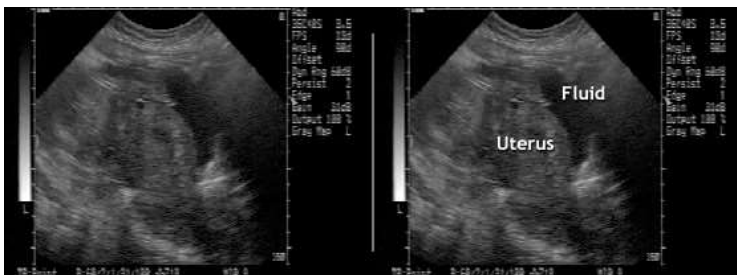Transabdominal imaging of free fluid



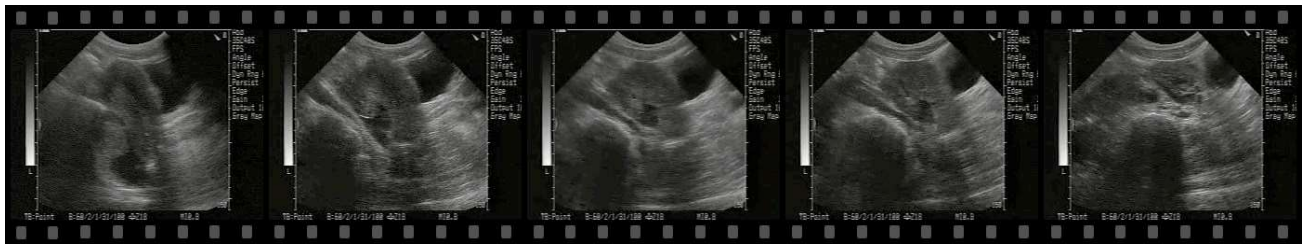
Case 4



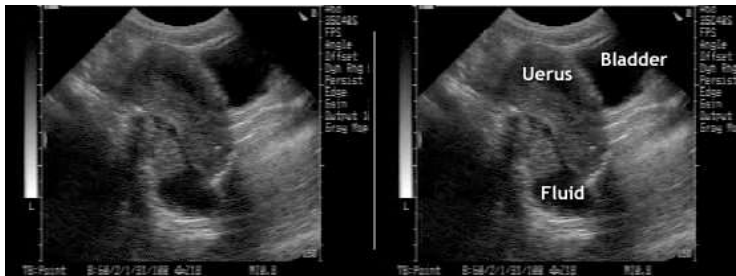
Transabdominal longitudinal imaging of free fluid



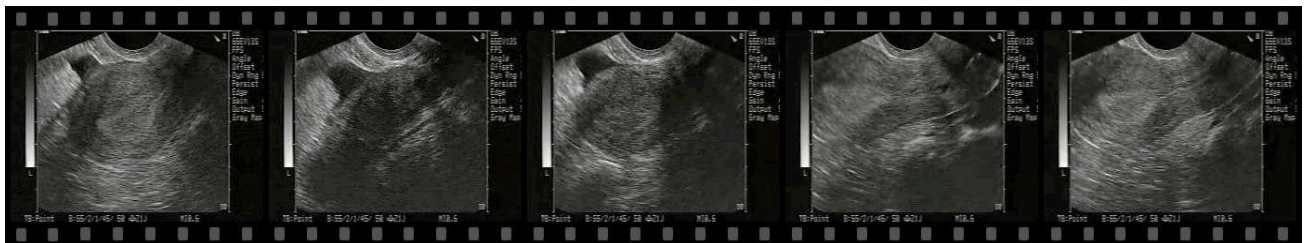Case 5



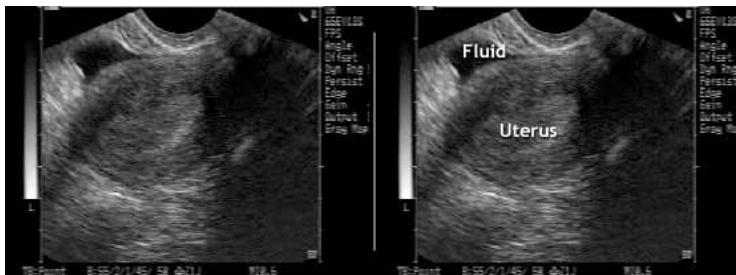
Transabdominal longitudinal imaging of free fluid



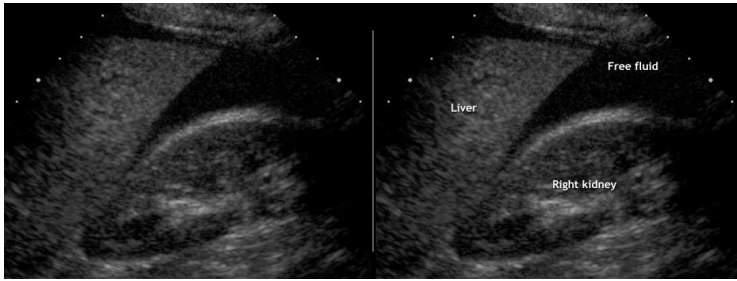
Case 6



Transabdominal longitudinal imaging of the uterus and free fluid



Case 7

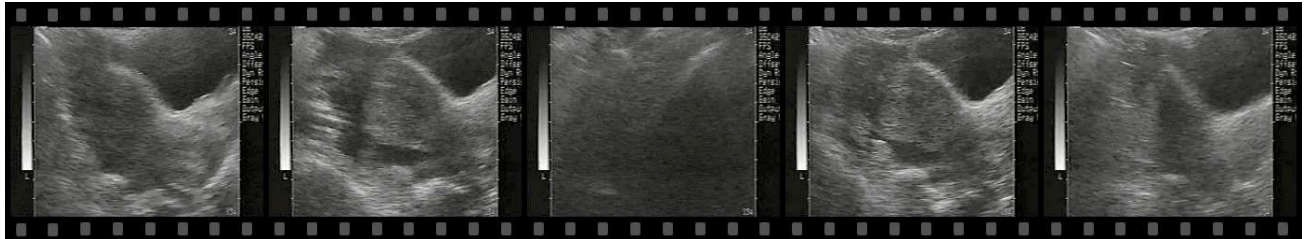


Free fluid in Morrison's Pouch

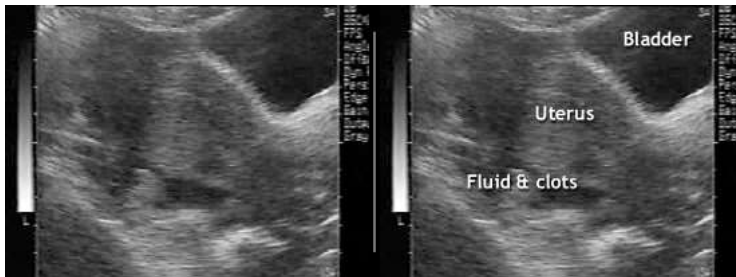7.12: Ectopic Pregnancy Cases: Free Fluid and a Mass or Tubal Ring

These cases show examples of free fluid and a mass or tubal ring of an ectopic pregnancy.

Case 1a

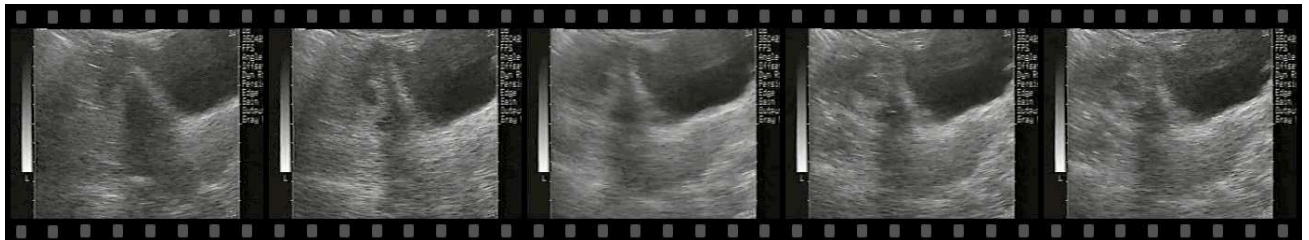

Transabdominal longitudinal imaging of free fluid and ectopic pregnancy

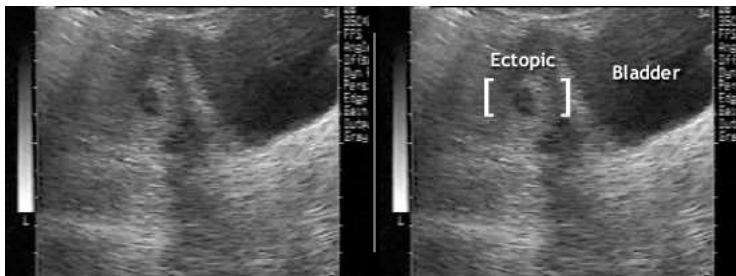


Free fluid with clot

Case 1b

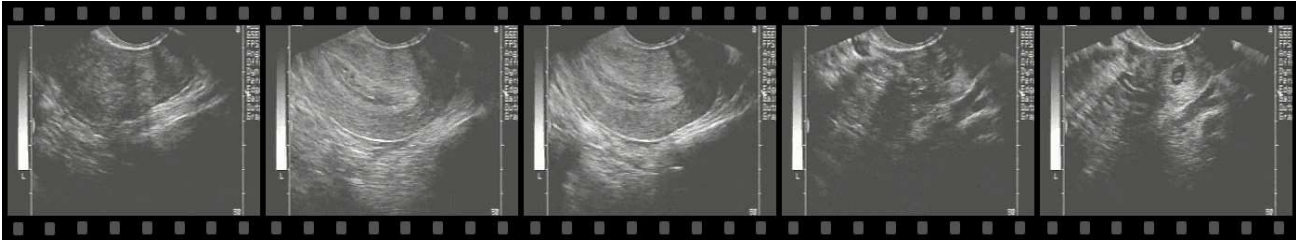


Transabdominal longitudinal imaging of free fluid and ectopic pregnancy

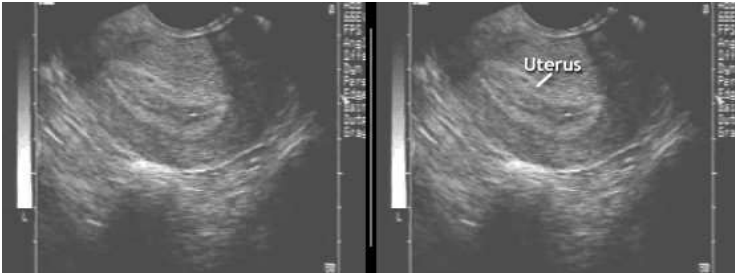


Ectopic pregnancy identified

Case 2a

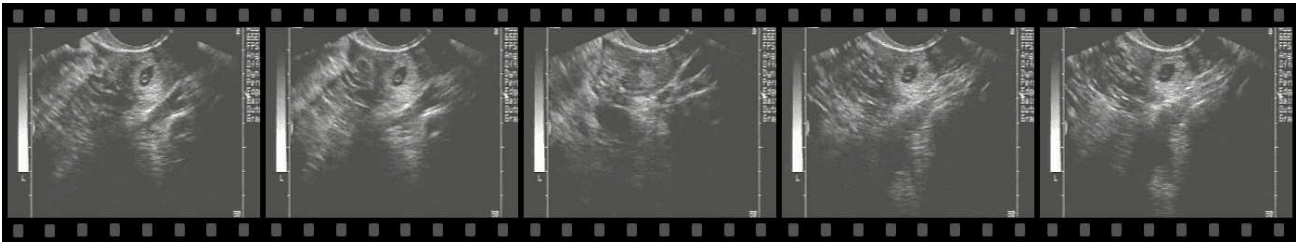


Transvaginal longitudinal imaging of free fluid and ectopic pregnancy

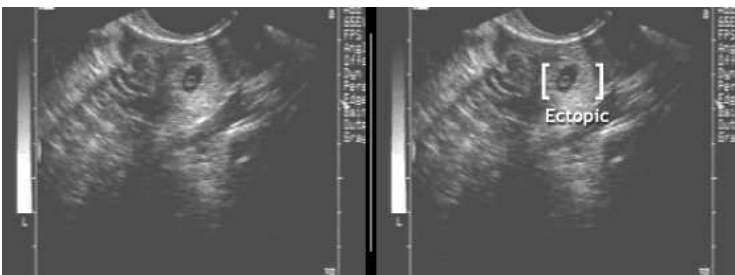


Empty uterus with small free fluid with dot

Case 2b

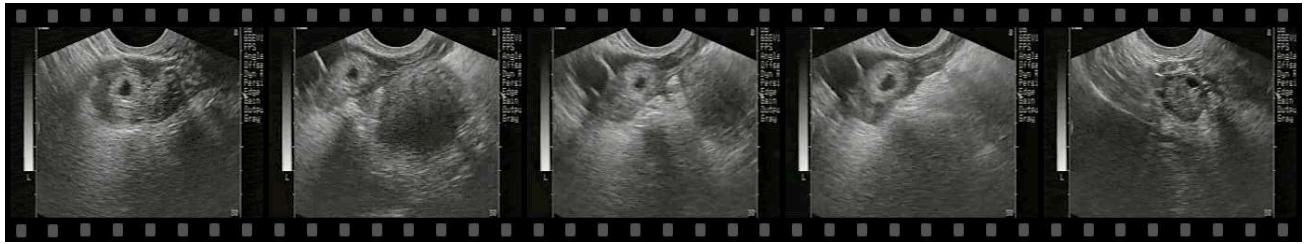

Transvaginal longitudinal imaging of free fluid and ectopic pregnancy

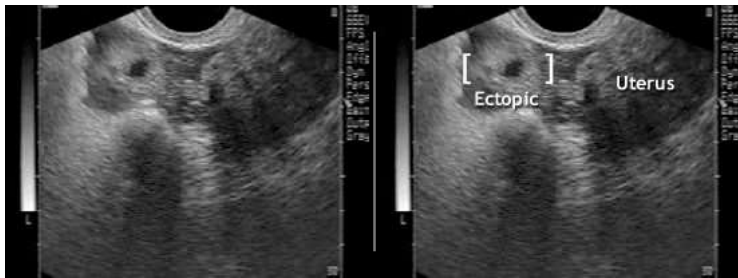

Ectopic pregnancy with yolk sac identified

Case 3a

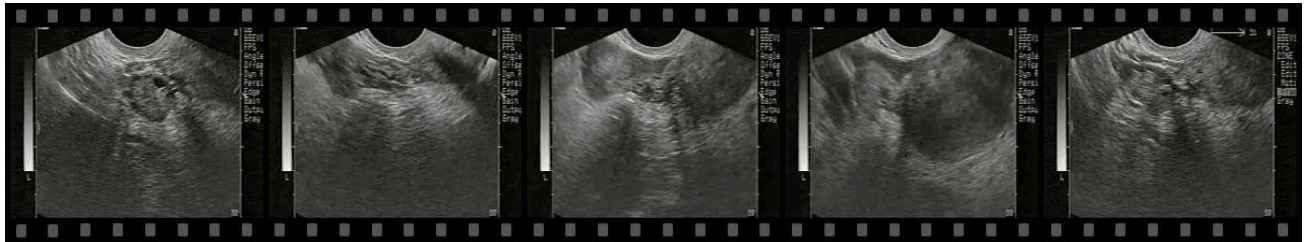

Transvaginal imaging of ectopic pregnancy with free fluid

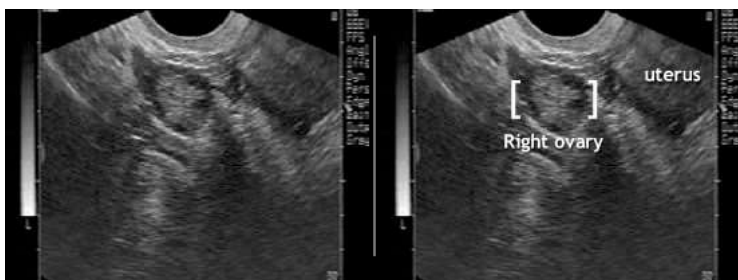


Ectopic pregnancy adjacent to empty uterus with surrounding free fluid

Case 3b

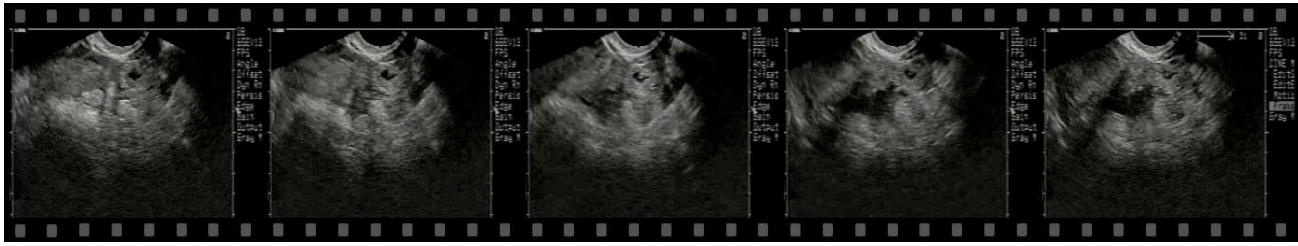


Transvaginal imaging of ectopic pregnancy with free fluid

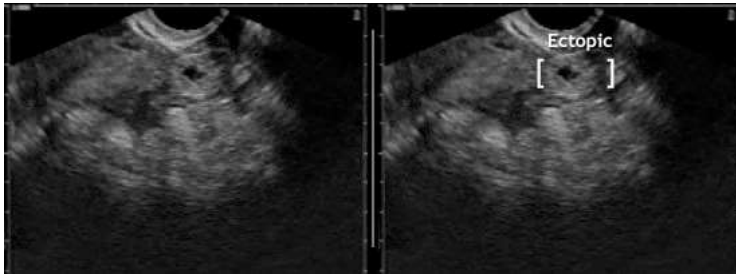


Normal right ovary identified separate from ectopic pregnancy

Case 4

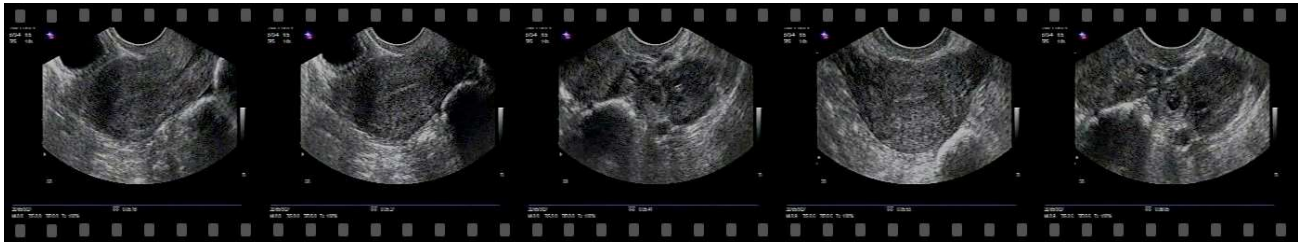

Transvaginal imaging of ectopic pregnancy

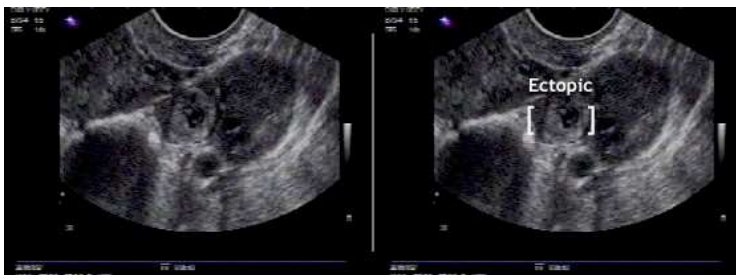

Left tubal ring

Case 5

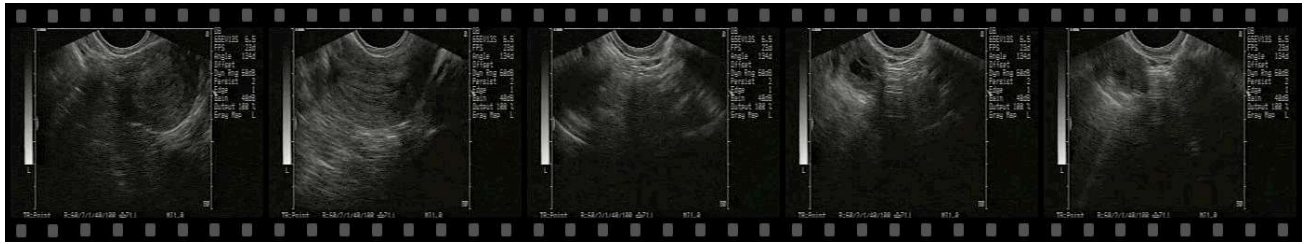


Transvaginal imaging of ectopic pregnancy between the empty uterus and left ovary

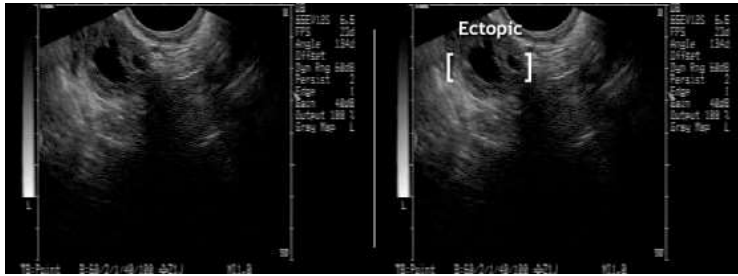


Left tubal ring

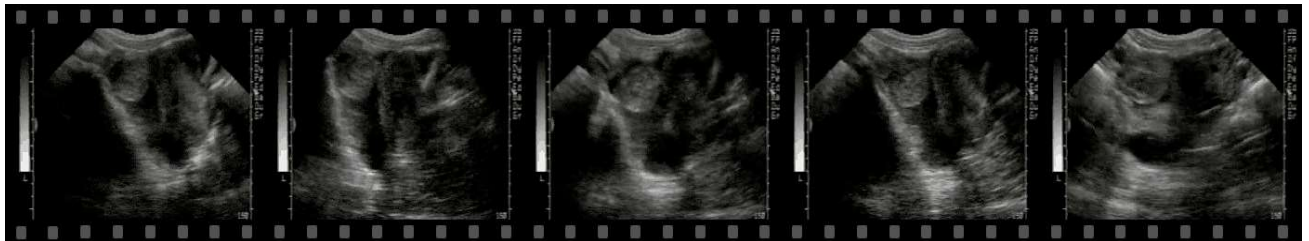Case 6



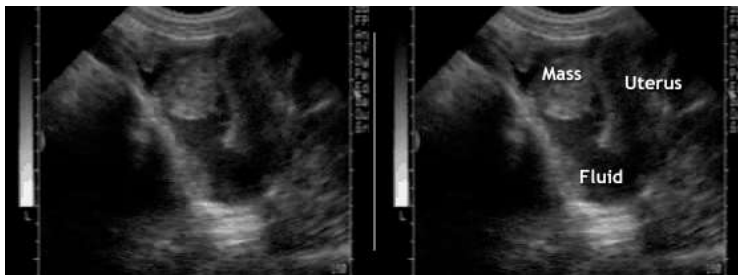
Transvaginal imaging of empty uterus and ectopic pregnancy



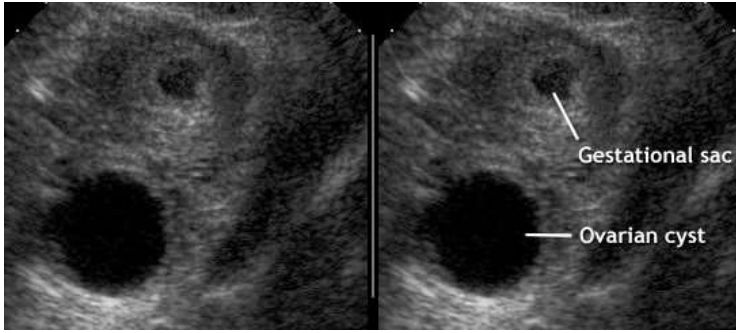
Case 7



Transabdominal imaging of a mass superior to the empty uterus with copious free fluid



7.13: Cornual Pregnancy Case



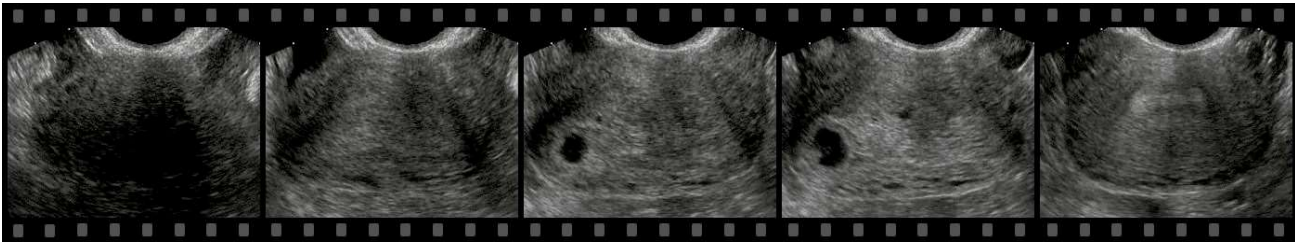Cornual ectopic

These video frames show an example of cornual ectopic pregnancy. A cornual pregnancy implants at the site where the uterine cavity and fallopian tube meet. Cornual ectopic pregnancies represent 2 to 4% of all ectopic pregnancies but have a high morbidity and mortality because of later detection and massive hemorrhage, often in the second trimester. In a cornual ectopic pregnancy, the myometrium of the uterus surrounds a portion of the

expanding gestational sac, allowing it to enlarge painlessly.

On ultrasound, the cornual ectopic pregnancy is seen at the lateral edge of the uterus, on the right in this case. The myometrium surrounding it is thin at the outer edge. Although the endometrium extends to meet the pregnancy, the pregnancy could not be seen in line with the cervix on longitudinal imaging. Thus, like other ectopic pregnancies, the papaya view is still key to diagnosis. Like most ectopic pregnancies, free fluid was identifiable.

Uterine aspiration should not be attempted in the clinic setting if a cornual pregnancy is suspected as rupture and hemorrhage can occur. Patients with suspected cornual ectopic pregnancy should be referred to a hospital setting for further evaluation and treatment.

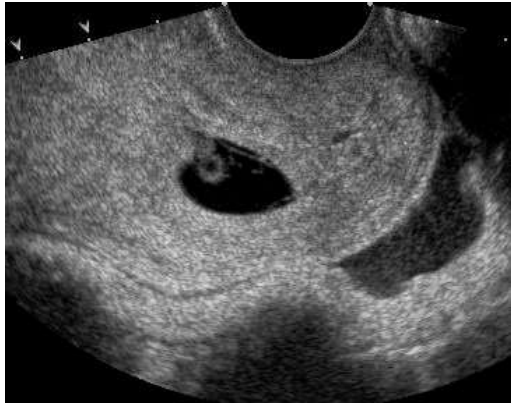
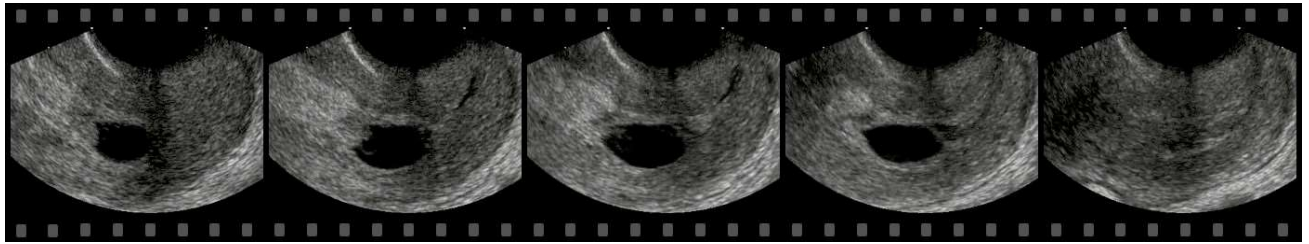
7.14: Cervical Ectopic Pregnancy



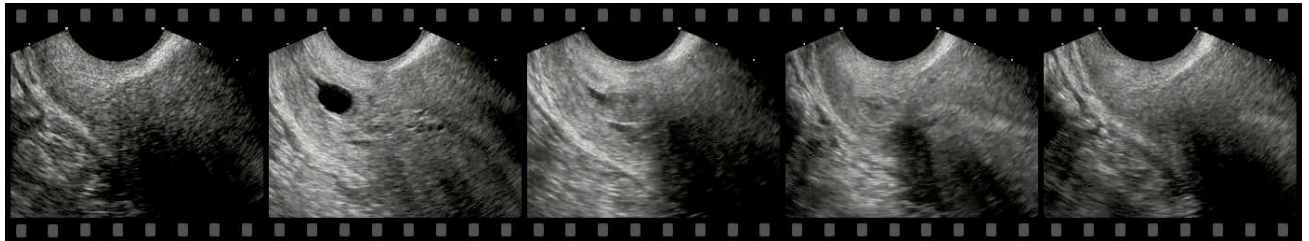The identification of cervical ectopic pregnancies is important since uterine aspiration without proper preparation can result in massive hemorrhage. Any pregnancy seen to lie within the cervix should be referred for further evaluation in a hospital setting. Uterine aspiration should not be performed. In some circumstances, it can be difficult to distinguish between a spontaneous abortion in progress and a cervical ectopic. In rare cases, cardiac motion has been demonstrated in a pregnancy in the cervix and vagina. However, in either case, uterine aspiration is not indicated.

Case 1



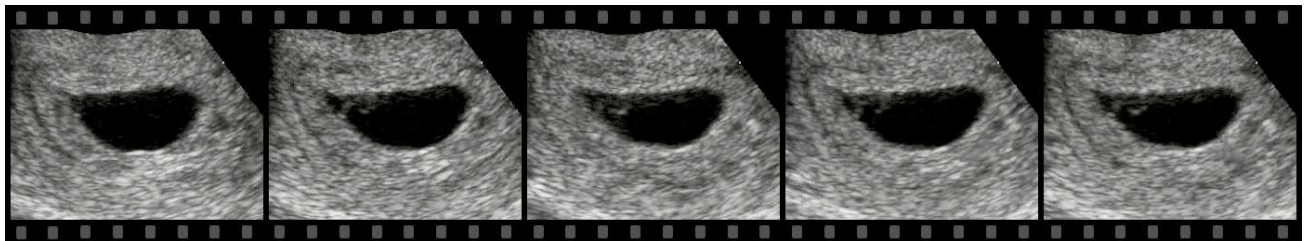Cervical ectopic with free fluid

Case 2



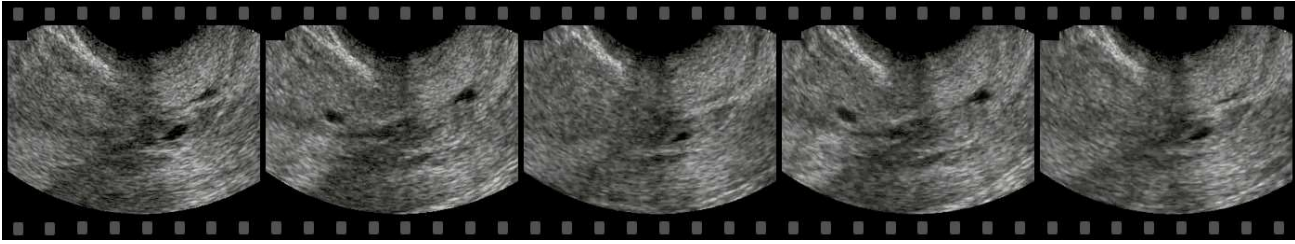
Cervical ectopic in a retroverted uterus: longitudinal view of uterus and cervix

Case 2 demonstrates the typical pattern of vascular flow seen around a cervical ectopic without Doppler. Doppler interrogation confirmed that the pregnancy was implanted in the cervix.



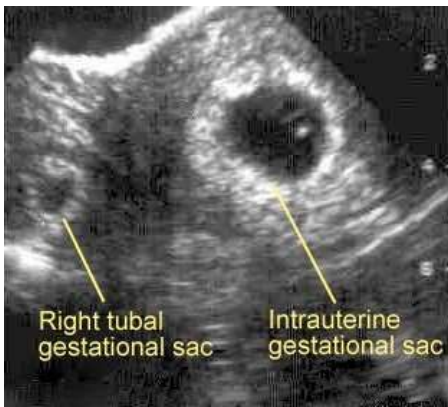
Cervical ectopic in a retroverted uterus: transverse view of cervix

Case 3



Early cervical ectopic pregnancy

7.15: Heterotopic Pregnancy

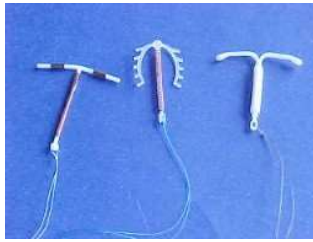


www.webmm.ahrq.gov/case.aspx?caseID=43

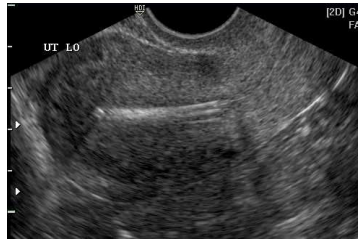
Heterotopic pregnancy refers to the simultaneous existence of an intrauterine pregnancy AND an ectopic pregnancy. The obvious opportunity for missing the diagnosis is visualizing an intrauterine pregnancy and missing the ectopic pregnancy. This condition is rare, ranging from about 1 in ten thousand pregnancies in the general population, but is increased to nearly 100 in ten thousand or 1% when a woman has conceived using assisted reproductive technology (ART).

Since the use of ART is very unusual among women seeking termination of pregnancy, heterotopic pregnancies are extremely rare in the setting of abortion care. This image shows a case of heterotopic pregnancy.

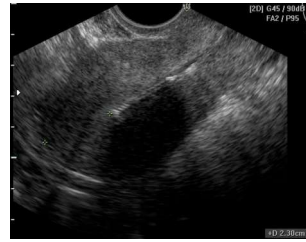
7.16: Intrauterine Contraceptive System Within the Uterus



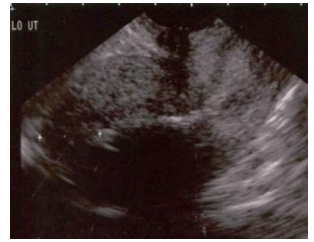Three common IUDs - the CuT380a, Multiload & Mirena



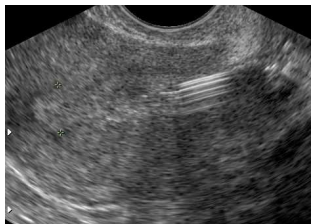Normally-situated Mirena



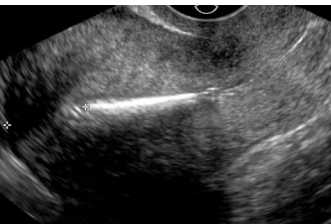Normally-situated Mirena



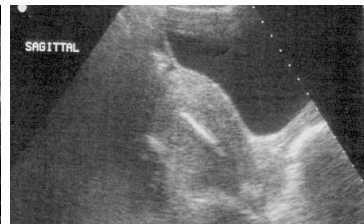Normally-situated Mirena but poorly imaged



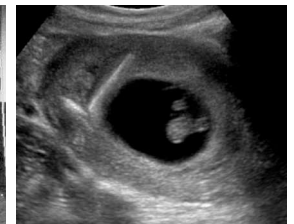Mirena in the lower uterine segment



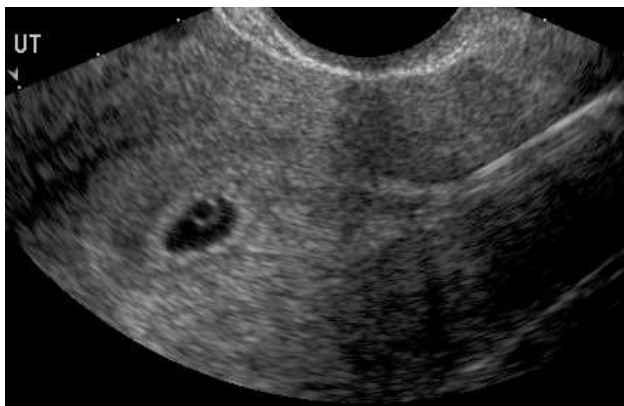Normally-situated copper IUD



Copper IUD properly situated within the uterus



Copper IUD with an intrauterine pregnancy



Mirena in the cervix with an intrauterine pregnancy

The efficacy of the intrauterine contraceptive system equals that of tubal sterilization, so method failure is rare when an IUD is in place. However, if a pregnancy occurs while using an IUD or tubal sterilization, the risk of an ectopic pregnancy is higher. If a patient is pregnant with an IUD, the location of the IUD should be determined as well as the location of the pregnancy. Commonly, the IUD is not normally situated in the fundus if a pregnancy has occurred.

These images show some common types of IUDs. The Mirena IUD is often difficult to image on ultrasound. If it cannot be seen, a radiograph should be considered. Copper IUDs produce

bright echoes that are easily identified on ultrasound. From left to right, the first image shows the Paragard CuT380a, the Multiload 375, and the Mirena levonorgestrel-releasing IUD. The Multiload is not approved for use in the U.S. but is one of the most commonly encountered IUDs among women coming to the U.S. The last two images show intrauterine pregnancies with IUDs in place. The same steps to verify that the pregnancy is intrauterine should be performed as if the IUD were not present.

7.17: Pseudosac in Ectopic Pregnancy

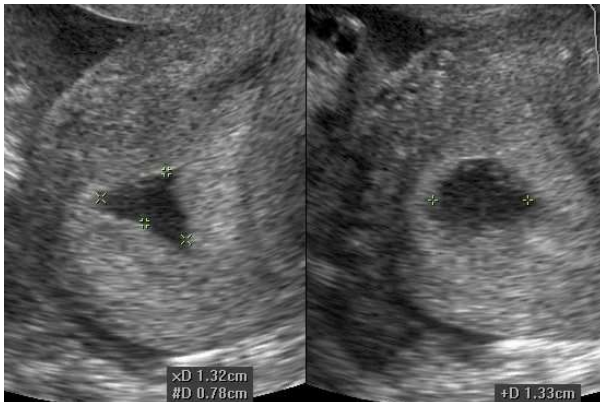
Gestational sac	Pseudosac
Round or elliptical in all planes	May not be round or elliptical in all planes
Double decidual sign	Single layer of decidia
Eccentric to the midline	May be midline in uterine cavity
May have embryonic structures	No embryonic structures

Not all cases of ectopic pregnancy exhibit an empty uterus. In some cases of ectopic pregnancy, the uterus contains a fluid accumulation that can be confused with an early gestational sac. The secretions of the decidua may produce a fluid collection in the endometrial cavity known as a pseudogestational sac or "pseudosac." A pseudosac can be small or large. Approximately 20% of patients with ectopic pregnancy have a pseudosac visualized on ultrasound scanning.

The table shows the characteristics of a true gestational sac and those of a pseudosac. In practice, it can sometimes be challenging to

distinguish a pseudosac from a gestational sac.

7.18: Pseudosac in Ectopic Pregnancy

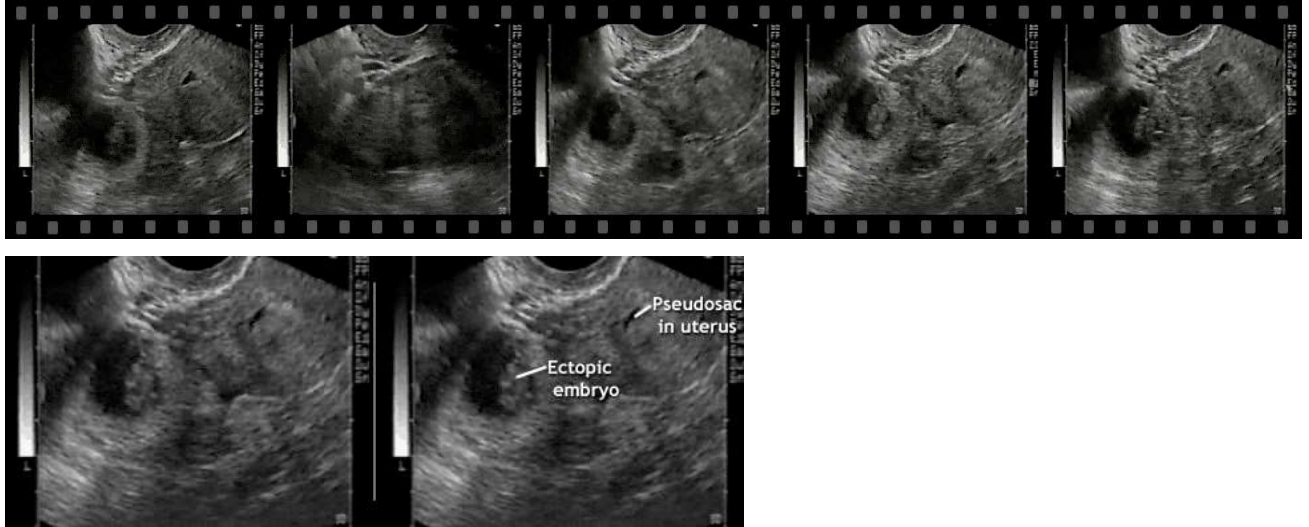


This pseudosac does not have a normal echogenic rind of chorionic villi. This image shows a pseudosac within the uterus in a patient who had an ectopic pregnancy. Note the single layer of decidia surrounding the pseudosac, its central placement within the uterus, its irregular shape, and lack of embryonic structures.

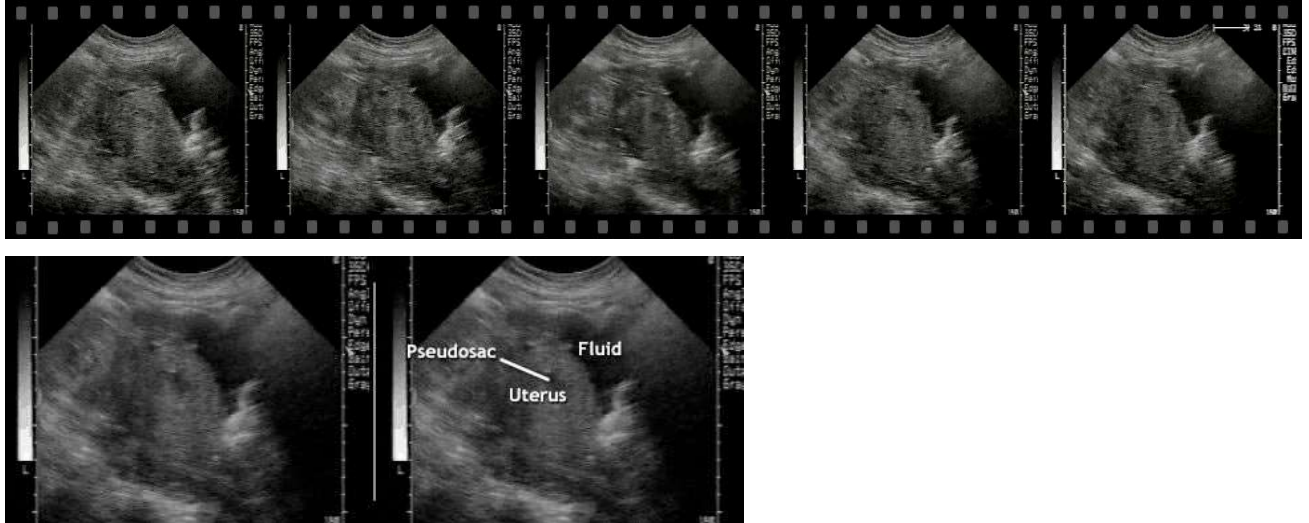
7.19: Ectopic Pregnancy Cases: Pseudosac Within the Uterus

These images and video frames show examples of a pseudosac within the uterus.

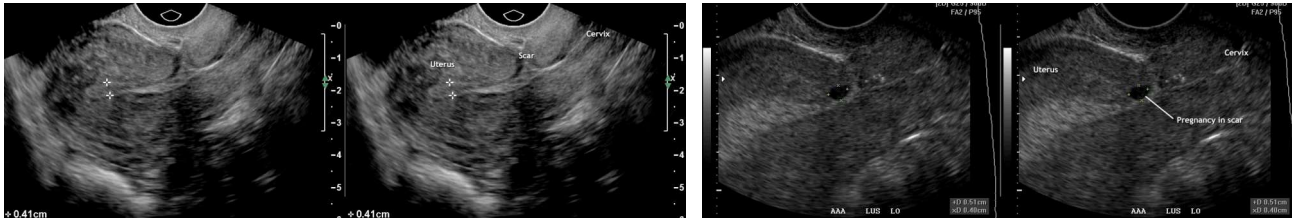
Case 1



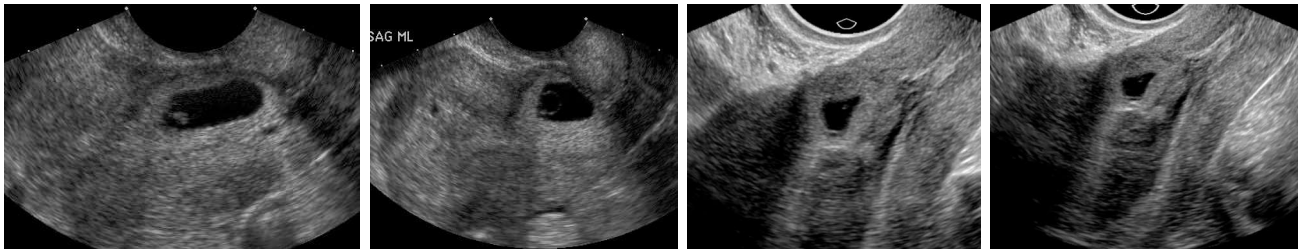
Case 2



7.20: Cesarean Scar Ectopic Pregnancy

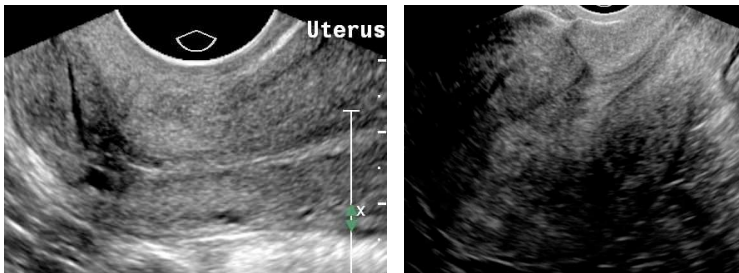


Prominent Cesarean section scar in a non-pregnant uterus



Ectopic pregnancy in Cesarean section scar

Ectopic pregnancy in Cesarean section scar

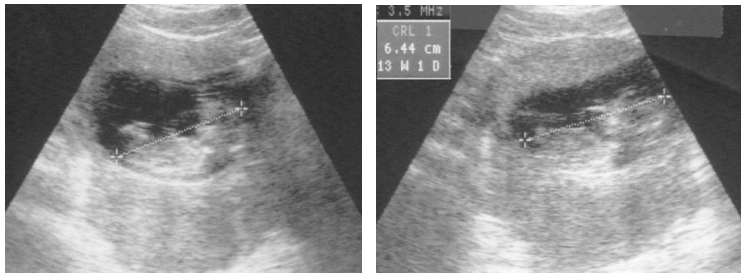


Prominent Cesarean section scar in a retroverted non-pregnant uterus

Prominent Cesarean section scar in a non-pregnant uterus

Rarely, the pregnancy may implant within a Cesarean section scar. A pregnancy in a Cesarean section scar should be considered as a form of ectopic pregnancy. It can lead potentially to rupture of the myometrium with severe bleeding or may evolve into placenta accreta. Uterine aspiration without proper preparation should not be attempted. The images show early pregnancies implanted with Cesarean section scars. The last three images show prominent cesarean section scars in the lower uterine segment.

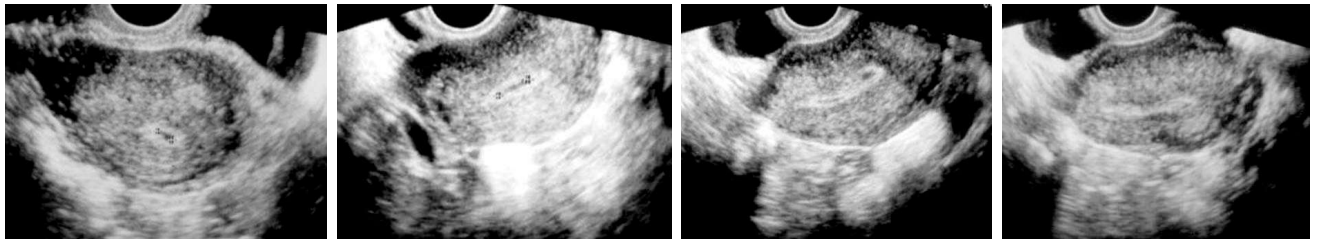
7.21: Clinical Case #1



This asymptomatic patient presented for surgical abortion at 13 weeks LMP. The procedure was started, but no tissue obtained. The physician repeated the scan and diagnosed an ectopic pregnancy. During laparotomy, the pregnancy was found contained within the fallopian tube. This case illustrates the fact that ectopic pregnancy can progress to relatively late gestational

ages and be asymptomatic. Note that the outlines of the uterus are not seen; the pregnancy is not within the uterus.

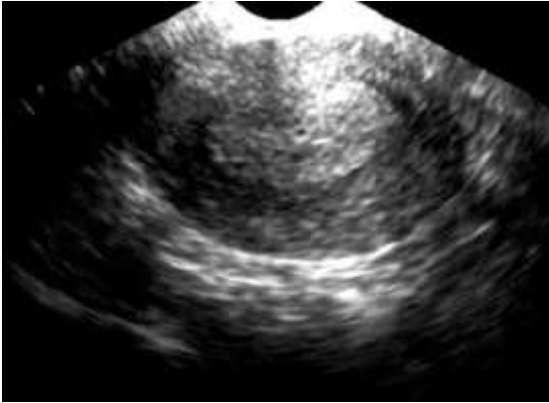
7.22: Clinical Case #2



This patient was found to have what was believed to be a gestational sac. These images were taken from multiple views. In the first view, there is a thin homogeneous ring of echogenic tissue, not the double decidual sign that should surround a normal gestational sac. In addition, the sac is directly midline in the endometrium, not eccentric to the midline. In the first view, the sac appeared to be oval, but it is not round in further views 2, 3, and 4. The patient subsequently developed pain and spotting and had diagnostic laparoscopy, revealing bilateral ectopic pregnancies. The ectopic pregnancies are not apparent on the views presented here, but the intrauterine findings do not allow the diagnosis of an intrauterine gestation to be made and are suspicious for a "pseudosac" which should prompt consideration of ectopic pregnancy.

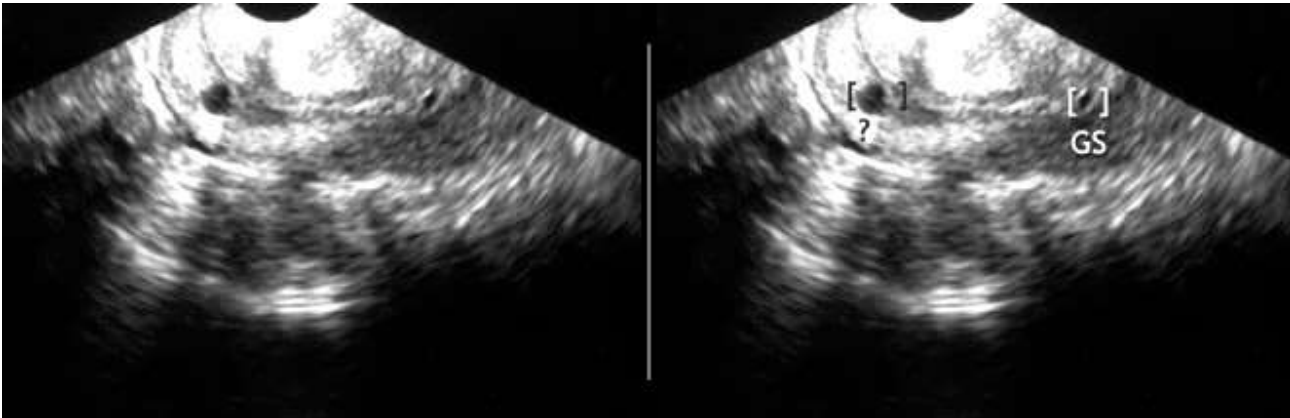
7.23: Clinical Case #3

Views 1 & 2



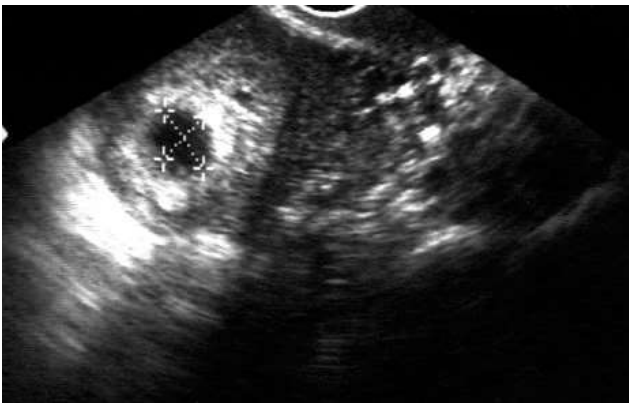
View #1: Tiny gestational sac

This patient was found to have what was perhaps a tiny gestational sac in the uterus as seen in view #1 but also a fluid-filled sac in the cervix as seen in view #2. The abortion provider was concerned that the cervical fluid collection might be a cervical ectopic pregnancy.



View #2: Transvaginal scan of retroverted uterus; GS = gestational sac, ? = ? sac in cervix

Views 1 & 3



View #3: Uterus one week later containing gestational sac.

A week later a clinician inserted a speculum and she could see large Nabothian cysts behind the epithelium (surface layer) of the cervix. At that visit, the gestational sac had grown as expected (about 1 mm/day) as seen in view #3. A Nabothian cyst is small round simple cyst which will not have the feature typical of a cervical ectopic. Nabothian cysts are normal. Specifically, Nabothian cysts lack the echogenic ring, created by chorionic villi. Usually, multiple Nabothian cysts are present throughout the cervix on real-time sonographic examination.

8.1: Usefulness of Sonographic Guidance

Situations in which sonographic guidance may be useful:

- Retroverted uterus
- Bicornuate uterus
- Uterine fibroids

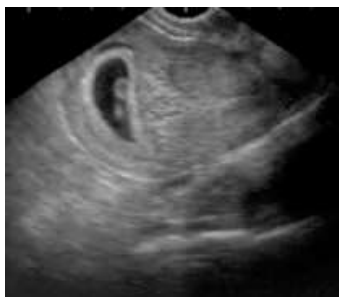Intra-operative sonographic guidance may be useful during surgical abortion, particularly when a retroverted uterus, a bicornuate uterus, or uterine fibroids are present. Ultrasound may be used to guide the suction cannula to the uterine fundus and the gestational sac. It can also be used to observe the removal of the gestational sac and to assess the completeness of the evacuation. Ultrasound guidance may also be useful in other complicated cases, such as when no products of conception are identified after an initial surgical abortion or when false passages have been created. Ultrasound guidance may be useful in general for all dilation and evacuation procedures, as

discussed in detail in Chapter 12.

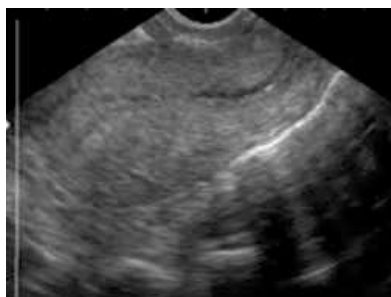8.2: Sonographic Appearance of the Uterine Cavity After Surgical Abortion

In the event that no products of conception are identified after a surgical abortion, a sonographic evaluation of the uterus immediately after the abortion is often helpful. Some providers routinely perform a pre- and post-evacuation sonogram for pregnancies at 6 weeks or less. In most situations, the completeness of uterine evacuation can usually be determined based upon uterine texture and examination of the products of conception. If there is concern that the evacuation was not complete, ultrasound may be a quick and useful next step in evaluating the completeness of the evacuation. The sonographic appearance of the uterine cavity immediately after surgical abortion should show a thin endometrial stripe. If not performed immediately after the procedure, the appearance of the endometrial stripe varies widely. If no products of conception are identified, it is important to keep ectopic pregnancy in the differential diagnosis, particularly if an intrauterine pregnancy was not definitively diagnosed by ultrasound prior to the surgical abortion. These cases show the appearance of the uterus immediately after surgical abortion, with the pre-procedure sonogram for comparison.

Case 1

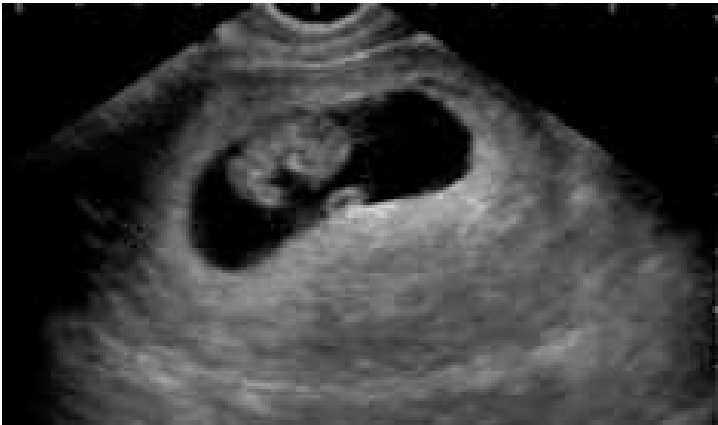

Before procedure

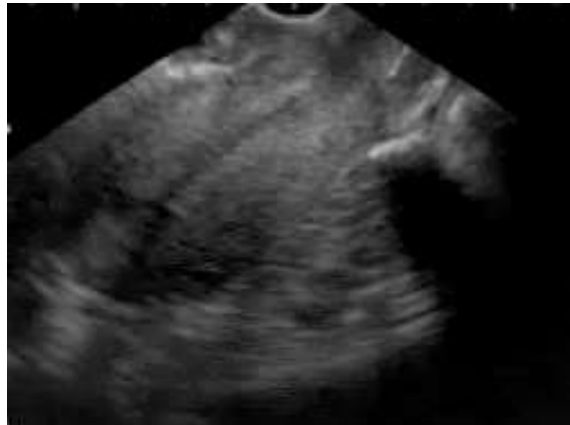


After procedure

Case 2

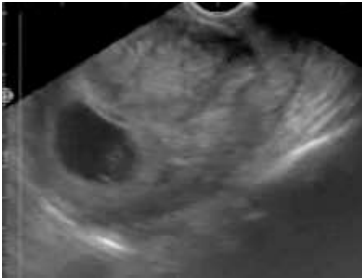


Before procedure

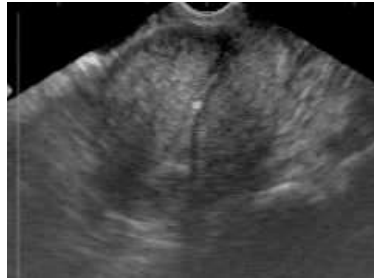


After procedure

Case 3

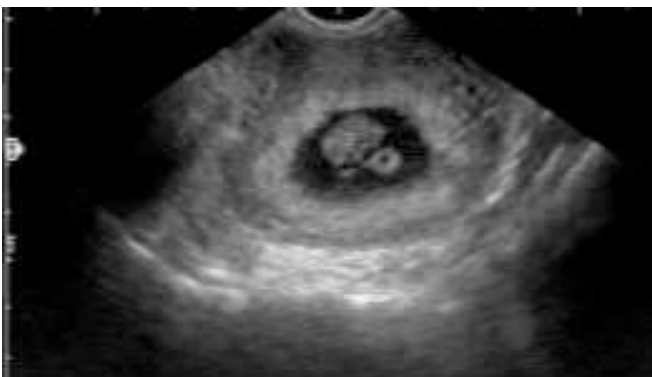

Before procedure

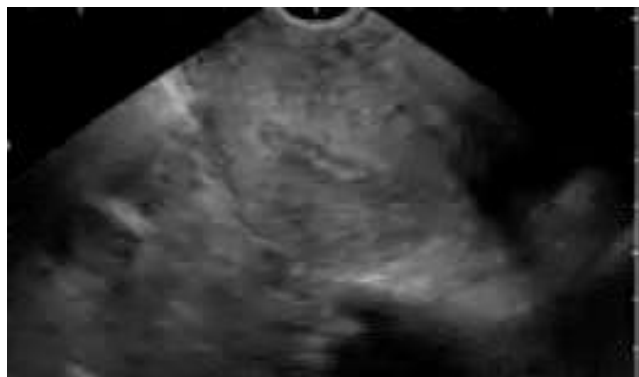


After procedure

Case 4

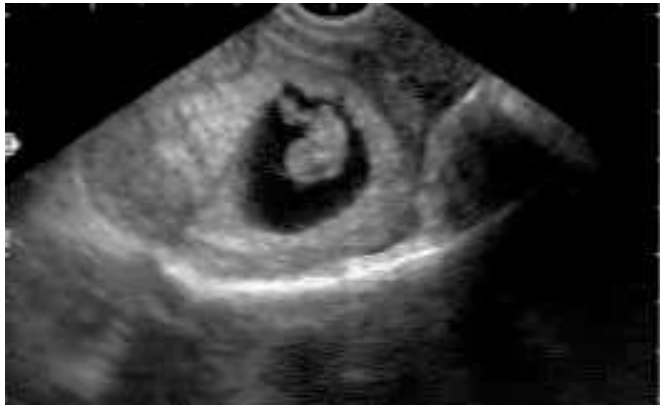

Before procedure

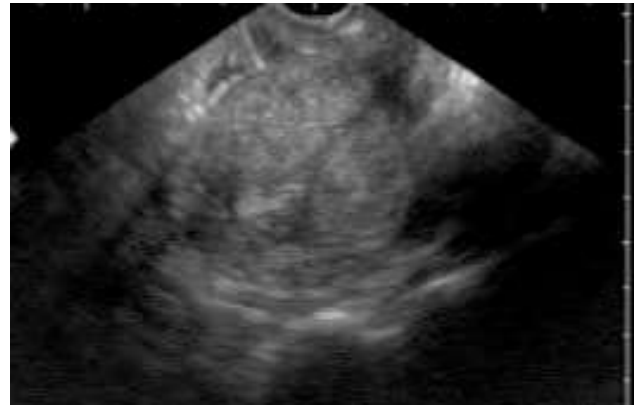


After procedure

Case 5

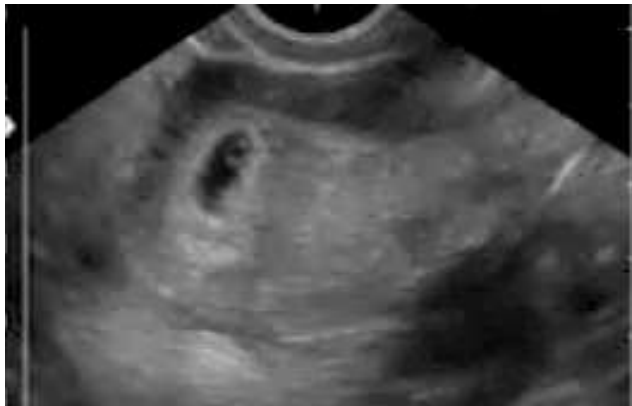

Before procedure

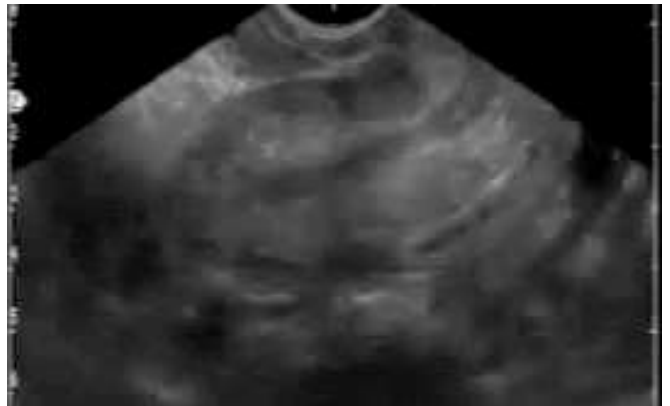


After procedure

Case 6

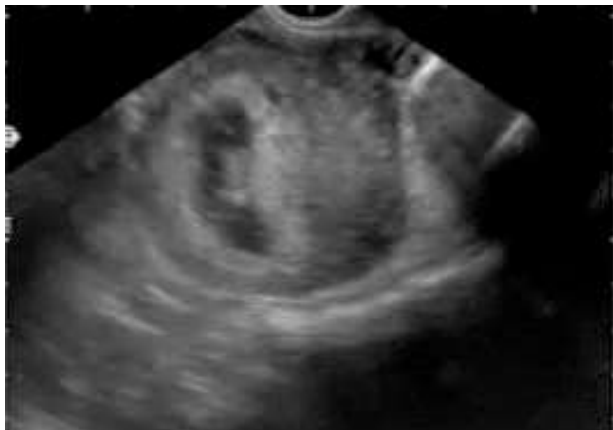

Before procedure

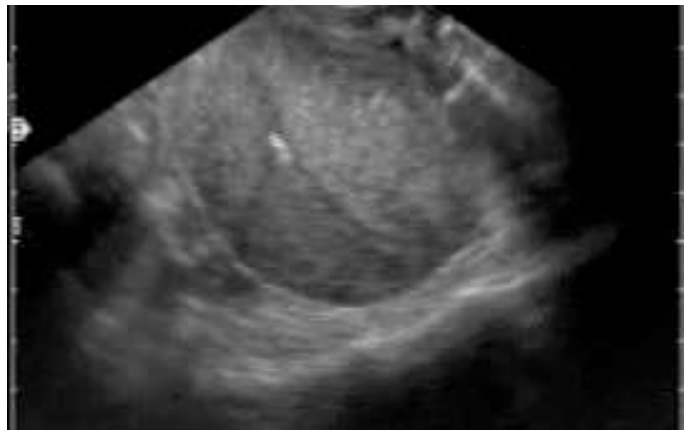


After procedure

Case 7

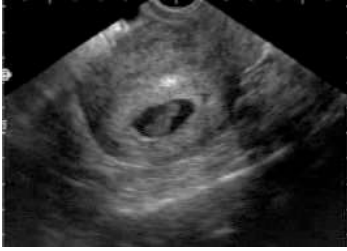

Before procedure

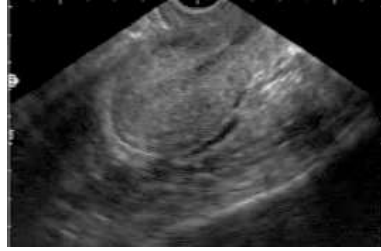

After procedure

Case 8

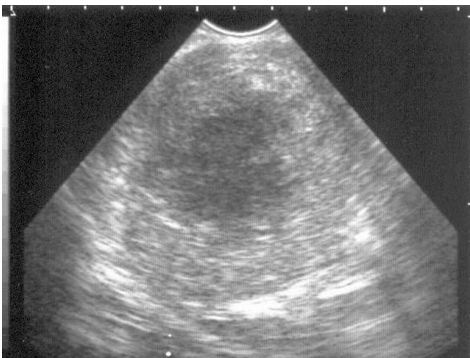


Before procedure

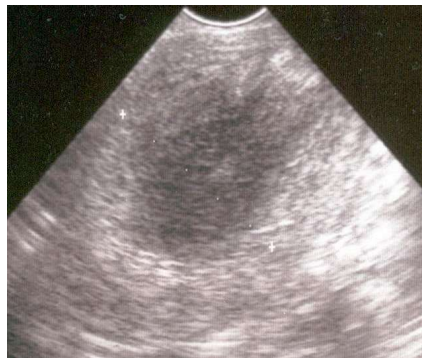

After procedure


8.3: Postabortal Hematometra



Transverse transabdominal scan



Longitudinal transabdominal scan

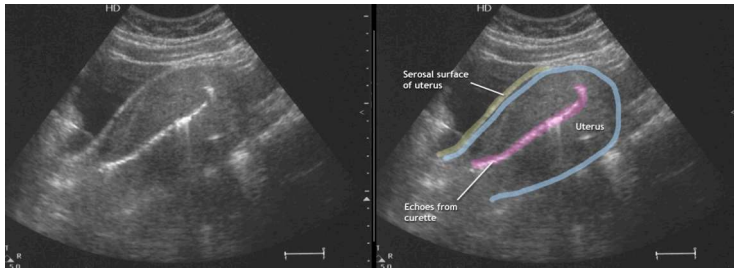


Pan of evacuated clotted blood

Hematometra occurs when accumulated clot and blood become trapped within the uterine cavity. It is also referred to as postabortal syndrome. These images show the sonographic appearance of a large hematometra. In this case, the endometrial "thickness" measures roughly 5 centimeters. The photograph shows the clotted blood that was evacuated.

The clinical presentation of hematometra is usually easily diagnosed even without ultrasound. Typically, the patient experiences low midline pelvic pressure and pain as soon as 15 minutes but up to several hours after the procedure. Patients may experience little to no bleeding or intermittent expulsion of maroon-colored clots. Upon physical examination the uterus is enlarged, tense and tender; sometimes it is larger in size than it was prior to the procedure. The diagnosis is made clinically and ultrasound merely serves to confirm the diagnosis, as was the case with the example shown here. Uterine aspiration provides rapid relief of the symptoms. Occasionally cervical dilation is sufficient to allow the uterine contents to be expelled.

8.4: Uterine Perforation



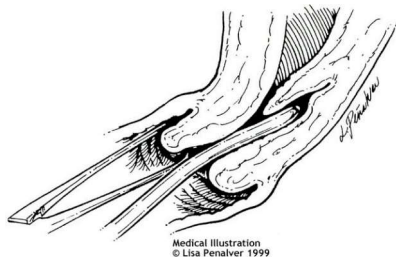
Sharp curette at fundus

Uterine perforation is a potentially serious complication that may be subtle or obvious. Sighting of bowel or omentum in the cannula or the cervix are obvious signs of perforation that deserves emergent care, with no need for ultrasound. Suspicion of perforation arises when instruments pass further than expected, often without discernible resistance or when the gritty surface of

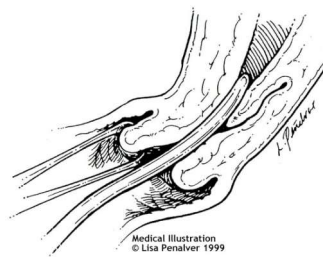
the endometrium is lost during aspiration or curettage. If sonographic guidance is being used, a perforating instrument may be seen extending beyond the serosa of the uterus. In all cases, if perforation is suspected, the instrument should be removed immediately. If ultrasound guidance is not already being used, the instrument should not be left in place so that ultrasound can be used to confirm the perforation.

If perforation is suspected, monitoring for accumulation of blood in the abdomen and pelvis may be useful. The appearance of intra-abdominal blood will be similar to that seen with an ectopic pregnancy.

8.5: False Passage



A passage is created in the upper portion of the cervix. If this tract is extended, perforation can result.



The dilator is withdrawn, the cervix is straightened by firmer traction, and the dilator is redirected properly. Continued traction on the cervix helps compress the blind passage.

The provider may create a "false passage" that burrows into the stroma of the cervix instead of following the cervical canal. Ultrasound guidance can often identify the cervical canal and allow the instrument to be guided back into the proper course. A false passage may also start in the lower uterine segment and extend into the myometrium, particularly during second-trimester abortion.

9.1: Introduction



Since the introduction of mifepristone in the United States in the year 2000, medication abortion has become an important option for women choosing to terminate an early pregnancy. In the U.S., ultrasound prior to medication abortion is routine at many clinics.

However, use of ultrasound was not required by the FDA as part of the approval of mifepristone. Ultrasound is not required or routinely employed in many countries of the world and in some U.S. settings.

There are two commonly used methods for evaluating the success of medication abortion. The most commonly used method in the United States is transvaginal ultrasound, but serum beta-hCG testing is also a good option.

9.2: The Use of Ultrasound in Medication Abortion



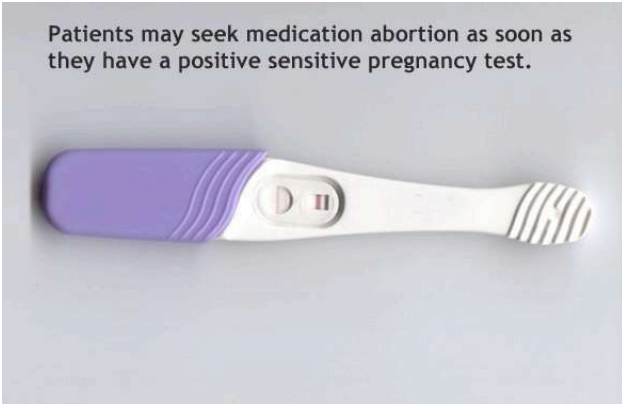Ultrasound is useful for verifying gestational age before initiation of medication abortion and for confirming successful expulsion of the pregnancy at the follow-up visit.

Ultrasound is commonly used to verify the gestational age of the pregnancy prior to starting the medication abortion. This initial ultrasound then serves as a basis for comparison with subsequent sonograms. Absence of the previously identified intrauterine pregnancy at the follow-up visit serves to confirm successful expulsion of the pregnancy.

9.3: Medication Abortion in Very Early Pregnancy



Patients may seek medication abortion as soon as they have a positive sensitive pregnancy test.



Patients may seek medication abortion as soon as they have a positive sensitive pregnancy test. However, it may be too early to see a pregnancy, even with a transvaginal ultrasound.

When no intrauterine pregnancy is seen on ultrasound and the sensitive urine pregnancy test is positive, careful assessment and follow-up are required. If the patient is less than 5 weeks by last menses, it is most likely that the pregnancy is too small to visualize with ultrasound, but it is also possible that the patient is having an early pregnancy loss or that the pregnancy is ectopic.

Mifepristone and misoprostol do not treat an ectopic pregnancy and should not be given when ectopic pregnancy is suspected.

Patients in very early pregnancy may receive medication abortion even when the pregnancy is so early that it can't be visualized by ultrasound. In this case, the patient is followed with serum beta hCG testing. This alternate follow-up will be discussed at the end of the chapter.

9.4: Ultrasound To Evaluate The Success of Medication Abortion



The purpose of the ultrasound following medication abortion is to determine if the patient is still pregnant.

When using ultrasound to evaluate the success of medication abortion, a follow-up ultrasound is usually performed one to two weeks after initiation of the medication abortion. The purpose of the ultrasound following medication abortion is to ensure that the patient no longer has a continuing pregnancy. The goal of medication abortion is to end the pregnancy, not to achieve an "empty" uterus. After medication abortion, it is common to see heterogeneous debris in the endometrial cavity. This residual endometrial tissue, blood and clot are normal and will be expelled over time.

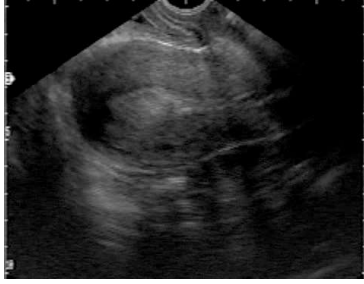
9.5: The Uterus After Medication Abortion



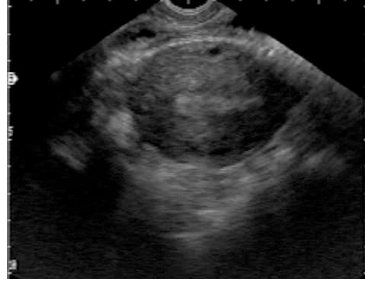In successful medication abortion, thickened endometrium with heterogeneous uterine contents is a common finding, but the gestational sac should no longer be apparent. The decision to intervene with uterine aspiration should not be based on endometrial thickness. Intervention should be based on the patient's symptoms, not endometrial thickness. The endometrial thickness after successful medication abortion ranges from 1mm to over 3 centimeters. However, it is not necessary or clinically useful to measure the endometrial thickness.

The cases shown here are examples of successful medication abortion. In all five cases, an intrauterine gestation was identified before the medication abortion regimen was begun.

Case 1

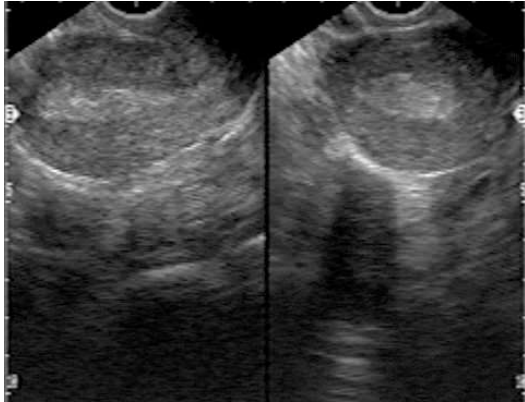


Case 1; longitudinal view



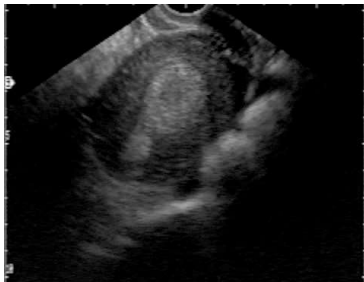Case 1; transverse view

Case 2

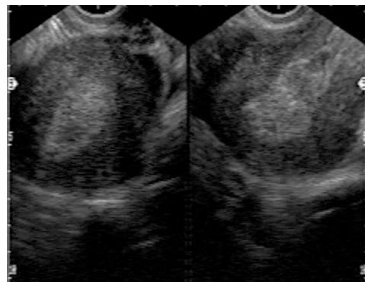


Case 2; longitudinal and transverse views

Case 3

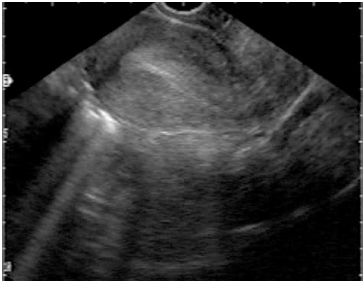


Case 3; oblique view

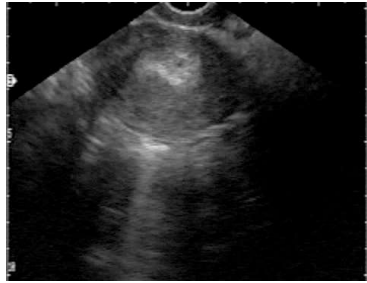


Case 3; transverse and longitudinal views

Case 4

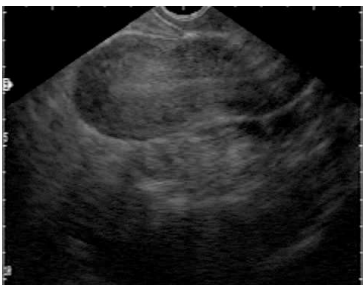

Case 4; longitudinal view

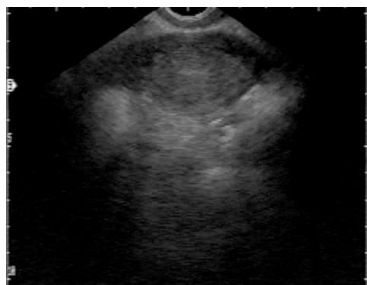

Case 4; transverse view

Case 5

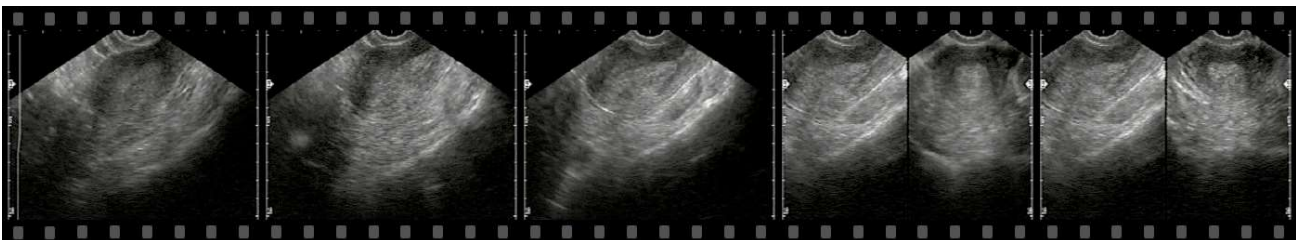


Case 5; longitudinal view



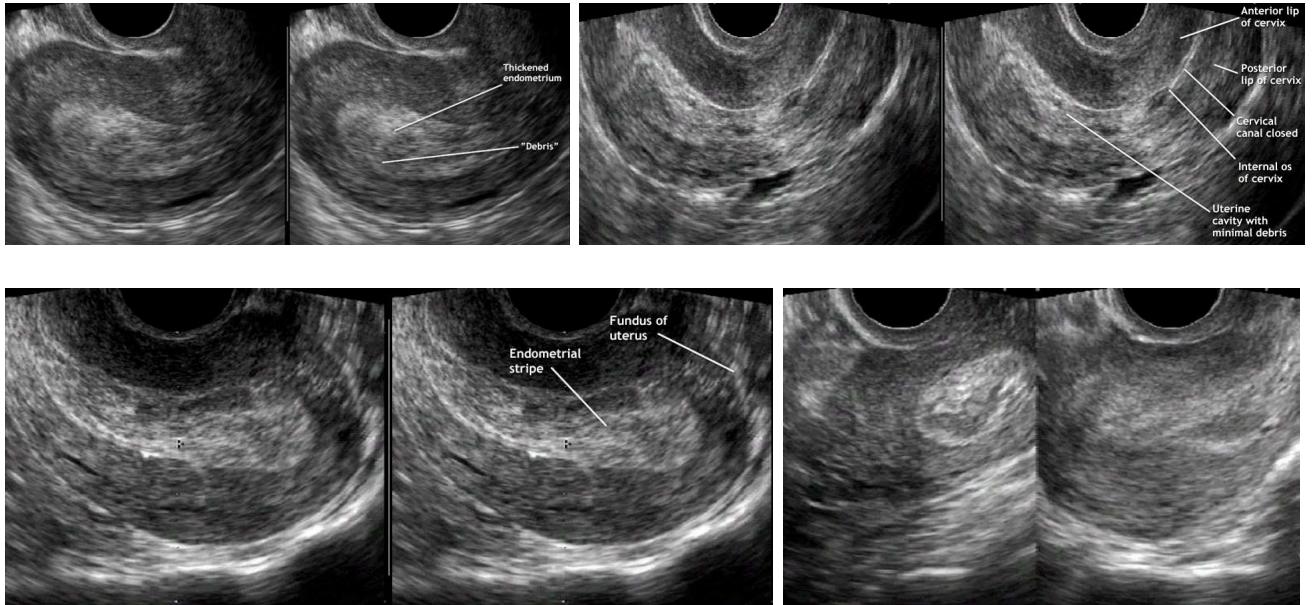
Case 5; transverse view

9.6: Ultrasound Assessment After Medication Abortion



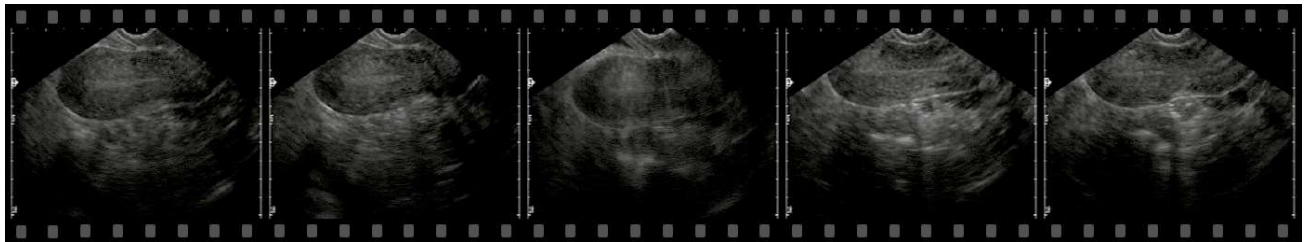
These video frames show the longitudinal and transverse scan of the uterus after a successful medication abortion.

9.7: Ultrasound Assessment After Medication Abortion



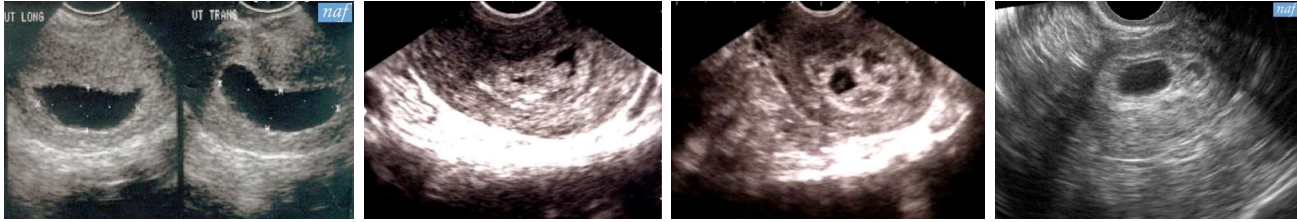
These are more images of the normal variation in post-medication abortion ultrasound.

9.8: Variation in Endometrial Thickness After Medication Abortion



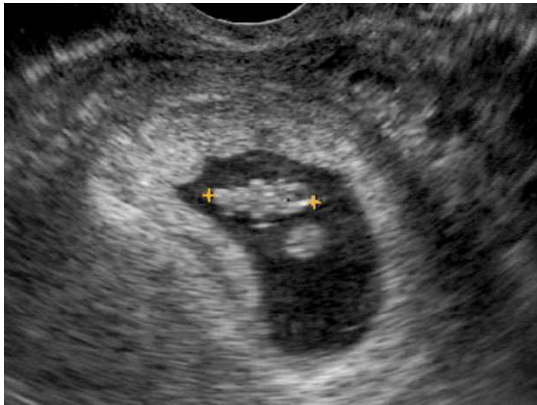Occasionally, the endometrium is very thin after medication abortion as seen here. The patient's clinical condition, not the thinness or thickness of the endometrium, should guide judgment about whether intervention is indicated. These video frames demonstrate a patient with a thin endometrium in the longitudinal plane.

9.9: Retained Gestational Sac After Medication Abortion



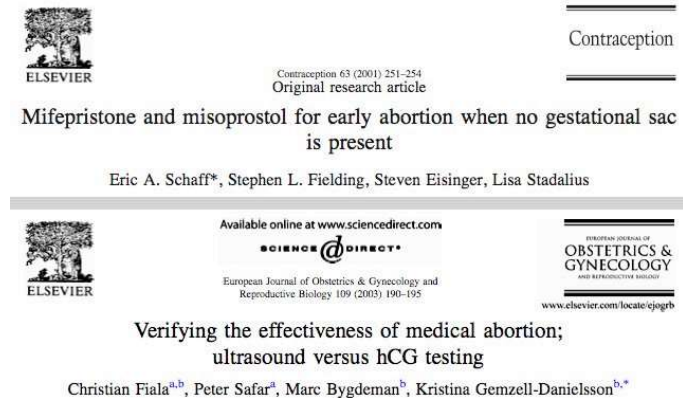
The gestational sac may no longer have embryonic structures visible or it may be collapsing. Often the chorionic villi will lose their echogenic appearance, like an early pregnancy failure. The gestational sac may be surrounded by heterogeneous debris composed of decidua, blood, and clots. Once a retained gestational sac is identified, medication abortion protocols vary in how this situation is handled. Planned Parenthood protocols allow a range of treatment for retained gestational sac if the patient is clinically normal. The options are: 1) wait and watch for 42 days with the expectation that the sac will be expelled with the first menses, 2) administer a second dose of misoprostol and 3) uterine evacuation.

9.10: Continuing Pregnancy After Medication Abortion



Rarely, patients have an ongoing pregnancy after medication abortion. Once a continuing pregnancy is identified, medication abortion protocols vary in how this situation is handled.

9.11: Following Medication Abortion with Serum Beta hCG



It may be a relief for some women to have a very early abortion. The patient may be eligible for medication abortion even if no gestational sac is seen on transvaginal ultrasound under the following conditions: the patient is asymptomatic, the beta-hCG is less than 2000 mIU (or a urine pregnancy test with a sensitivity of 2000 mIU test is negative), she has no risk factors for ectopic pregnancy and is willing to comply with the additional serum beta hCG follow-up testing. Studies have shown that there's no "too early" for medication abortion. A beta hCG can be drawn on the same day that the

mifepristone is given. The quantitative beta hCG is re-tested in 2-14 days after misoprostol. One can determine from the pattern of hCG fall if the medication abortion was successful.

Two references are provided here that explain how to provide medication abortion to women when the pregnancy is too early to visualize by ultrasound. These references discuss following serum beta hCGs to assess the progress of medication abortion.

9.12: Following Medication Abortion with Serum Beta hCG

Following drop in beta hCG is as accurate as, and in some cases more accurate than ultrasound in determining success of medication abortion.

Beta hCG follow-up may also be very useful when patients travel long distances or in bad weather conditions to receive medication abortion. Medical center protocols may allow the patient to be followed with beta hCG testing instead of returning for an ultrasound. In this case, a serum beta hCG is drawn on Day One and the patient has a second beta hCG drawn in a laboratory near her home in about a week. If the second beta hCG dropped to 20% or less of the original beta hCG, and the patient is not experiencing problematic symptoms, a return trip for an exam at the health center is not necessary.

9.13: References



This is a list of references used in this chapter.

Banerjee, S., Aslam, N., Zosmer, N., Woelfer, B., and Jurkovic, D. (1999). The expectant management of women with early pregnancy of unknown location. Ultrasound in Obstetrics and Gynecology, *14*, 231-236.

Barnhart, K.T., Sammel, M.D., Rinaudo, P.F., Zhou, L., Hummel, A.C., and Guo, W. (2004). Symptomatic patients with an early viable intrauterine pregnancy: hCG curves redefined. Obstetrics and Gynecology, *104* (1), 50-55.

Barnhart, K.T., Simhan, H., and Kamelle, S.A. (1999). Diagnostic accuracy of ultrasound above and below the beta-hCG discriminatory zone. Obstetrics and Gynecology, *94* (4), 583-587.

Callen, P.W. (2000). Ultrasonography in Obstetrics and Gynecology (4th ed.). Philadelphia: W.B. Saunders Company.

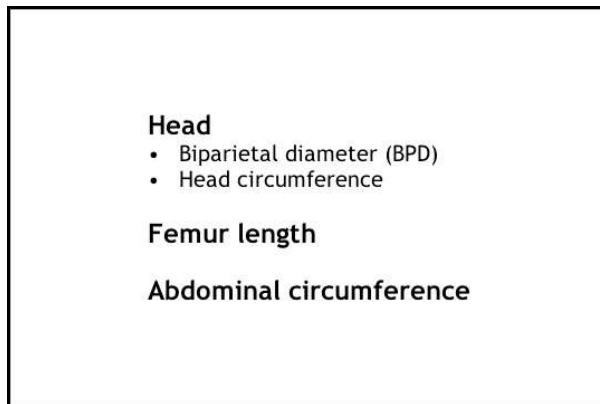
Cowett AA, Cohen LS, Lichtenberg ES, Stika CS. Uterine evaluation of the endometrium after medical termination of pregnancy. Obstetrics & Gynecology 2004; *103*(5): 871-875.

Fiala, C., Safar, P., Bygdeman, M., and Gemzell-Danielsson, K. (2003). Verifying the effectiveness of medical abortion; ultrasound versus hCG testing. European Journal of Obstetrics & Gynecology and Reproductive Biology, *109* (2003), 190-195.

Paul, M., Schaff, E., and Nichols, M. (2000). Early medical abortion: the roles of clinic assessment, human chorionic gonadotropin assays, and ultrasonography in medical abortion practice. American Journal of Obstetrics and Gynecology, *183*(2).

Schaff, E.A., Fielding, S. L, Eisinger, S., and Stadalius, L. (2001). Mifepristone and misoprostol for early abortion when no gestational sac is present. Contraception *63*, 251-254.

10.1: Advanced Module 1 Introduction



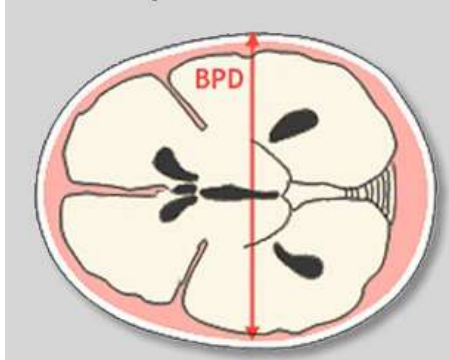
In early pregnancy, mean gestational sac diameter and embryonic crown-rump length are the sonographic measurements used to determine gestational age. The proper techniques for making those measurements were discussed and practiced in Chapter 5.

After about 12 weeks, different structures including the head, femur and abdomen are used to determine gestational age. In this chapter, you will be introduced to the principles of making these measurements and have a chance to practice making them. To reduce error in assessing gestational age, multiple measurements should be

taken and they should be compared for consistency before assigning gestational age. Allowing your ultrasound machine to combine the different measurements will give you a composite gestational age. Most ultrasound machines use the Hadlock formulas to do this.

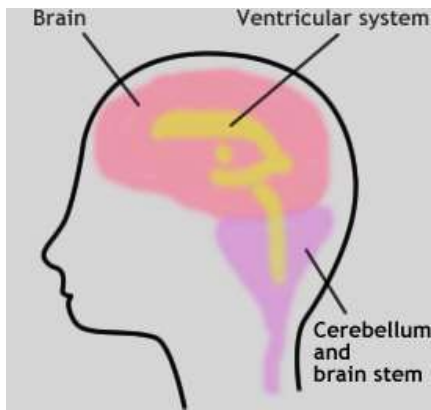
10.2: Biparietal Diameter (BPD) Measurement

BPD = Biparietal Diameter



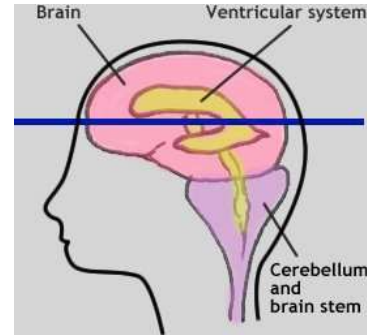
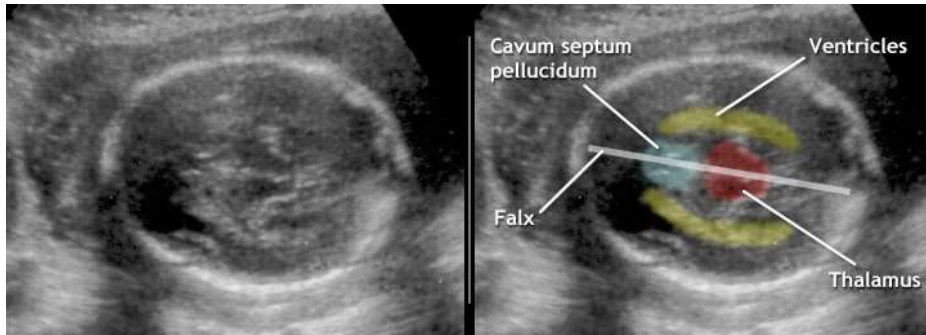
During the second trimester and thereafter, several measurements are made including at least the head and femur. The head measurement most commonly used in second trimester ultrasound is the biparietal diameter, BPD.

10.3: Fetal Head Diagram for BPD Measurement



To be sure that the BPD is measured correctly, an image containing several specific landmarks must be used. Those landmarks are structures within the fetal brain. This diagram shows the fetal brain, cerebellum and brainstem, and ventricular system that contains the spinal fluid.

10.4: Correct Level for BPD Measurement

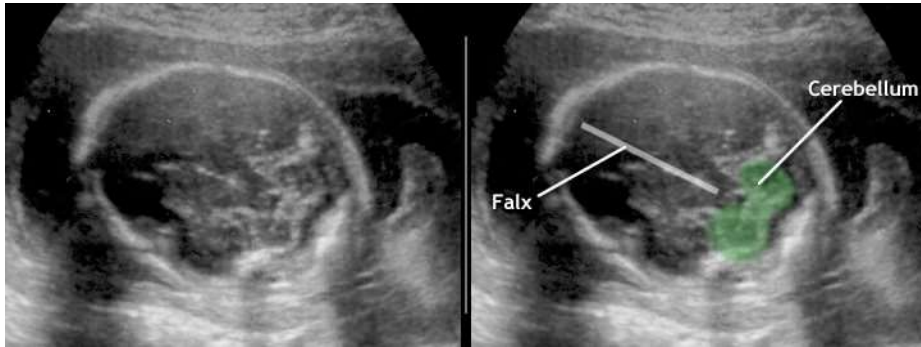


Sonogram at correct plane for measuring BPD

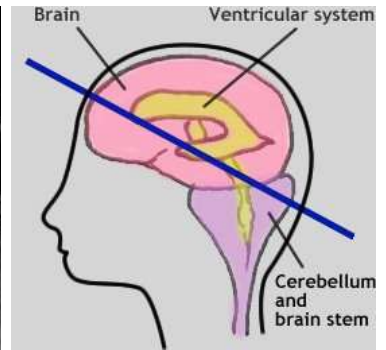
Correct plane for measuring BPD

In the diagram on the right, the line shows the level of the fetal head that must be imaged for correct measurement of the BPD. The sonogram on the left shows the landmarks at this level, including the thalamus, cavum septum pellucidum, falx and ventricles. This same level is used to measure the head circumference.

10.5: Incorrect Level for BPD Measurement



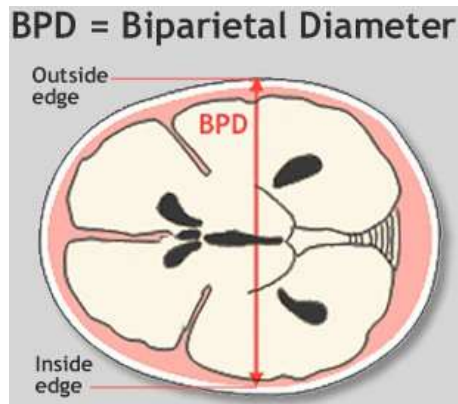
Sonogram at incorrect plane for measuring BPD



Incorrect plane for measuring BPD

If the image level is tipped down into the back of the head as shown in the diagram on the left, the cerebellum will come into view as seen on the right. The falx is present, but the other landmarks are not. This is NOT the right level at which to measure the BPD and head circumference.

10.6: Correct Caliper Placement for BPD Measurement

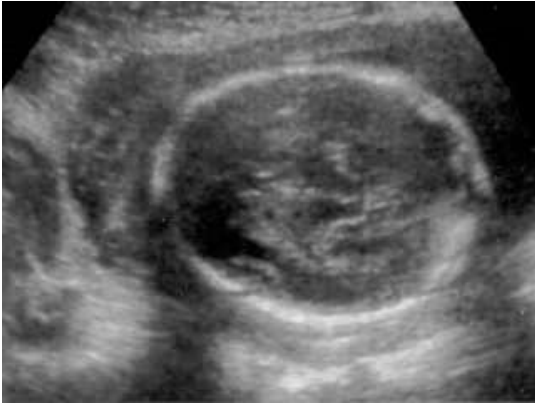

The BPD is measured from the OUTSIDE of the fetal skull edge nearest the transducer to the INSIDE of the fetal skull edge farthest from the transducer.

10.7: Practice Measuring: BPD

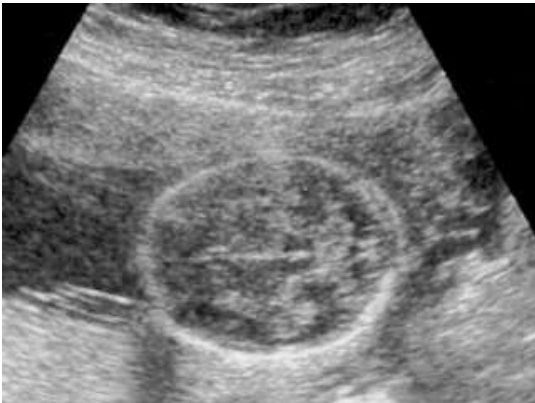
Practice measuring the BPD on these images. The answer key is at the back of the workbook.

Case 1

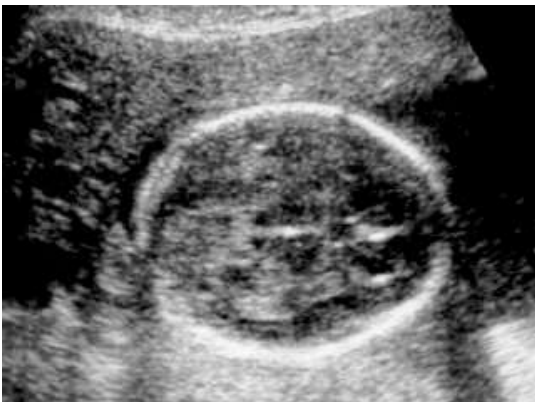

Mark where to set the calipers or imagine where to set the calipers and measure the BPD. Be sure to measure from the OUTSIDE of the fetal skull edge nearest the transducer to the INSIDE of the fetal skull edge farthest from the transducer.

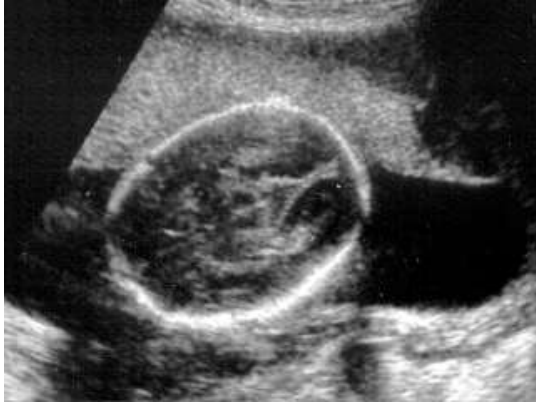Case 2



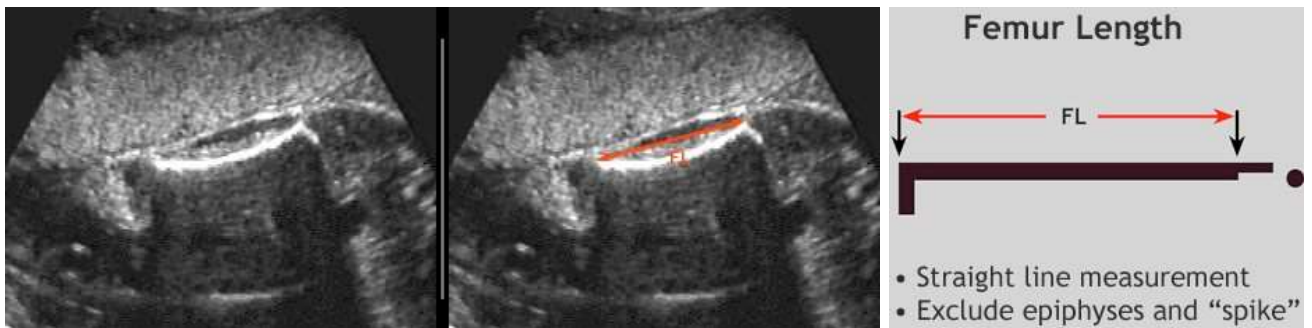
Case 3



Case 4



10.8: Correct Caliper Placement for Femur Length Measurement



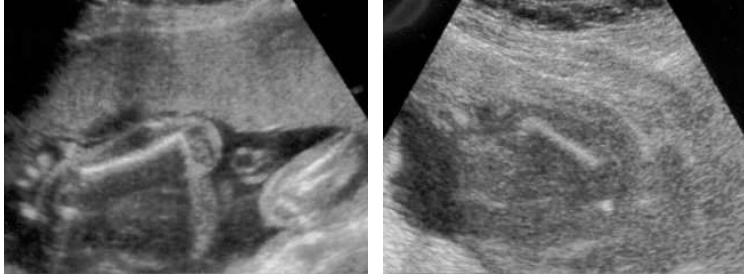
The femur length is often the easiest measurement to obtain because the femur is essentially one-dimensional. The transducer needs to be aligned perpendicular to the long axis of the bone.

It's important to realize that the entire femur should not actually be measured. Only the diaphysis is measured. This is the strongly echogenic middle portion.

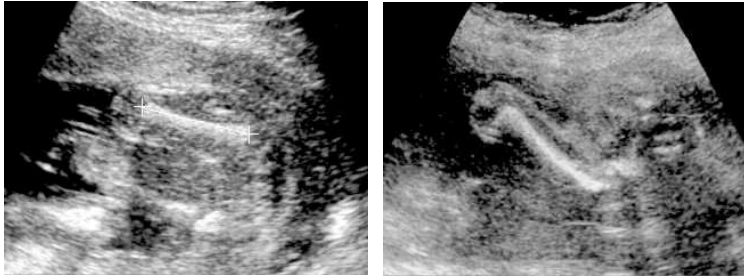
10.9: Practice Measuring: Femur Length

Practice measuring the femur length on these images.

Case 1-2

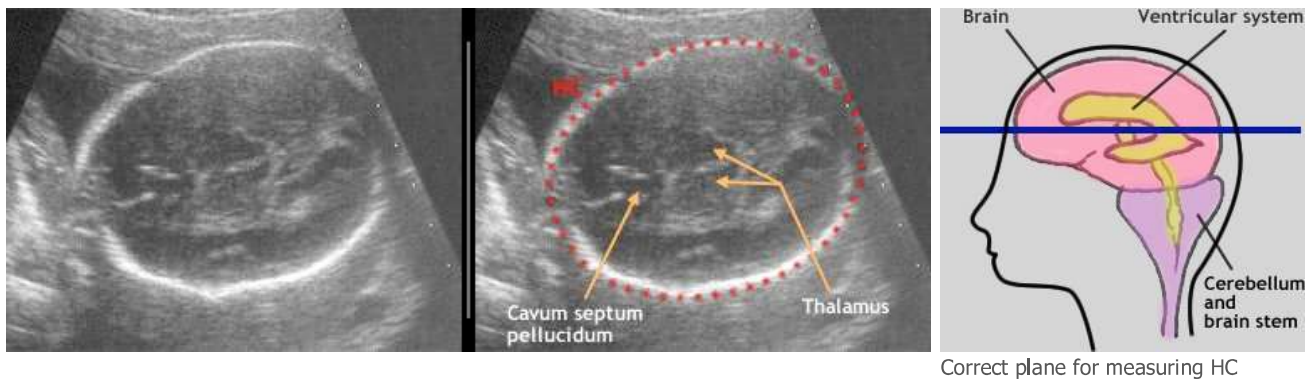


Case 3-4



10.10: Practice Measuring: Head Circumference

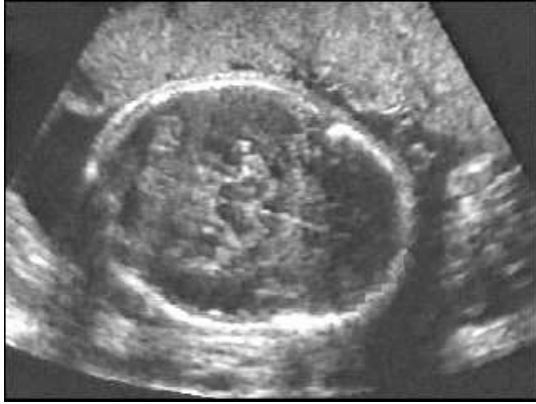
Diagrams and images



Correct plane for measuring HC

The head circumference (HC) must be measured in a transverse view of the fetal head. The thalamus and cavum septum pellucidum should be visible. The Sylvian fissure should be visible laterally. The cerebellum should not be visible. After roughly 14 weeks, the lateral ventricles and choroid plexus should not be visible. (Prior to 15 weeks, these structures dominate most views of the fetal head.) The margins of the calvarium (fetal skull) should be clear and symmetric. The head circumference is measured along the outside of the bony calvarium, not the edge of the scalp.

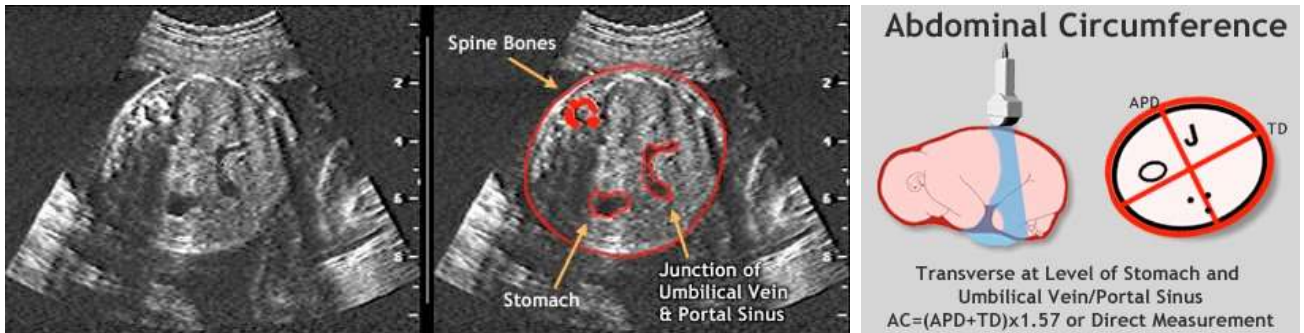
Practice measuring HC



Practice measuring the HC of this fetal head.

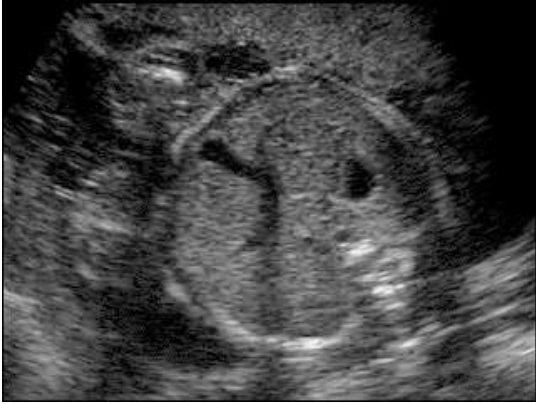10.11: Practice Measuring: Abdominal Circumference

Diagrams and images



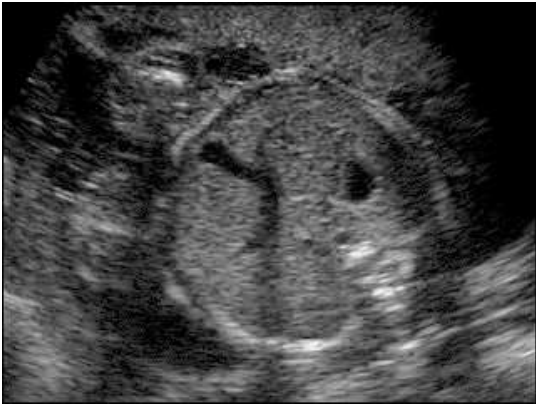The abdominal circumference is measured in a transverse plane containing the fetal stomach and the junction of the umbilical vein and left portal vein as they form a "J." The heart and kidneys should not be visible. The circumference may be measured either directly or by calculation from two diameters. In many situations, an abdominal circumference is not needed prior to a surgical abortion; head and femur measurements are sufficient to determine gestational age within the limits needed prior to surgical abortion. However when needed, the addition of the abdominal circumference will allow a more precise estimation of gestational age.

Practice 2-diameter measurement



Practice measuring the abdominal circumference.

Practice direct measurement

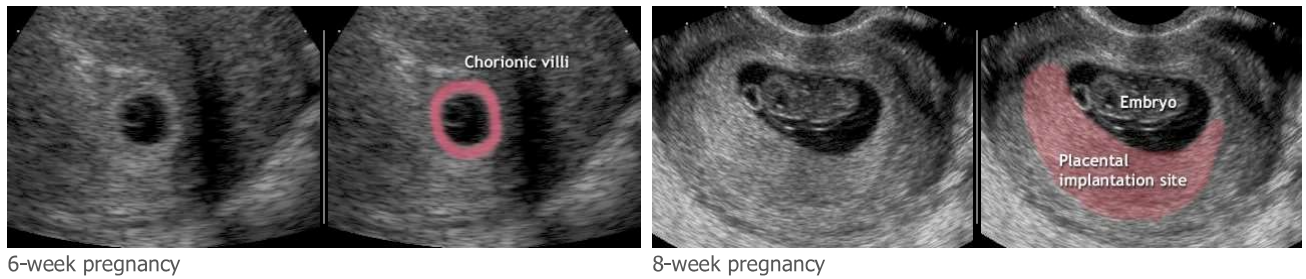

10.12: Interpretation of Measurements

Hadlock formulas calculate gestational age from any combination of biparietal diameter (BPD), head circumference (HC), abdominal circumference (AC), and femur length (FL).

After measurements are taken, your ultrasound machine can generate a composite gestational age. Most ultrasound machines use the formulas developed by Hadlock to combine the BPD, HC, AC, and FL into one gestational age. The formula allow from one to all four of the measurements to be used to calculate the gestational age. You may need to refer to the user's manual for the ultrasound machine to learn how to use the built-in formulas.

11.1: Early Appearance of the Implantation Site



When the gestational sac is first visible sonographically, it is surrounded by a thick, echogenic ring of chorionic villi. Eventually, the portion of this structure adjacent to the myometrium will proliferate to become the placenta. As a structure composed mostly of blood vessels, it is more echogenic than the myometrium to which it is attached on the maternal side and much more echogenic than the amniotic fluid bathing the fetal side. The placental implantation site may be visible sonographically from about eight weeks of pregnancy, but it has little clinical relevance until the second trimester.

11.2: Apparent Change in Location of the Placenta

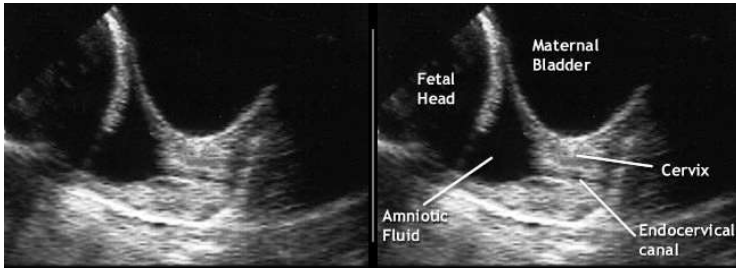
Change in placental location

- Myometrial stretching
- Trophotropism

The embryo may implant anywhere within the uterus. The placenta will develop centered upon the site of implantation. In up to half of early second trimester pregnancies, the placenta will be seen to be at least partially covering the internal cervical os, yet placenta previa is present in only about 0.5% of pregnancies at term. The change in placental location has been termed "migration" but is most likely due to two processes: First, differential expansion of the uterine segments causes the placenta to stay with the upper part of the uterus as the lower segment stretches. Second, the placenta tends to proliferate more in the upper uterus where the blood supply is better and less in

the lower segment where the blood supply is poorer.

11.3: Lower Uterine Segment and Cervix: Normal Appearance



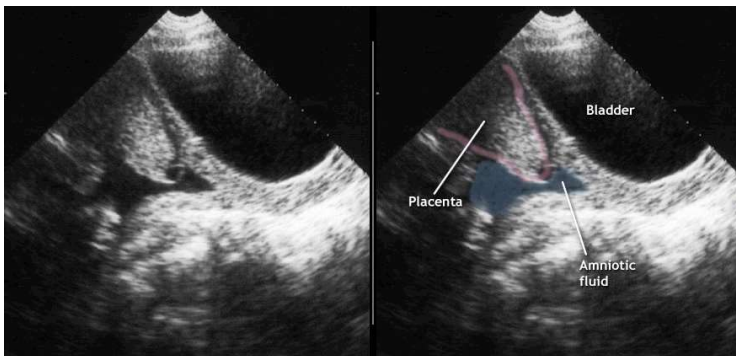
Longitudinal view

A transabdominal longitudinal view of the lower uterine segment seen through a partially filled maternal bladder normally reveals a small amount of amniotic fluid in the lower uterus, preceding the presenting fetal part. In this image, the fetal head is near the cervix. The cervix is clearly outlined by amniotic fluid adjacent to internal cervical os and the full maternal bladder, above. The endocervical canal

is seen as a dark stripe within the cervix.

11.4: Low-Lying Placenta and Placenta Previa: Sonographic Identification

When patients bleed during pregnancy, low-lying placenta, placenta previa, or placental abruption are suspected. Complete or marginal placenta previa is diagnosed by visualizing placental tissue covering the internal cervical os. These images illustrate a spectrum of findings in low-lying placenta and placenta previa. Techniques such as partial bladder filling and transvaginal and transperineal scanning may help clarify the diagnosis.

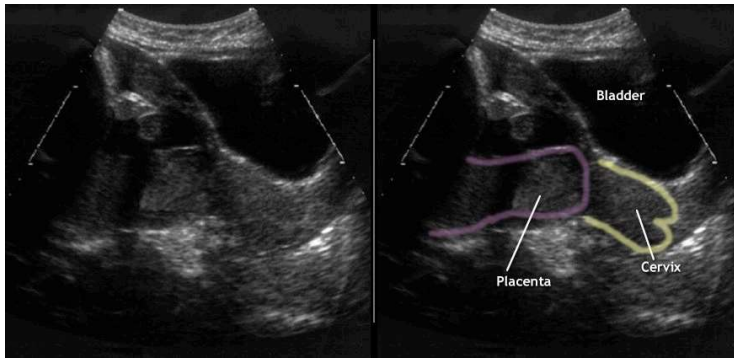


Anterior placenta

Anterior placenta

This image shows an anterior placenta that is low lying but does not extend to the internal os.

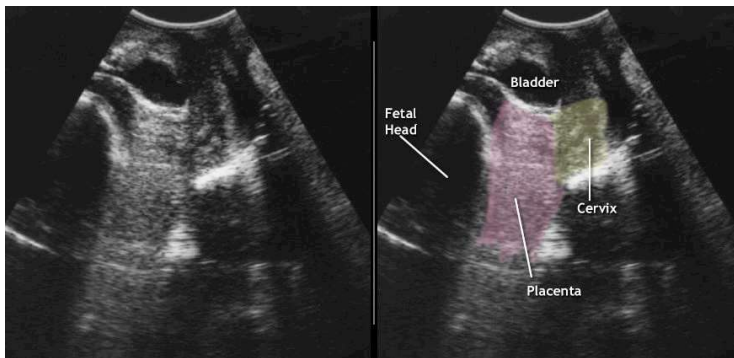
Posterior placenta



Posterior placenta

This image shows a posterior placenta with the placenta extending to and covering the internal os.

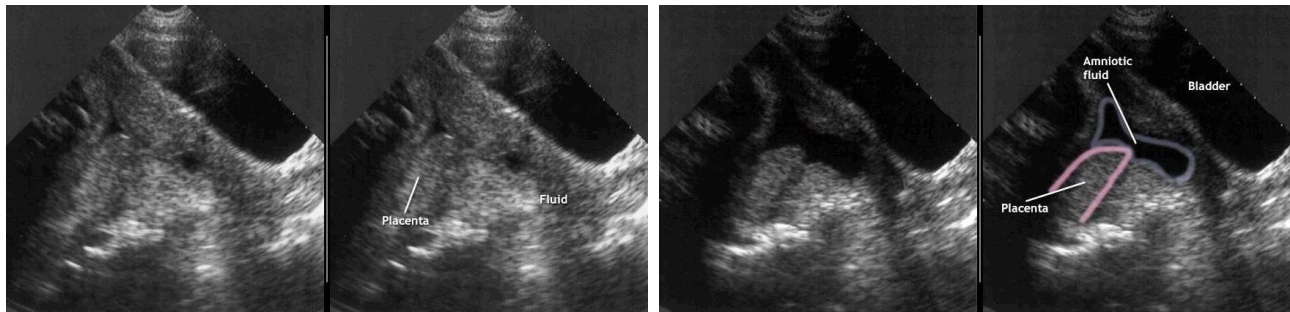
Placenta previa



Placenta previa

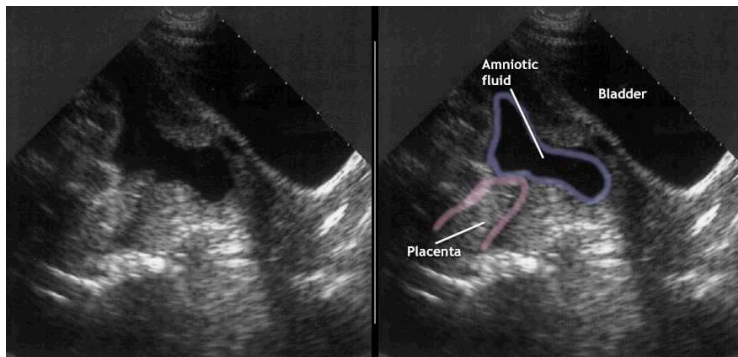
This image of a placenta previa was obtained by the transperineal route. It shows placental tissue between the fetal head (H) and the cervix (CX).

11.5: Lower Uterine Segment: Pitfalls in Imaging



Longitudinal view

Longitudinal view

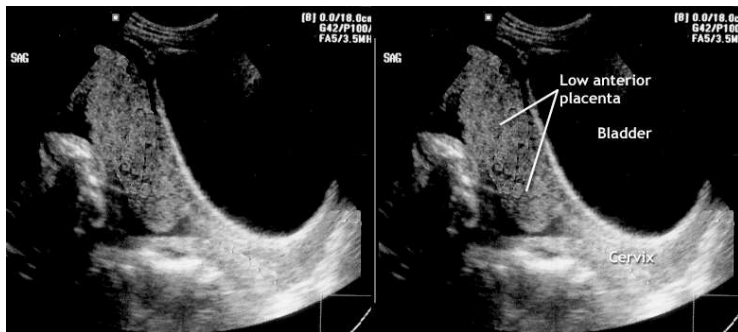

Longitudinal view

Myometrial contractions or an OVER-filled maternal bladder can compress the lower uterine segment producing a false positive diagnosis of placenta previa. Myometrial contractions can be particularly misleading since they last for long periods of time (20+ minutes) early in pregnancy. In this series of three images taken over a 15-minute period, the apparent placenta previa disappears as myometrial contraction of the lower uterine segment relaxes, allowing amniotic fluid (AF) to enter the lower

uterine segment.

11.6: Placenta Implanted on Cesarean Scar Site



Low, anterior placental site

When the placenta is implanted on a cesarean scar site, the patient is at increased risk for placenta accreta. This abnormal attachment can lead to severe hemorrhage at delivery or at the time of surgical abortion. Although it is difficult to diagnose this condition with ultrasound, any low anterior placenta in a second trimester patient who has had a previous cesarean delivery should be considered to be at risk. Additional previous cesareans increase the risk.

12.1: Introduction

Sonographic guidance of second trimester abortion:

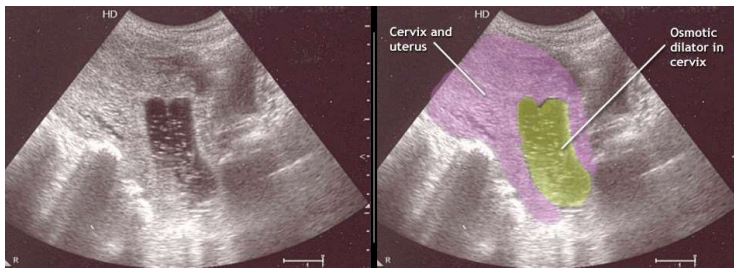
- Cervix
- Uterine position
- Location of instruments
- Avoid or identify perforation
- Assess completeness of procedure

Ultrasound guidance can be helpful during second trimester abortion procedures to identify the condition of the cervix, the position of the uterus, and to visualize the location of instruments. This is advantageous to help avoid perforation of the uterus, or to identify perforation if it occurs. In addition the completeness of the procedure can be verified. The transducer is usually held in the suprapubic area by an assistant.

12.2: Cervix After Use of Osmotic Dilators

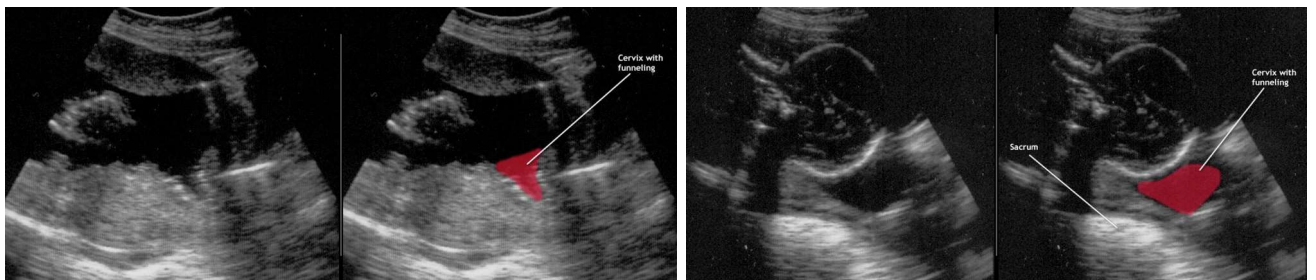
Osmotic dilator in place

This image shows a longitudinal view of the uterus and cervix with an osmotic dilator in place.



Uterus and cervix with an osmotic dilator in place

Cervical funneling after dilator removal

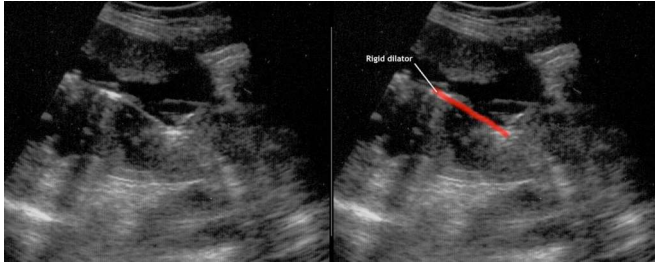


Cervix and uterus after dilators; cervix shows funneling

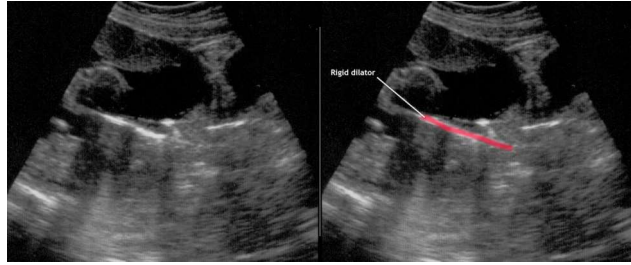
Cervix with funneling and sacral promontory just behind funneling

These images show longitudinal views of the uterus and cervix after the osmotic dilators have been removed. The "funneling" of the cervix is normal after the removal of the osmotic dilators. It results from amniotic membranes prolapsing into dilated cervix.

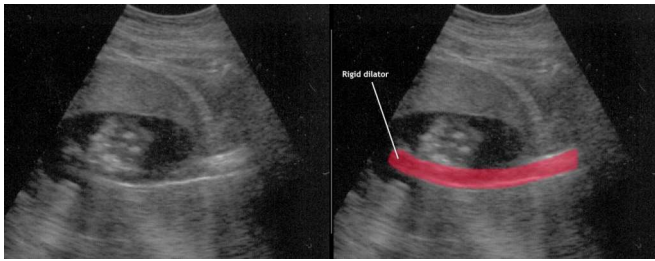
12.3: Rigid Dilators and Cannula



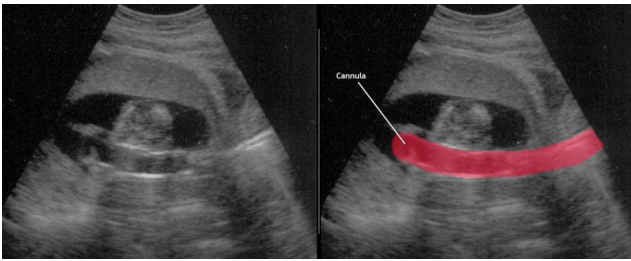
Rigid dilator



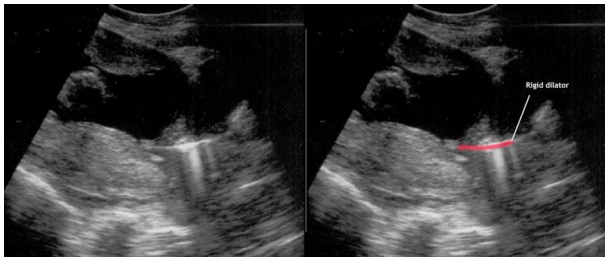
Rigid dilator



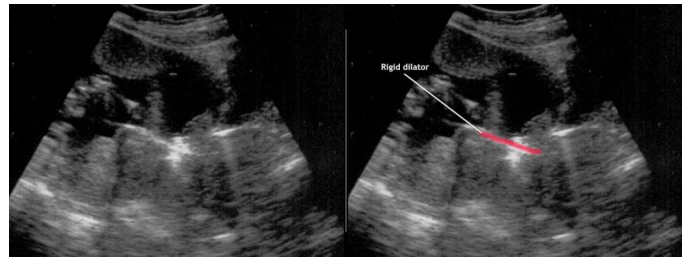
Rigid dilator



Cannula



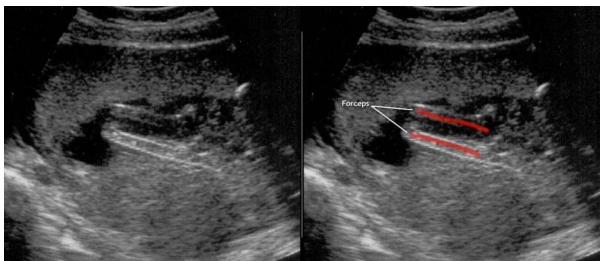
Rigid dilator



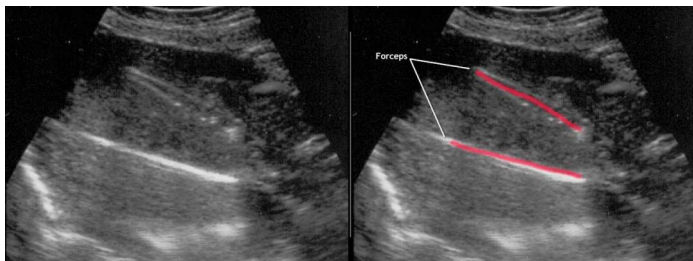
Rigid dilator

These images show longitudinal views of the uterus and cervix with rigid dilators or a cannula in place, before membrane rupture.

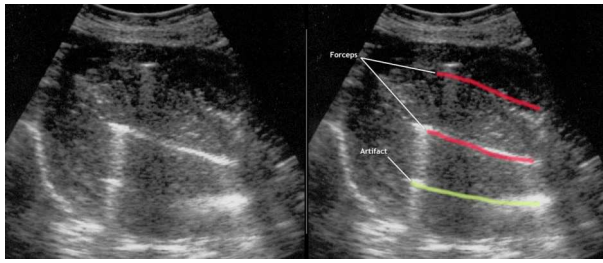
12.4: Forceps and Sharp Curette



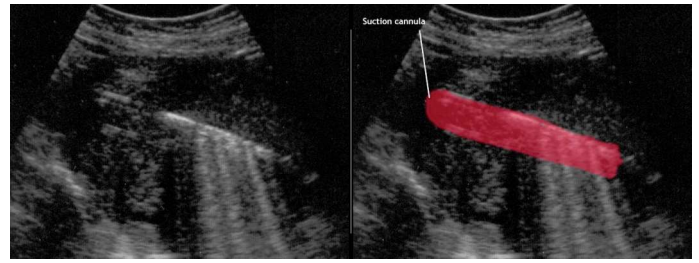
Uterus with forceps in place



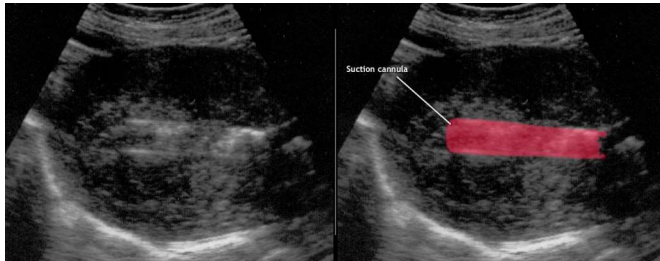
Uterus with forceps in place



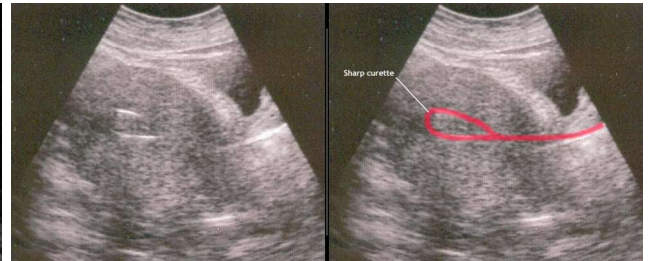Uterus with forceps, showing "third forcep blade" caused by reverberation artifact



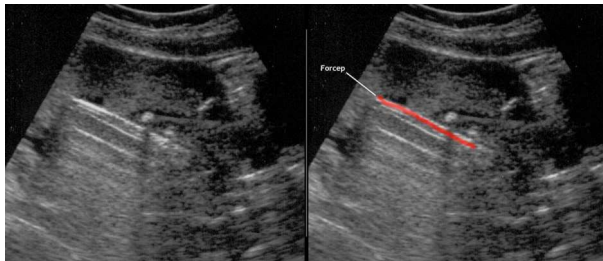
Uterus with suction cannula in place at end of procedure



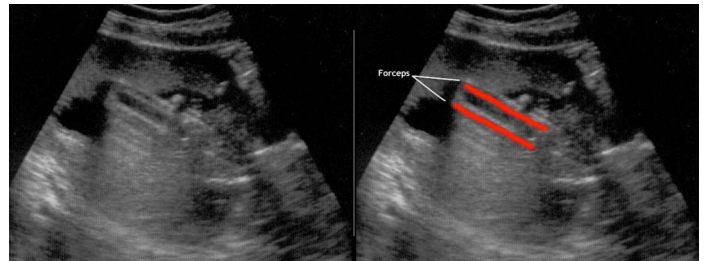
Uterus with suction cannula in place at end of procedure



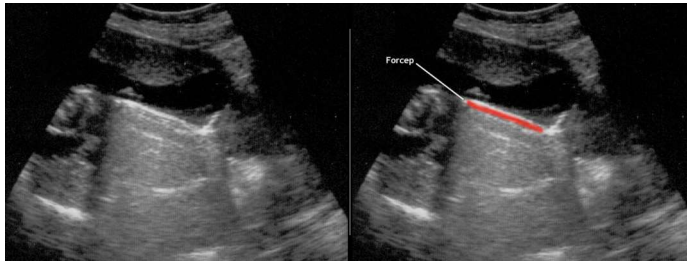
Uterus with sharp curette in place after procedure



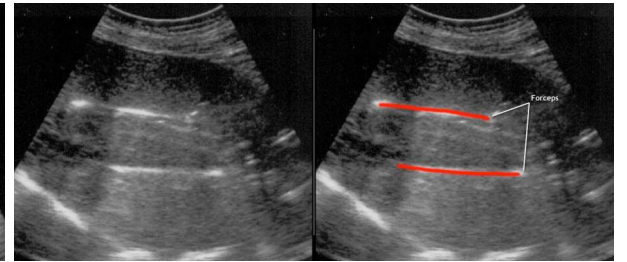
Uterus with forceps in place



Uterus with forceps in place



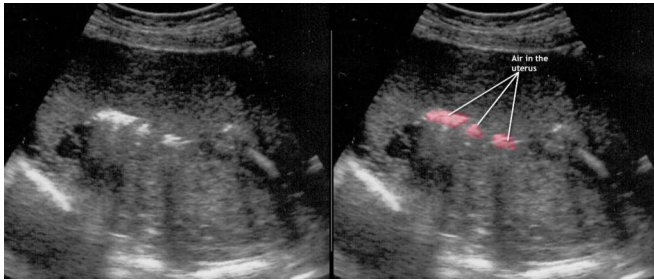
Uterus with forceps in place



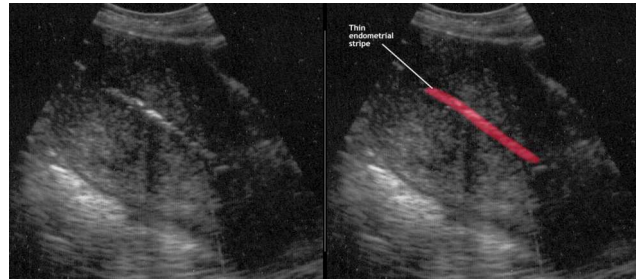
Uterus with forceps in place

These images show longitudinal views of the uterus with forceps or a sharp curette in place.

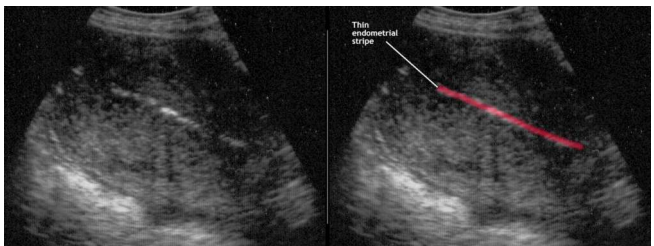
12.5: Sonographic Appearance of Uterus During Second Trimester Abortion



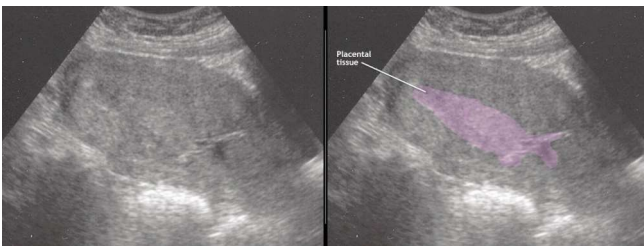
Air in the uterine cavity



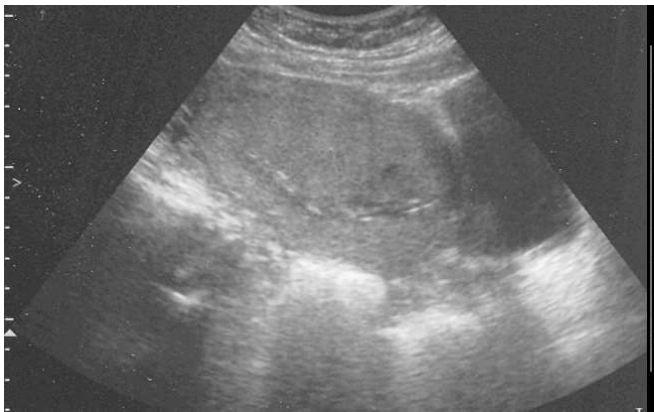
Thin endometrial stripe after procedure



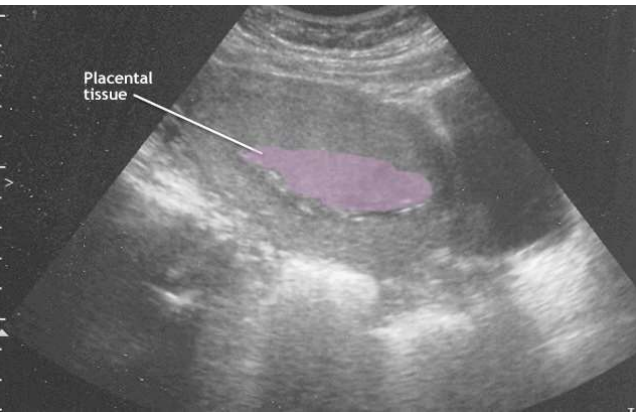
Thin endometrial stripe after procedure



Placental tissue remaining

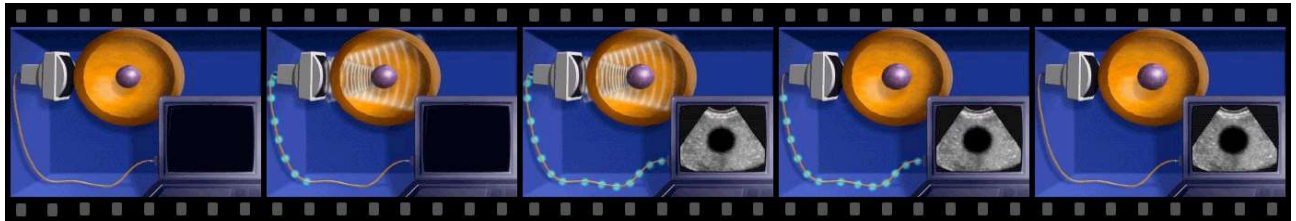


Placental tissue remaining

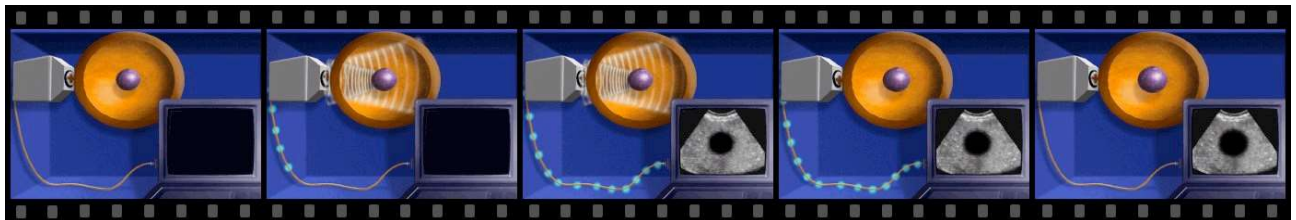


These images show the sonographic appearance of several conditions that can be seen during second trimester abortion procedures including air in the uterine cavity, a thin endometrial stripe indicating a complete procedure, and placental tissue remaining within the uterus.

13.1: Transducer Construction: Linear Array, Curvilinear, and Mechanical Sector

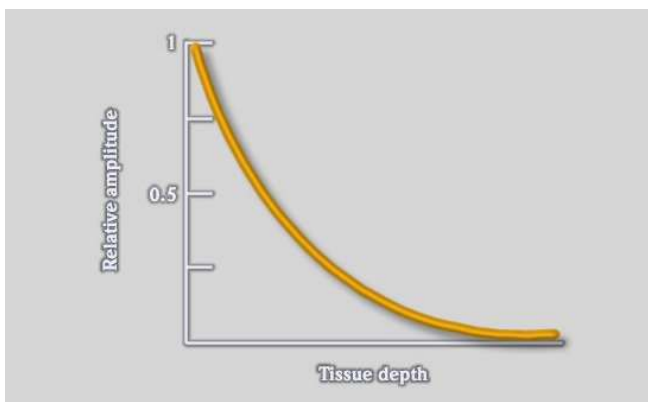


Diagnostic ultrasound transducers come in many shapes and different types of construction. Linear array and curvilinear transducers are composed of many (often hundreds) of piezoelectric crystals that fire in sequence to produce a sweeping motion across the field of view. This sweeping motion rapidly updates the image at 10-20 times per second to produce a real-time moving image.

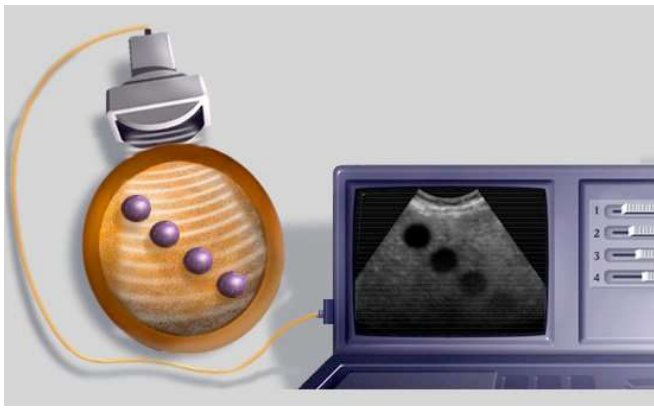


Mechanical sector transducers have only one crystal, but the crystal wobbles back and forth as it vibrates, producing the same sweeping motion that multiple crystals accomplish in linear and curvilinear transducers.

13.2: Attenuation of Sound Energy by Reflection, Absorption, Scattering



As sound passes through tissues, it is dissipated or attenuated by several mechanisms, including reflection, absorption, and scattering.



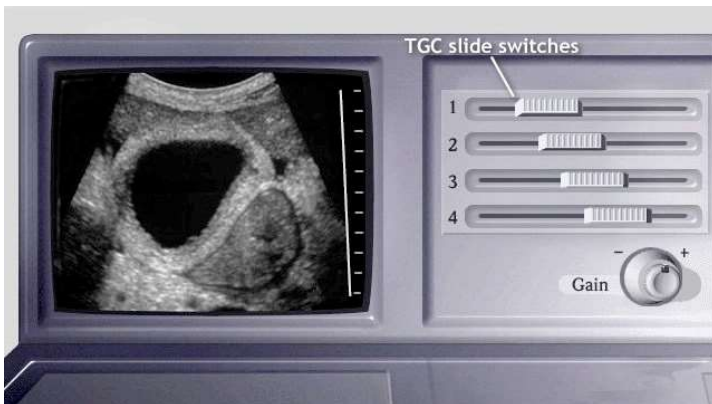Reflected sound waves are detected by the transducer, and the depth from which they came is determined by calculation of the time from transmission to return. Because of the attenuation of the sound beam, the echoes returning from progressively deeper, more distant reflectors are significantly weaker than those returning from shallower, more nearby reflectors. This diagram illustrates the decrease in intensity of returning echoes as a function of depth of origin.

13.3: Time Gain Compensation, Overall Gain, and Power

Time gain compensation (TGC):

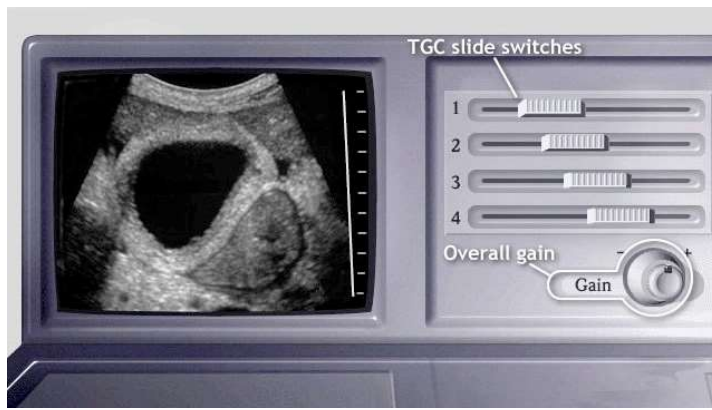
Amplification of echoes from deeper reflectors is greater than from shallower reflectors.

Attenuation of sound energy increases with increasing distance from the transducer. For this reason, deeper reflectors that are just as large as shallower reflectors will produce weaker echoes and will be "seen" by the ultrasound system as less intense unless there is some way to compensate. This compensation is accomplished by differentially amplifying echoes from deeper reflectors. This process is called time gain compensation and is abbreviated TGC.

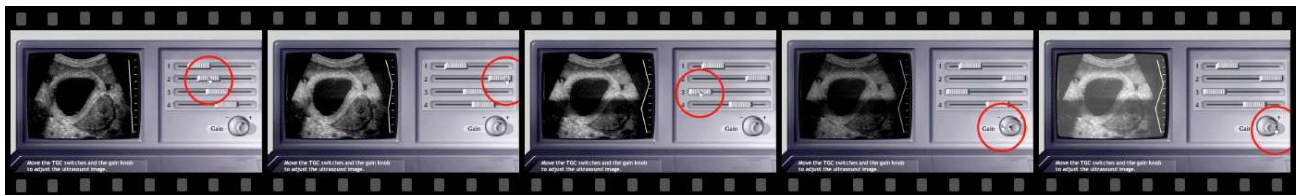


Ultrasound systems usually use a series of slide switches or knobs to control TGC. The position of a particular switch or knob corresponds to the part of the image that it affects. Generally, the TGC switches corresponding to progressively deeper areas of the image must be positioned further to the right to create a smooth, uniform image. A TGC curve can be displayed that shows the degree to which various portions of the image are amplified. During the course of an ultrasound scan, it is common for the operator to periodically readjust the TGC

switches to optimize image quality.

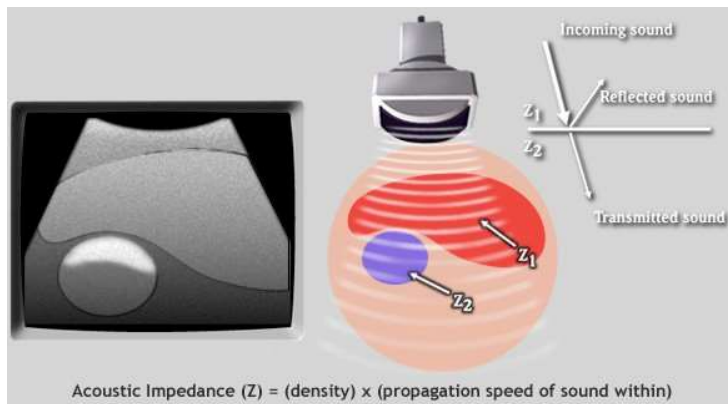


In addition to TGC switches, a knob that controls overall gain is usually present. Although the overall gain knob lightens or darkens the image, this control is different from the brightness and contrast knobs on the video screen. The overall gain knob controls overall amplification of returning echoes.



Some ultrasound systems allow the user to also control the intensity of the sound energy emitted from the transducer. This control is usually labeled "Power," "Power Output," or "Transmit Power." Despite the fact that ultrasound energy of diagnostic power ranges has never been shown to produce adverse effects, it is prudent to use the lowest power setting that is needed to produce quality images. Use of the lowest effective power level has been termed the ALARA principle. The power output of some systems is fixed and therefore not available for user control. The power output of most diagnostic ultrasound scanners is about 1 milliwatt per square centimeter.

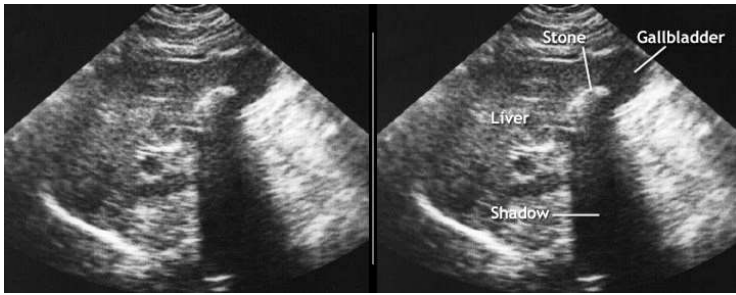
13.4: Acoustic Impedance



Sound energy is reflected from interfaces between tissues. The property of tissues that determine the intensity of the sound reflection is their acoustic impedance, signified by the letter Z. Acoustic impedance is, in turn, determined by the tissue's density multiplied by the speed of sound transmission within it. Since most tissues transmit sound at about 1540 meters per second, acoustic impedance is basically a function of tissue density. When the difference in acoustic impedance between two tissues is greater, more of the sound beam will

be reflected and less transmitted to deeper tissues. The brighter the reflection that an object or area produces, the more echogenic it is said to be. Areas that do not produce echoes are termed anechoic or sonolucent.

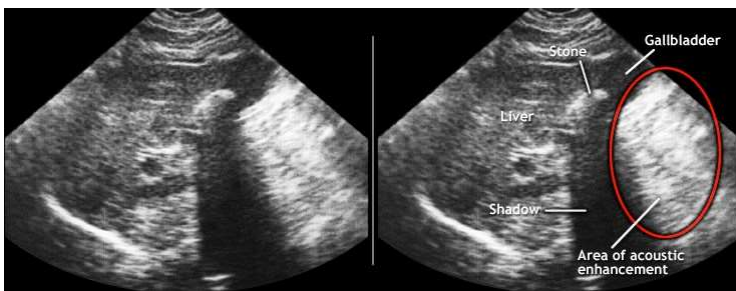
13.5: Acoustic Mirrors



If the difference in acoustic impedance at an interface is large enough, all the sound energy will be reflected and none will pass through. An acoustic mirror will be created in this situation, and no amount of manipulation of gain or power will enable the user to image deeper structures that lie within the acoustic shadow. This image of a gallstone illustrates this problem. Other

typical acoustic mirrors are bone-tissue, air-fluid, and air-tissue interfaces. Scanning from a different direction is necessary to image the area within the acoustic shadow. A good scanning path, free of obstructing bones or gas, is termed an acoustic window.

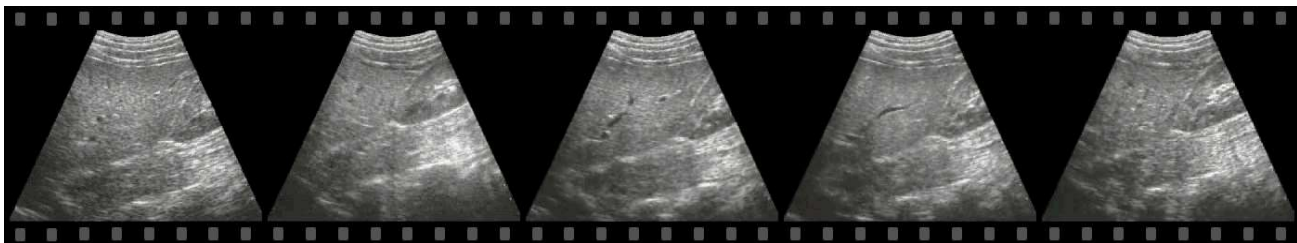13.6: Acoustic Enhancement



Sound energy that passes unobstructed through a region of low density, such as fluid, arrives stronger than energy in that portion of the beam that must pass through more acoustically dense tissue. Echoes from behind the low-density area are therefore stronger and appear brighter. This effect is called acoustic enhancement and should not be

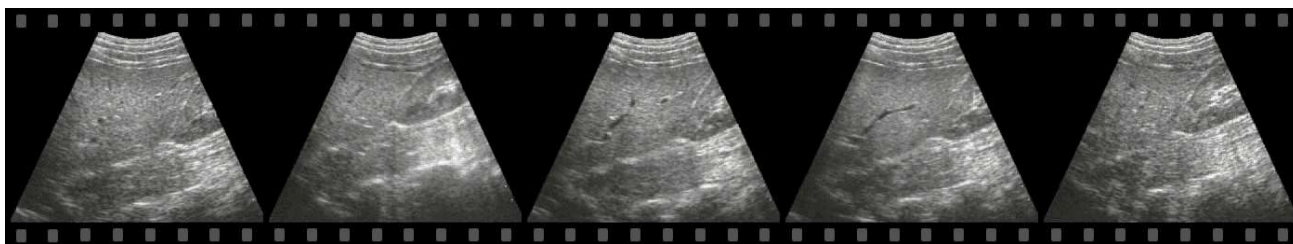interpreted as true differences in the tissue being imaged. In the same image presented in the previous lesson, there is acoustic enhancement in that portion of the liver beneath the fluid-filled region of the gallbladder.

13.7: Frame Rate



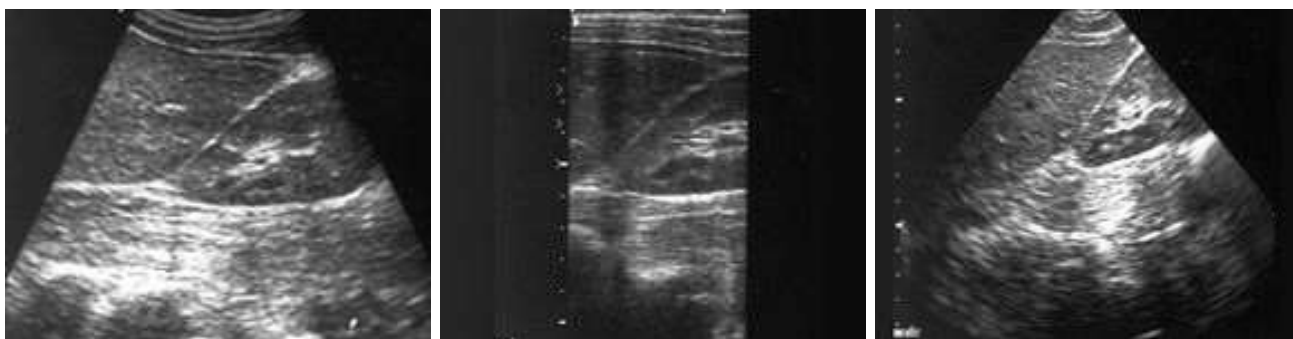
High frame rate

Frame rate refers to the real-time speed with which the ultrasound image is updated. Faster frame rates create a smoother image, while slower frame rates may appear jerky. Slower frame rates may offer improved resolution on many ultrasound systems.



Low frame rate

13.8: Beam Shape and Focus



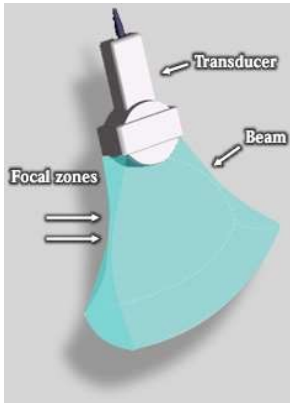
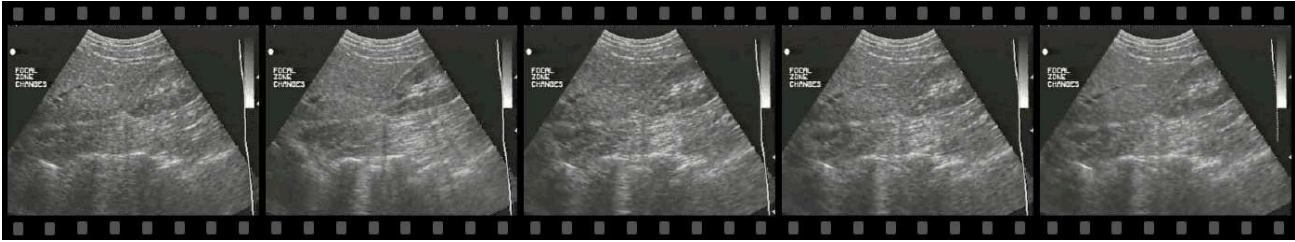Curvilinear

Linear array

Mechanical sector

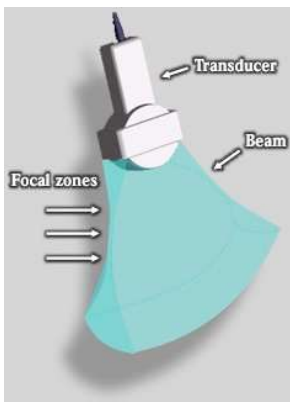
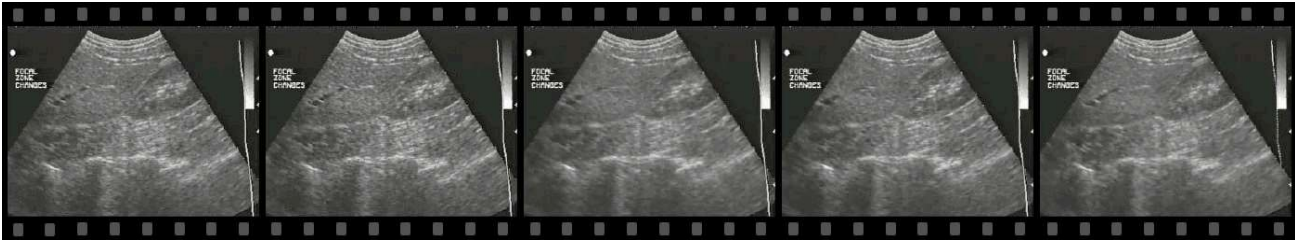
A sound beam, like any other energy beam, spreads out as it leaves its source. A sound beam has three dimensions: width, length or depth, and thickness. The width of an ultrasound beam is often determined by the transducer crystal arrangement. Linear array transducers produce images displayed as rectangles. Curvilinear and mechanical sector transducers produce images in a pie shape. A transducer with a small face and a widely diverging field of view is advantageous in imaging between obstructions such as ribs.

Two Focal Zones

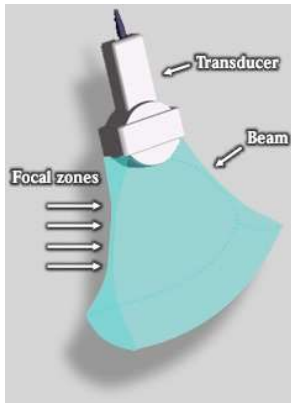
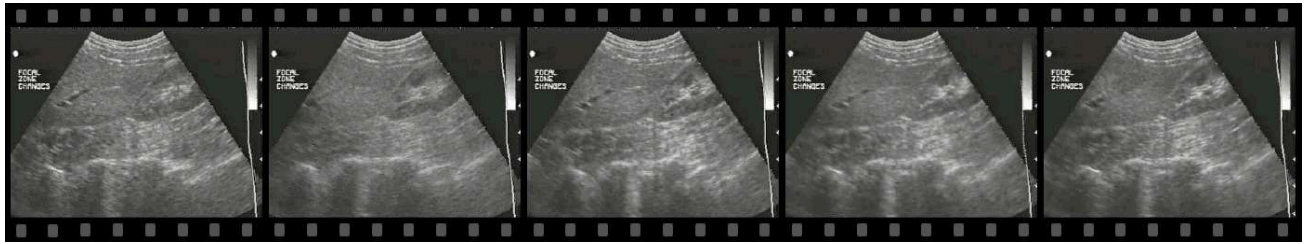

The thickness of a sound beam generally increases as it leaves the transducer, but can often be controlled to some degree by creating focal zones within the beam. The beam is narrowed at a focal zone, producing better spatial resolution at those points. Focal zones are created by complex electronic means. As the user activates more focal zones, the frame rate is generally slowed down simultaneously. These video frames show how changing focal zones affects the image.

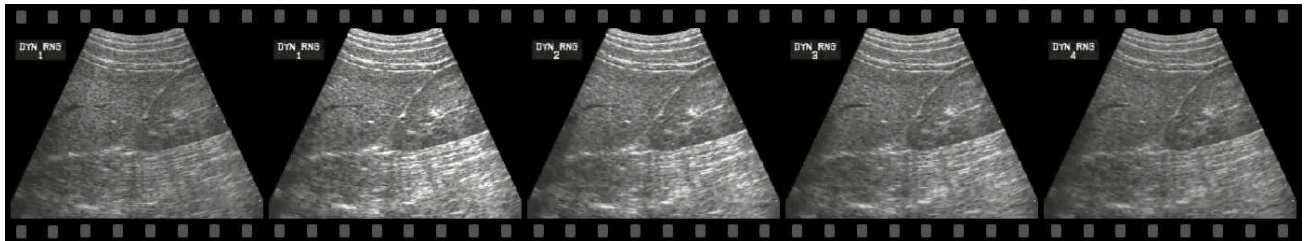
Three Focal Zones



Four Focal Zones

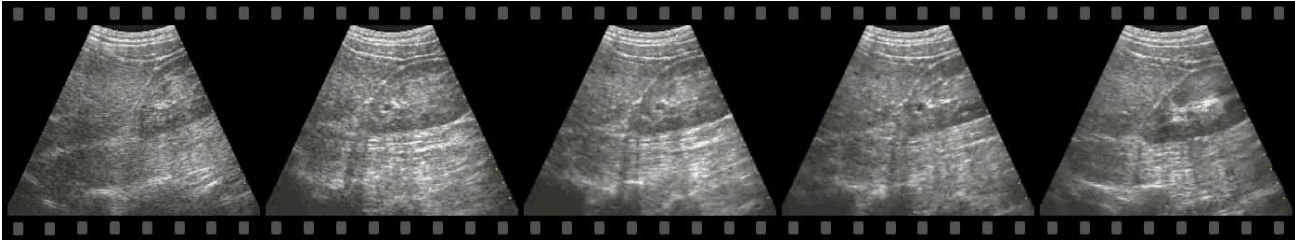


13.9: Dynamic Range



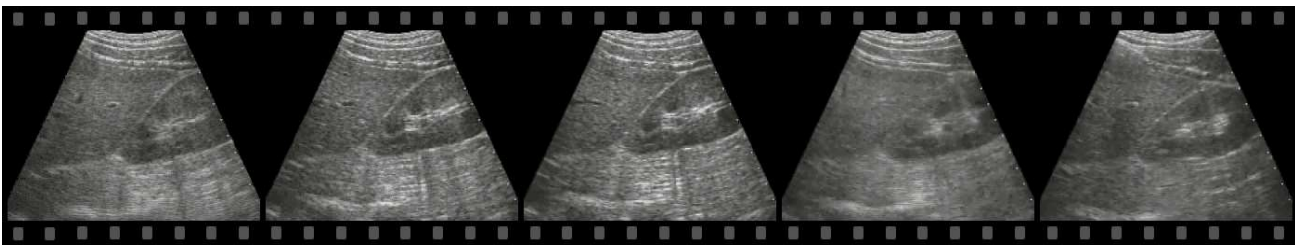Some ultrasound systems permit the user to control the dynamic range, the range of grayscale of the echoes that will be displayed. Changes in dynamic range alter the appearance of the image in a way that may be described as increasing softness or hardness. Higher dynamic range settings allow more low-level echoes to be displayed.

13.10: Frame Averaging, Correlation or Blend



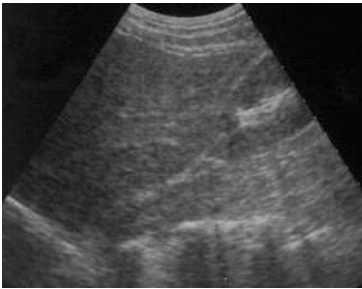
Frame averaging off

Some ultrasound systems allow the user to control frame averaging, or how much one frame of imaging blends into the next. Increasing frame averaging softens the image.

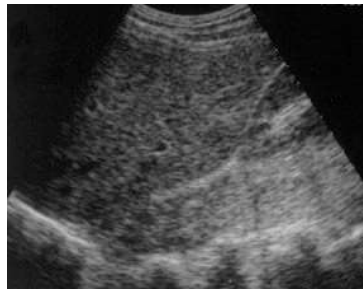


Frame averaging on

13.11: Reject or Filter



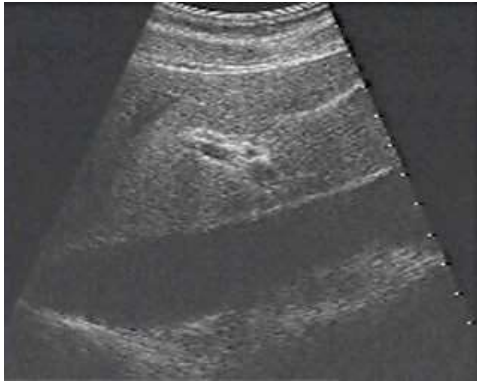
Reject off




Reject at 35%

Some ultrasound systems allow the user to cause the display to ignore lower level echoes. Rejecting lower level echoes creates a more contrasted image and can help define edges.

13.12: Display Modes: B-Mode and M-Mode



Normal two-dimensional ultrasound imaging is called B-mode imaging. The two dimensions represented are depth and width, with depth displayed in the vertical axis and width displayed in the horizontal axis. The B stands for brightness, since the objects in the scan beam are represented by dots of various brightness. The general appearance of the image is subject to some control by the operator using the features reviewed in the previous pages, including overall gain, time gain compensation, frame rate, frame averaging, reject, and dynamic range adjustments.



If time is substituted for width, an M-mode display is created. M stands for motion. In this type of display, depth is represented in the vertical axis, and time is represented in the horizontal axis. Only points along one thin line are really imaged; anything that moves within that line produces a wave as the time axis moves along. The line that is imaged is called the M-line, M-cursor, or TM-cursor.

13.13: Doppler Description



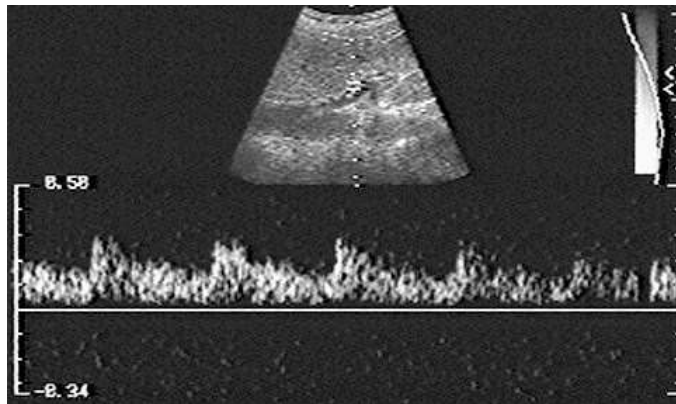
The Doppler effect is a change in the frequency of reflected sound caused by movement of either the source or the reflector. The Doppler effect is apparent when the sound of a passing ambulance changes from a high note to a lower note as it first comes toward and then goes away from you.



This same Doppler effect is used in diagnostic ultrasound to perform Doppler velocimetry. Doppler velocimetry is widely used in peripheral vascular applications, but can also be used to study blood flow in the heart and many abdominal vessels. The principle underlying the use of Doppler is that when a sound beam encounters a moving substance such as blood, the frequency of any sound

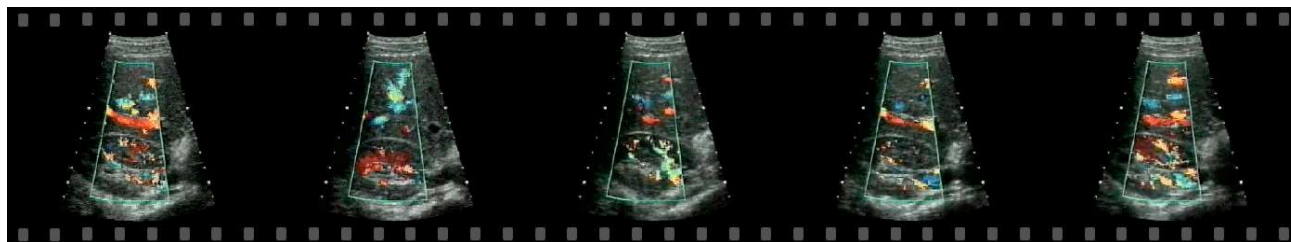
reflected from that moving substance is shifted. Measuring that shift indicates the velocity of the moving substance in the sound beam's path. The angle of incidence has an effect on the Doppler shift.

13.14: Duplex Doppler Imaging



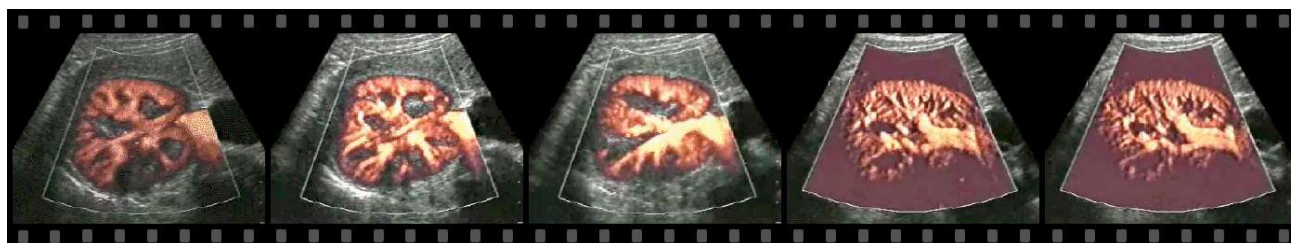Here you see an ultrasound image with a cursor passing through the superior mesenteric artery. The box located over the superior mesenteric artery is a sample window for Doppler velocimetry. The waveforms below show the velocity of blood flow within that sample window. This type of imaging is called duplex imaging because it displays a two-dimensional B-mode image next to a Doppler waveform tracing.

13.15: Color Doppler



Color Doppler technology measures blood flow in a large number of sites over the entire image or in a selected portion of the image and assigns colors to that motion based on its velocity and direction. In this image, color Doppler is used to identify blood flow in the liver and right kidney.

13.16: Power Doppler



Power Doppler is a newer technique that assigns color to the intensity of blood flow without regard to its direction or velocity. In doing so, it reveals the density of red blood cells and shows where they are flowing. Power Doppler is three to five times more sensitive than standard color Doppler in detecting and displaying flow. This is a power Doppler image of a kidney.

14.1: Overview of Steps in Gaining Proficiency



Steps in gaining proficiency in ultrasound

- Study basic principles; learn to recognize normal and abnormal images
- Take the post-test
- Meet with your medical director to begin hands-on training
- Observe a skilled practitioner performing several ultrasound scans
- Perform 30 to 40 ultrasound scans under direct supervision
- Review progress regularly during training period
- Participate in ongoing self-learning and group case reviews

Gaining proficiency in ultrasound is a stepwise process. First, you should study the basic principles and learn to recognize normal and abnormal images. That is the purpose of this CD-ROM-based program. You can review these materials as often as you choose. In fact, as you proceed through the learning process, coming back to this program will enhance your skills. After taking the post-test, you should meet with your medical director or his/her designee to begin the hands-on portion of your training. The hands-on process will usually begin by observing a skilled practitioner performing several ultrasound scans. Then, you should perform 30 to 40 ultrasound

scans under direct supervision of a skilled practitioner. Not all individuals learn new skills at the same rate, so you should discuss your progress regularly with your supervisor to determine when you are ready to begin scanning on your own. You will never be "done" learning about ultrasound. Engaging in ongoing self-learning activities and group case reviews will enhance and refine your skills.

14.2: Documentation During Training



Keep a record of scans during your training period in a logbook or journal:

- Reason for the exam
- Physical findings
- Your sonographic findings compared to supervisor's findings
- What you learned from the case
- Consider keeping representative images

Keep a record of your scans during your training period to share with your supervisor and to help yourself understand what you have learned and what you need to study. Your supervisor may provide a worksheet, or consider making your own logbook or journal that includes physical findings, your sonographic findings compared to your supervisor's findings, and what you learned from the case. Keeping representative images in your logbook or journal will help with your learning. There is a sample worksheet to document hands-on training at the end of the chapter. If you keep images, make sure the patient's name is covered or removed. Thermal prints are convenient and

inexpensive for this purpose.

14.3: Transmitting Images for Review

Ways to transmit images:

- Thermal prints carried by hand
- Thermal prints scanned with a computer scanner and converted to digital files
- Videotapes
- Direct digital capture of still images and video segments from your ultrasound machine on to floppy disks, CDs or DVDs.

Even experienced practitioners frequently want to share ultrasound images in questionable, unusual or interesting cases. For urgent cases, such as suspected ectopic pregnancy, immediate on-site consultation with an experienced practitioner is best. If on-site consultation is not available, sending the patient to a consultant is the next best option. Thermal prints can be scanned and converted to digital files. If your ultrasound machine has the capability, digital images can be captured directly. For remote consultation, digital files can be emailed. You should be careful to abide by your clinic's patient information privacy policy

when transmitting images. Except in unusual circumstances, the patient's name should be removed from the images.

14.4: Printable Worksheet for Assessing Progress

This sample worksheet may be used by you and your supervisor to document and assess your progress.

14.5: Granting Clinical Privileges to Perform Ultrasound in Abortion Services

DOCUMENTATION OF HANDS-ON ULTRASOUND										
MR #	#1	#2	#3	#4	#4	#6	#7	#8	#9	#10
weeks LMP										
1st trimester										
Sac										
DDS										
long view										
transverse										
yolk sac										
CRL										
FHT										
gest age by sono										
2nd trimester										
BPD										
femur length										
gest age by sono										
gest age by POC										
post-abortion										
post surgical AB										
post med AB										
Proctor initials										

A sample form is included which may assist the medical director or the physician program director to document that a learner is granted privileges to perform ultrasound in the setting of abortion care. Non-clinicians may be granted privileges for performing ultrasound; clinicians may also be granted privileges for interpreting ultrasound. Skills of those performing ultrasound should be evaluated on a periodic basis.

Ultrasound Worksheet and Progress Assessment

Ultrasound Worksheet and Progress Assessment

Provider's name:

Clinic site:

Today's date:

Patient overview: Age: G: P: Ab: LMP:

Reason for scan: Diagnosis of pregnancy Gestational age assessment Pain Bleeding
Pre-procedure Intra-operative guidance Other

Details if "other":

Route of scan: Transabdominal Transvaginal Both

Physical findings:

Uterine size:

Adnexae:

Tenderness:

Ultrasound findings:

Uterine size:

Uterine contents:

Gestational sac: Yes No Measurements:

Mean sac diameter: Gestational age:

Yolk sac: Yes No

Embryo: Yes No Cardiac motion Yes No

Crown-rump length: Gestational age:

Cul-de-sac:

Adnexae:

Tenderness:

Diagnosis and conclusions:

Clinical care plan:

Signature and date: _____

=====
Supervisor's comments and evaluation:

Patient counseled properly: Yes No
Equipment set up properly: Yes No
Transducer(s) cleaned prior to exam: Yes No
Gain settings adjusted properly: Yes No
All essential anatomy examined: Yes No
Measurements taken properly: Yes No
Appropriate images captured: Yes No
Ultrasound and physical findings correlated: Yes No
Appropriate conclusions and plan made: Yes No
Feedback given to learner: Yes No
Exam conducted: Independently With assistance
Comments:

Signature and date: _____

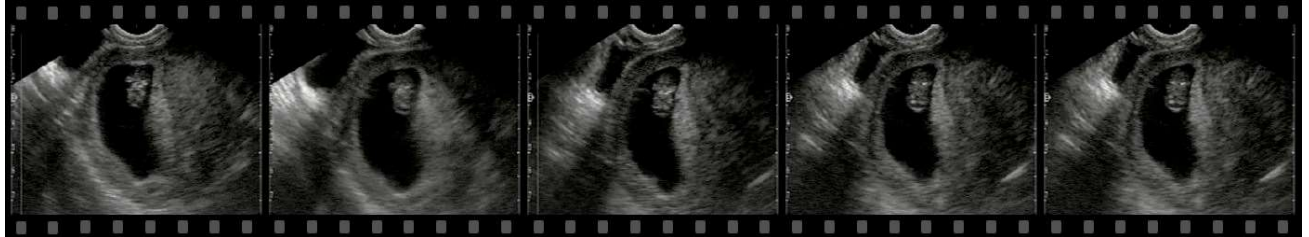DOCUMENTATION OF HANDS-ON ULTRASOUND

	#1	#2	#3	#4	#4	#6	#7	#8	#9	#10
MR #										
weeks LMP										
1st trimester										
Sac										
DDS										
long view										
transverse										
yolk sac										
CRL										
FHT										
gest age by sono										
2nd trimester										
BPD										
femur length										
gest age by sono										
gest age by POC										
post-abortion										
post surgical AB										
post med AB										
Proctor initials										

	#11	#12	#13	#14	#15	#16	#17	#18	#19	#20
MR #										
weeks LMP										
1st trimester										
Sac										
DDS										
long view										
transverse										
yolk sac										
CRL										
FHT										
gest age by sono										
2nd trimester										
BPD										
femur length										
gest age by sono										
gest age by POC										
post-abortion										
post surgical AB										
post med AB										
Proctor initials										

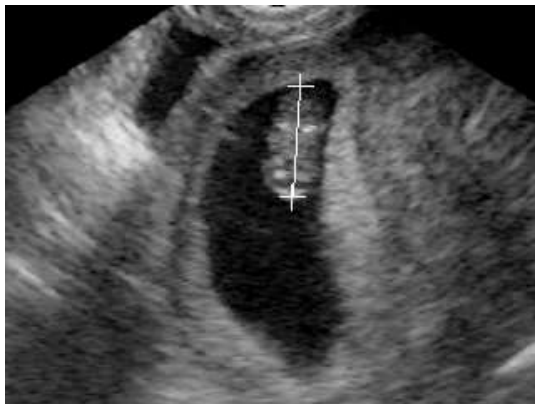COURSE ANSWER KEY

2.14: Machine Controls: Electronic Calipers



ANSWER: Frame 4 and 5 in this image are both acceptable for measuring the CRL.

It is essential to be able to perform measurements to date the pregnancy. On-screen measurements are more accurate than those performed later on printed images. The ultrasound machine has electronic calipers to use when performing on-screen measurements. The operator uses a tracking ball or other pointing device to locate and set the calipers at desired points. The software calculates and displays the measurement.



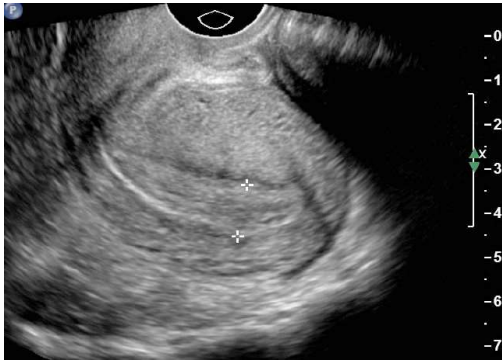
ANSWER: This image shows proper caliper placement for measuring the CRL.

Practice measuring by setting the calipers and performing a measurement of the length of the embryo in this image. You can mark it with a pencil or decide mentally where to place the calipers.

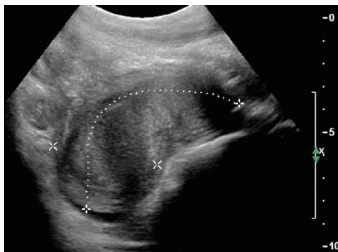4.16: Uterine Position Exercises

EXERCISE: Anteverted vs. retroverted uterus

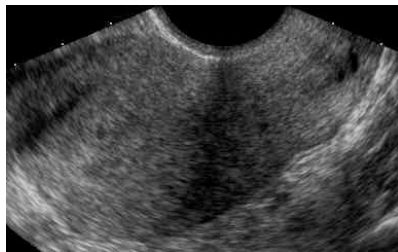
For each of these images, check the box indicating whether you believe the uterus is anteverted or retroverted.



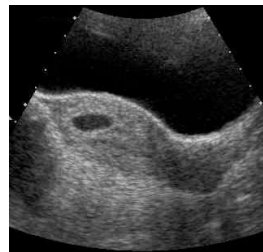The uterus in this transvaginal scan is: anteverted
 retroverted



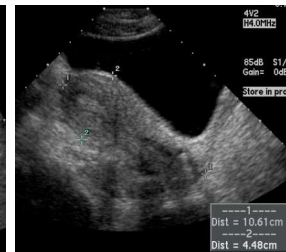
The uterus in this transabdominal scan is: anteverted
 retroverted



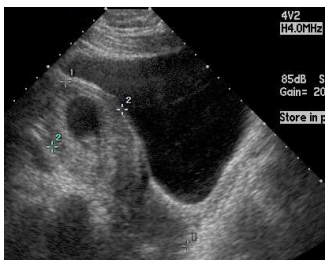
The uterus in this transvaginal scan is: anteverted retroverted



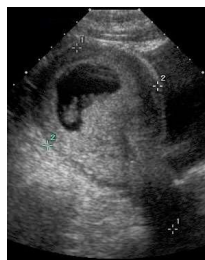The uterus in this transabdominal scan is: anteverted
 retroverted



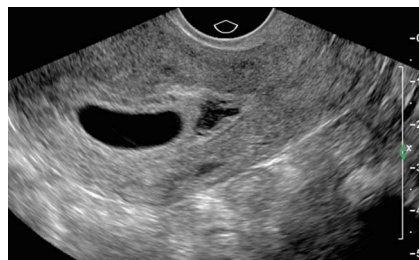The uterus in this transabdominal scan is: anteverted retroverted



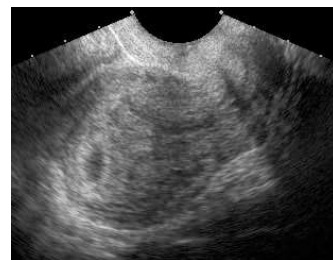The uterus in this transabdominal scan is: anteverted
 retroverted



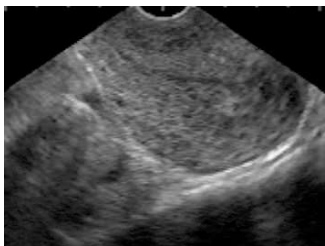
The uterus in this transabdominal scan is: anteverted
 retroverted



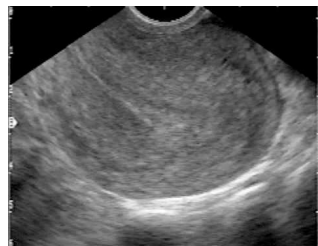
The uterus in this transvaginal scan is: anteverted retroverted



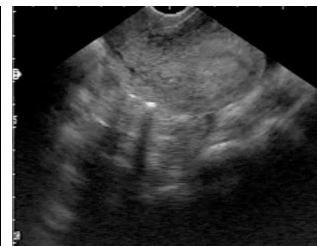The uterus in this transvaginal scan is: anteverted
 retroverted



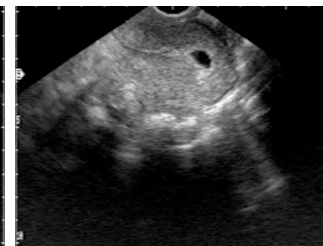
The uterus in this transvaginal scan is: anteverted
 retroverted



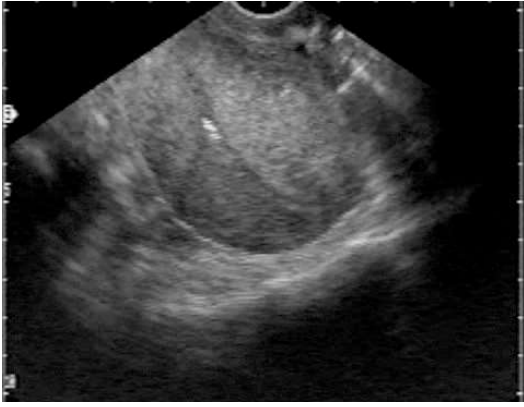
The uterus in this transvaginal scan is: anteverted
 retroverted



The uterus in this transvaginal scan is: anteverted
 retroverted



The uterus in this transvaginal scan is: anteverted
 retroverted

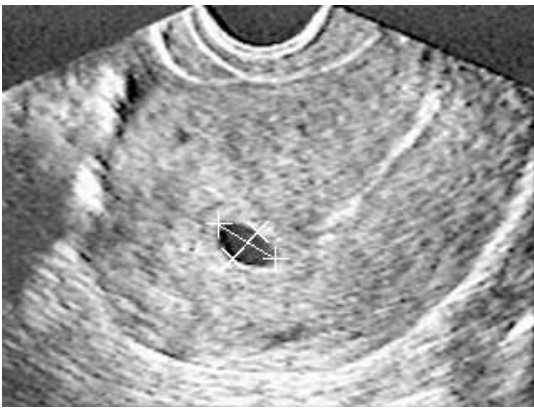


The uterus in this transvaginal scan is: anteverted
retroverted

5.18: Practice Measurements of the Gestational Sac

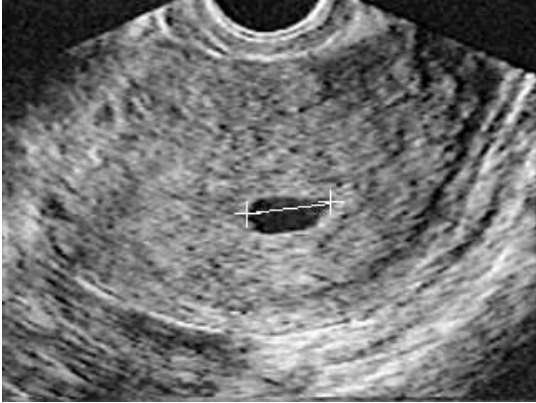Longitudinal plane

Now practice making these measurements yourself on this set of two images. The first image is in the longitudinal plane; use it to measure the sac length and height. The second image is in the transverse plane; use it to measure the sac width.



ANSWER: This image shows proper caliper placement for measuring the GS in the longitudinal plane.

Transverse plane



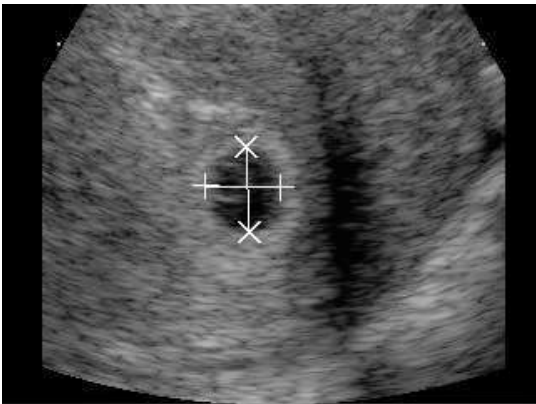
ANSWER: This image shows proper caliper placement for measuring the GS in the transverse plane.

5.20: More Practice Measuring the Gestational Sac



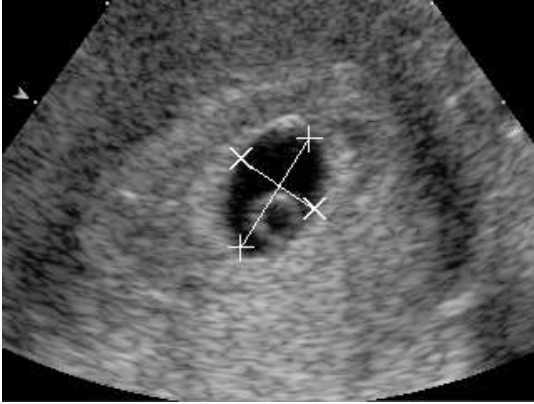
Practice measuring the length and width of the gestational sac in these cases.

Case 1



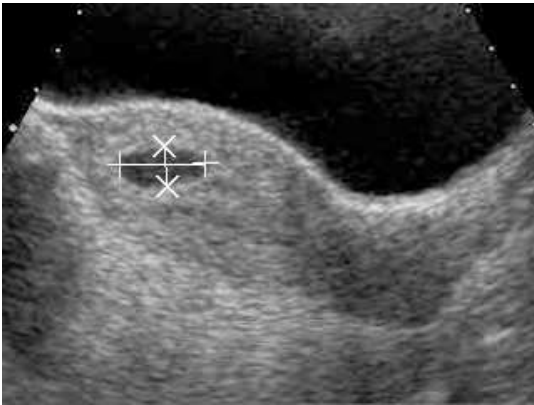
ANSWER: This image shows proper caliper placement for measuring the GS.

Case 2



ANSWER: This image shows proper caliper placement for measuring the GS.

Case 3

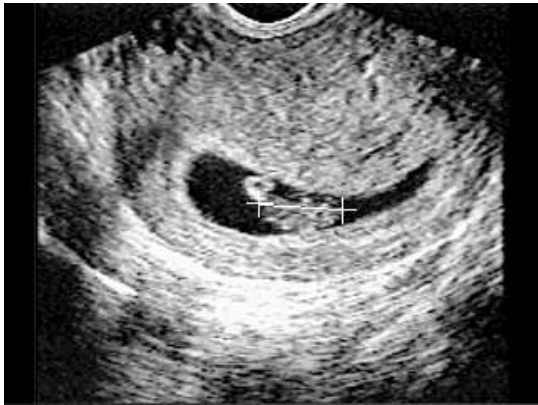


ANSWER: This image shows proper caliper placement for measuring the GS.

5.34: Practice Measurements of CRL

Practice measuring the crown-rump length of these embryos.

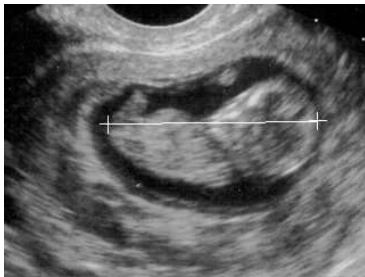Case 1



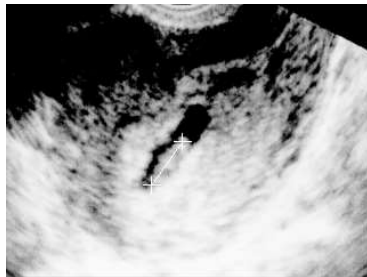Be sure that you do NOT include the yolk sac in your measurement.

ANSWER: This image shows proper caliper placement for measuring the CRL.

Case 2-3

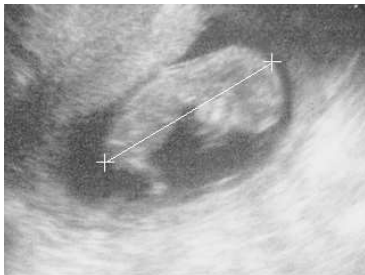

ANSWER: This image shows proper caliper placement for measuring the CRL.

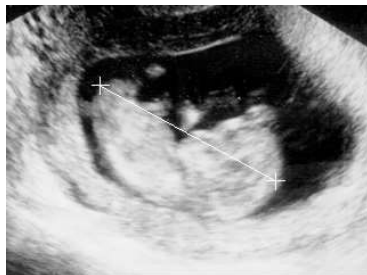

ANSWER: This image shows proper caliper placement for measuring the CRL.

Case 4-5

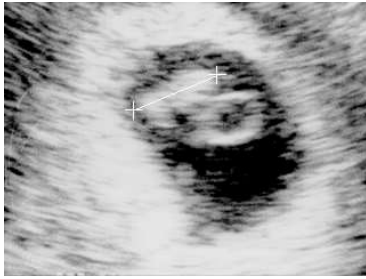

ANSWER: This image shows proper caliper placement for measuring the CRL.

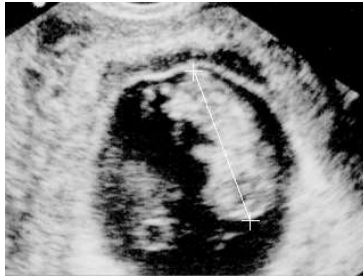

ANSWER: This image shows proper caliper placement for measuring the CRL.

Case 6-7

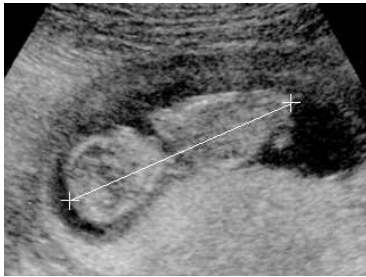


ANSWER: This image shows proper caliper placement for measuring the CRL.

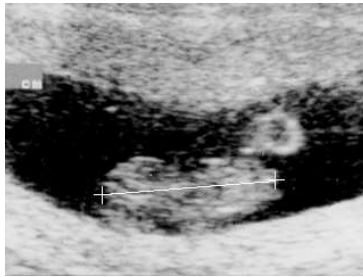


ANSWER: This image shows proper caliper placement for measuring the CRL.

Case 8-9

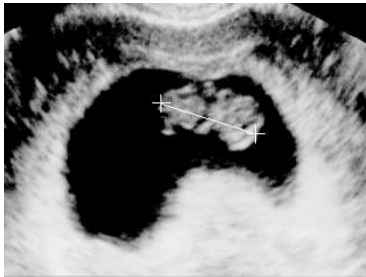


ANSWER: This image shows proper caliper placement for measuring the CRL.

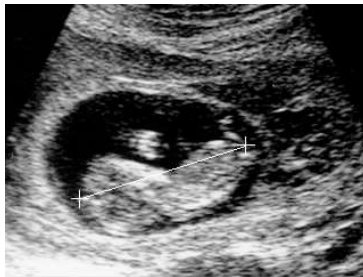

ANSWER: This image shows proper caliper placement for measuring the CRL.

Case 10-11

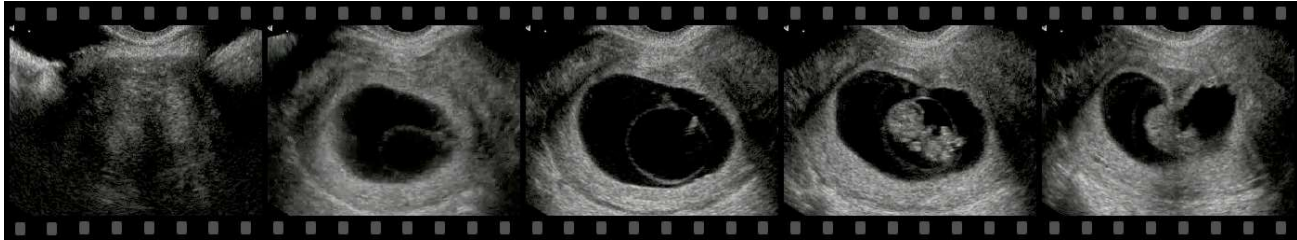


ANSWER: This image shows proper caliper placement for measuring the CRL.



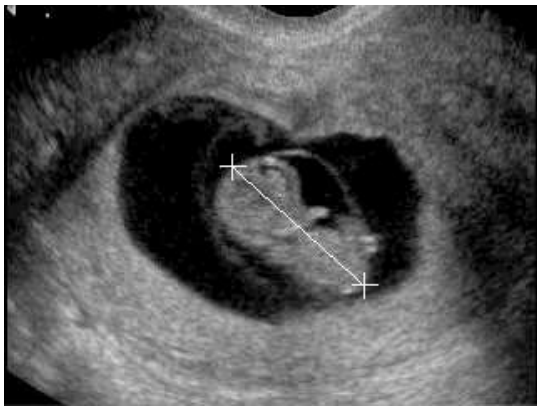ANSWER: This image shows proper caliper placement for measuring the CRL.

5.35: Practice Selecting the Appropriate Frame for CRL Measurement



ANSWER: Frame 4 in this image is acceptable for measuring CRL.

Choose the image in this set of video frames that is the appropriate image for measuring crown-rump length.

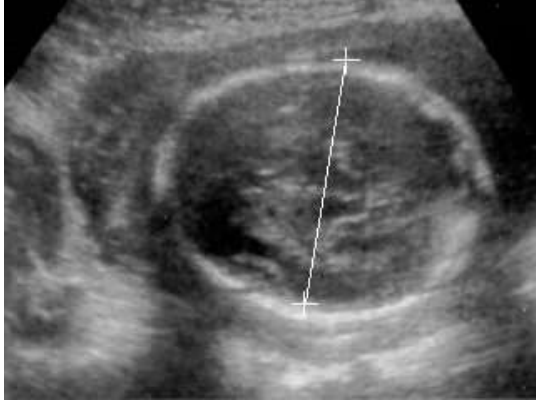


ANSWER: This image shows proper caliper placement for measuring the CRL.

10.7: Practice Measuring: BPD

Practice measuring the BPD on these images.

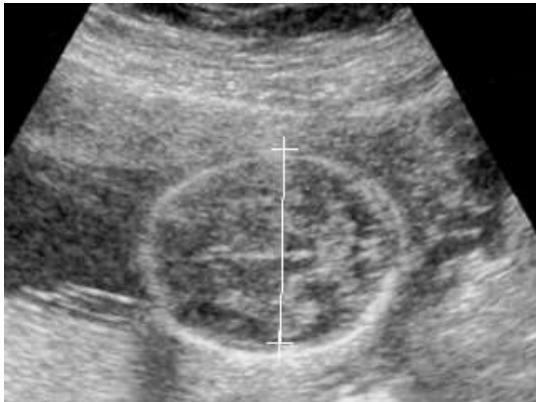Case 1



Mark where to set the calipers or imagine where to set the calipers and measure the BPD. Be sure to measure from the **OUTSIDE** of the fetal skull edge nearest the transducer to the **INSIDE** of the fetal skull edge farthest from the transducer.

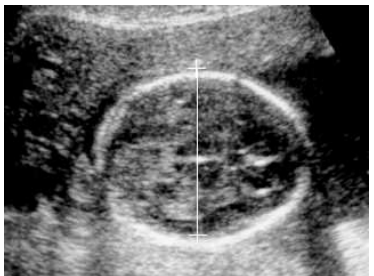
ANSWER: This image shows proper caliper placement for measuring the BPD.

Case 2

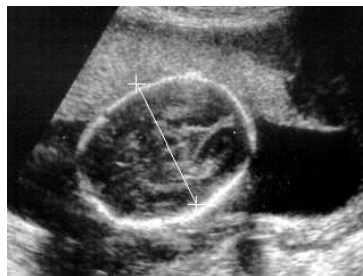

ANSWER: This image shows proper caliper placement for measuring the BPD.

Case 3-4



ANSWER: This image shows proper caliper placement for measuring the BPD.

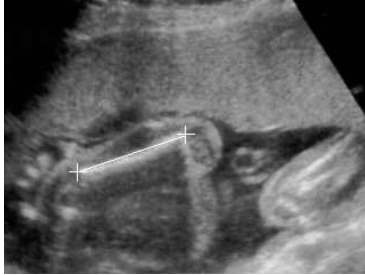

ANSWER: This image shows proper caliper placement for measuring the BPD.

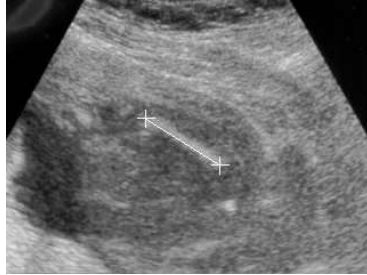10.9: Practice Measuring: Femur Length

Practice measuring the femur length on these images.

Case 1-2

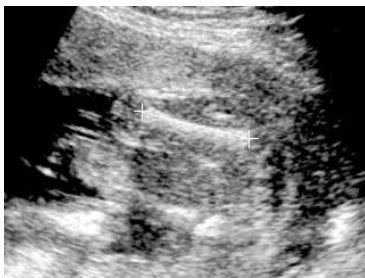

ANSWER: This image shows proper caliper placement for measuring the FL.

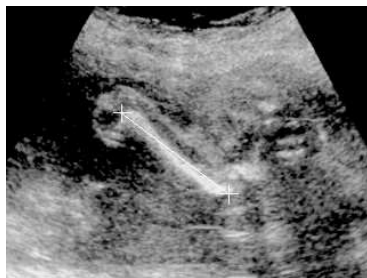

ANSWER: This image shows proper caliper placement for measuring the FL.

Case 3-4



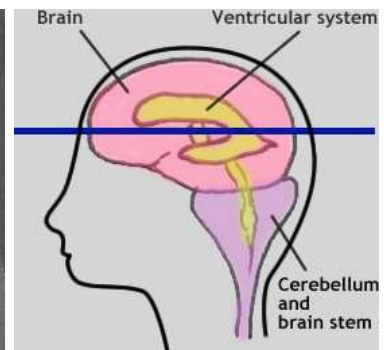
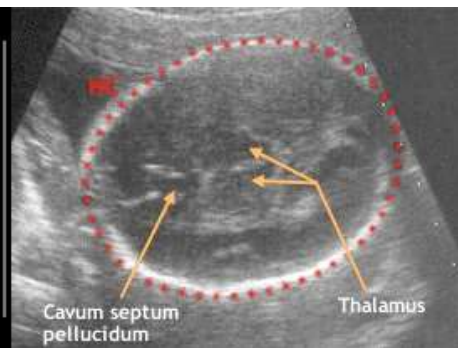
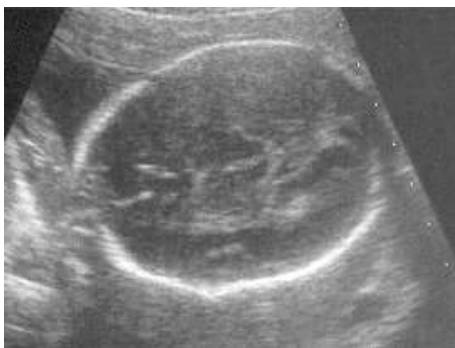ANSWER: This image shows proper caliper placement for measuring the FL.



ANSWER: This image shows proper caliper placement for measuring the FL.

10.10: Practice Measuring: Head Circumference

Diagrams and images

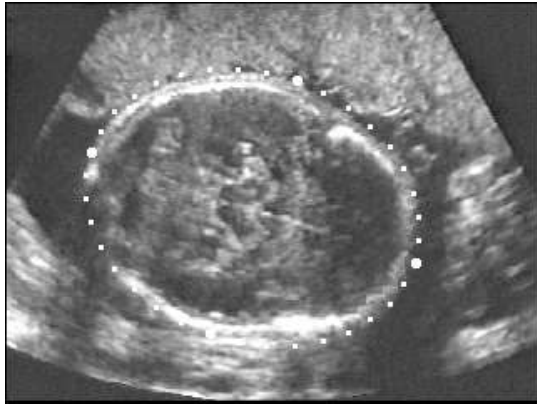


Correct plane for measuring HC

The head circumference (HC) must be measured in a transverse view of the fetal head. The thalamus

and cavum septum pellucidum should be visible. The Sylvian fissure should be visible laterally. The cerebellum should not be visible. After roughly 14 weeks, the lateral ventricles and choroid plexus should not be visible. (Prior to 15 weeks, these structures dominate most views of the fetal head.) The margins of the calvarium (fetal skull) should be clear and symmetric. The head circumference is measured along the outside of the bony calvarium, not the edge of the scalp.

Practice measuring HC

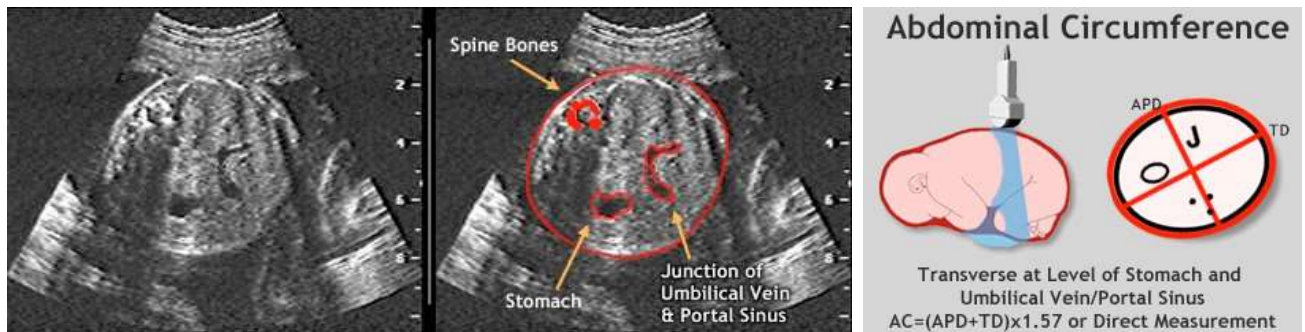


Practice measuring the HC of this fetal head.

ANSWER: This image shows proper caliper placement for measuring the HC.

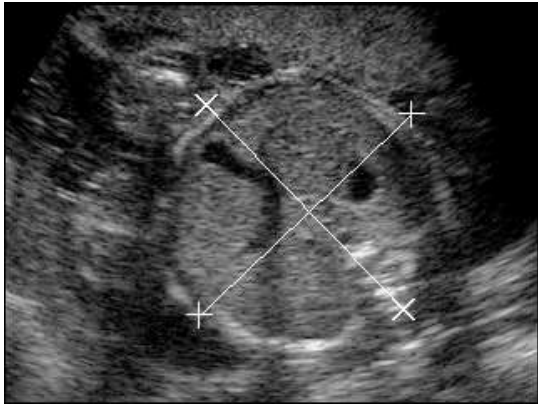
10.11: Practice Measuring: Abdominal Circumference

Diagrams and images



The abdominal circumference is measured in a transverse plane containing the fetal stomach and the junction of the umbilical vein and left portal vein as they form a "J." The heart and kidneys should not be visible. The circumference may be measured either directly or by calculation from two diameters. In many situations, an abdominal circumference is not needed prior to a surgical abortion; head and femur measurements are sufficient to determine gestational age within the limits needed prior to surgical abortion. However when needed, the addition of the abdominal circumference will allow a more precise estimation of gestational age.

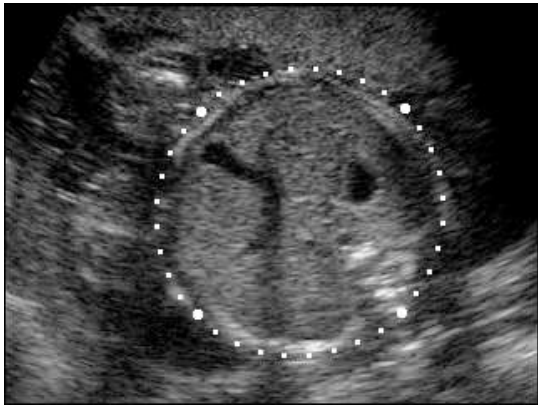
Practice 2-diameter measurement



Practice measuring the abdominal circumference.

ANSWER: This image shows proper caliper placement for measuring the AC.

Practice direct measurement



ANSWER: This image shows proper direct measurement of the AC.

References

The references are standard ultrasound textbooks except as noted. No references are provided for chapters 1 and 14.

The standard texts are:

1. Basic Ultrasound. Meire H and Farrant P (eds) John Wiley and Sons 1995
2. Ultrasonography in Obstetrics and Gynecology. Callen PW (ed) 4th ed. W.B. Saunders Co. 2001
3. Ultrasound in Obstetrics and Gynaecology. Dewbury K, Meire H, Cosgrove D, Farrant P (eds). 2nd ed. Churchill Livingstone 2001

Chapter/topic	Reference
1. Introduction	None
2. Basic physics	Reference 1: Chapters 2, 3, 4 and 10
3. Scanning routes	Reference 2: Chapter 28 pages 781-784 Reference 3: Chapter 7 pages 153-155
4. The pelvis	Reference 2: Chapter 28 pages 785-810 and Chapter 29 pp. 814-828 Reference 3: Chapter 1 pages 3-16 and Chapter 3 pages 65 -71
5. Early pregnancy: normal	Reference 2: Chapter 5 pages 105 - 131 Reference 3: Chapter 7 pages 155 - 161
6. Early pregnancy: abnormal	Reference 2: Chapter 5 pages 126 -141 and Reference 3: Chapter 7 pages 164-175
6. Twins	Reference 2: Chapter 7 pages 171-182 Reference 3: Chapter 7 pages 163-164 and Chapter 10 pp. 245-248
6. Fibroids	Reference 2: Chapter 29 pages 829-845 Reference 3: Chapter 7 pages 182-184
7. Ectopic pregnancy	Reference 2: Chapter 33 Reference 3: Chapter 7 pages 175-182
8. Ultrasound in early surgical abortion	Paul M, Lichtenberg ES, Borgatta L, Grimes DA, Stubblefield PG. A Clinician's Gide to Medical and Surgical Abortion. 1999 Churchill Livingstone: Chapter 9 and Chapter 15
9. Medication abortion	<i>(See full list below)</i>
10. Biometry	Reference 2: Chapter 6 Reference 3: Chapter 9
11. Placenta	Reference 2: chapter 20 pages 597-615 Reference 3: chapter 23 pages 529-533
12. Ultrasound in second trimester abortion	Paul M, Lichtenberg ES, Borgatta L, Grimes DA, Stubblefield PG. A Clinician's Gide to Medical and Surgical Abortion. 1999 Churchill Livingstone: Chapter 10 and chapter 15
13. Advanced physics	Reference 1: Chapters 5,6,7,8,9 and 11
14. Proficiency and quality assurance	None

References for Chapter 9: Medication Abortion

- Banerjee, S., Aslam, N., Zosmer, N., Woelfer, B., and Jurkovic, D. (1999). The expectant management of women with early pregnancy of unknown location. Ultrasound in Obstetrics and Gynecology, *14*, 231-236.
- Barnhart, K.T., Sammel, M.D., Rinaudo, P.F., Zhou, L., Hummel, A.C., and Guo, W. (2004). Symptomatic patients with an early viable intrauterine pregnancy: hCG curves redefined. Obstetrics and Gynecology, *104*(1), 50-55.
- Barnhart, K.T., Simhan, H., and Kamelle, S.A. (1999). Diagnostic accuracy of ultrasound above and below the beta-hCG discriminatory zone. Obstetrics and Gynecology, *94*(4), 583-587.
- Batzer, F.R., Schlaff, S., Goldfarb, A.F., and Corson, S. L. (1981). Serial β -subunit human chorionic gonadotropin doubling time as a prognosticator of pregnancy outcome in an infertile population. Fertility and Sterility, *35*(3), 307-312.
- Batzer, F.R., Weiner, S., Corson, S., Schlaff, S., and Otis, C. (1983). Landmarks during the first forty-two days of gestation demonstrated by the β -subunit of human chorionic gonadotropin and ultrasound. American Journal of Obstetrics and Gynecology, *146*(8), 973-979.
- Cowett, A.A., Cohen, L.S., Lichtenberg, E.S., and Stika, C.S. Uterine evaluation of the endometrium after medical termination of pregnancy. Obstetrics & Gynecology 2004; *103*(5): 871-875.
- Doubilet, P.M., and Benson, G.B. (2003). Atlas of Ultrasound in Obstetrics and Gynecology. Lippincott Williams & Wilkins.
- Fiala, C., Safar, P., Bygdeman, M., and Gemzell-Danielsson, K. (2003). Verifying the effectiveness of medical abortion; ultrasound versus hCG testing. European Journal of Obstetrics & Gynecology and Reproductive Biology, *109* (2003), 190-195.
- Gracia, C.R., and Barnhart, K.T. (2001). Diagnosing ectopic pregnancy: decision analysis comparing six strategies. Obstetrics and Gynecology, *97*(3), 464-470.
- Kaakaji, Y., Neghiem, H.V., and Winter, T.C. (2000). Sonography of obstetric and gynecologic emergencies. American Journal of Roentgenology, *274*, 641-649.
- Kadar, N., Caldwell, B.V., and Romero, R. (1981). A method of screening for ectopic pregnancy and its indications. Obstetrics and Gynecology, *58*, 162-165.
- Medication abortion Am J Obstet Gynecol 2000; *183*:S1-S98
- National Abortion Federation. Early Options – A provider’s Guide to Medical Abortion 2001. National Abortion Federation Washington D.C.
- Paul, M., Lichtenberg, E.S., Borgatta, L., Grimes, D.A., Stubblefield, P.G. A Clinician’s Guide to Medical and Surgical Abortion. 1999 Churchill Livingstone Chapter 8
- Paul, M., Schaff, E., and Nichols, M. (2000). Early medical abortion: the roles of clinic assessment, human chorionic gonadotropin assays, and ultrasonography in medical abortion practice. American Journal of Obstetrics and Gynecology, *183*(2).
- Schaff, E.A., Fielding, S.L, Eisinger, S., and Stadalius, L. (2001). Mifepristone and misoprostol for early abortion when no gestational sac is present. Contraception *63*, 251-254.
- Yeh, H. (1999). Efficacy of the intradecidual sign and fallacy of the double decidual sign in the diagnosis of early intrauterine pregnancy. (Letter to the editor). Radiology, *210*, 579-582.